



Discover Generics

Cost-Effective CT & MRI Contrast Agents



WATCH VIDEO

AJNR

Technical note: sonography through the posterior fontanelle in diagnosing neonatal intraventricular hemorrhage.

N Anderson and J Fulton

AJNR Am J Neuroradiol 1991, 12 (2) 368-370

<http://www.ajnr.org/content/12/2/368.citation>

This information is current as
of June 20, 2025.

Technical Note: Sonography Through the Posterior Fontanelle in Diagnosing Neonatal Intraventricular Hemorrhage

Nigel Anderson¹ and James Fulton

Studies comparing sonographic and autopsy findings have shown diagnostic errors in 8–34% of cases of neonatal intraventricular hemorrhage (IVH) [1, 2]. The main reasons cited for these inaccuracies are blood missed in normal-sized ventricles, a very small amount of blood (usually in the occipital horns), or a large normal choroid plexus mistaken for hemorrhage. Because overlooked IVH tends to be found in the occipital horns at autopsy, and sonography through the posterior fontanelle gives excellent visualization of the occipital horns, posterior fontanelle scanning may offer advantages over anterior fontanelle scanning alone. This is not a new concept, as posterior fontanelle scanning for IVH was described in the early 1980s [3, 4]; however, it has received scant attention since then.

Materials and Methods

From June to December 1989, 45 infants admitted to our institution had sonography through the anterior fontanelle and immediately afterward through the posterior fontanelle by the same operator. Scans were obtained on a Dasonics ADA 400 (Dasonics, Inc., Milpitas, CA) using a 7.5-MHz mechanical sector probe (either cardiac or neonatal). Three sagittal and three coronal/axial images were recorded on film.

The sagittal views were midline of the cerebellar vermis and fourth ventricle, and of each lateral ventricle, concentrating on the occipital horns (Fig. 1).

The coronal/axial views were supraventricular, at the level of the trigone, and through the occipital horns (Fig. 2).

Discussion

In 44 of the 45 infants, posterior fontanelle scanning provided good to excellent visualization of the occipital horns of

the lateral ventricles whether of normal size or enlarged (Figs. 1 and 2). This confirms that posterior fontanelle scanning is technically feasible in the neonatal group at high risk for IVH (under 32 weeks), although it is increasingly difficult in infants over 35 weeks owing to the smaller fontanelle and larger head size.

IVH was detected in seven of the 45 infants, all within the first week of life. In all seven cases, scanning through the posterior fontanelle demonstrated echogenic blood in the occipital horns of the lateral ventricles. In one case, IVH could be seen only via the posterior fontanelle, despite excellent visualization of the normal-size ventricle through the anterior fontanelle. In two other cases, IVH was seen first only via the posterior fontanelle, either adherent to the choroid plexus (Fig. 3) or as a blood CSF level. In the examinations in which IVH was seen via both fontanelles, the posterior fontanelle provided a more convincing image of IVH in six cases and an equally convincing image in the remaining six (Fig. 4). In the 37 infants without IVH, posterior fontanelle scanning helped confirm the absence of blood in the ventricles, especially in the normal slitlike ventricles (Fig. 1A), where the choroid was bulky, or in instances where the calcar avis created a pseudomass.

Blood and resultant clot usually collect in the occipital horn of the lateral ventricle, and commonly adhere to the choroid plexus [5]. The occipital horn lies peripherally in the far field in anterior fontanelle scans but lies centrally in the near field in posterior fontanelle scans (Fig. 1), allowing improved detection of small amounts of blood. Clot adherent to the choroid plexus usually projects into the occipital horn, as this is more dependent than the frontal horn. The clot/choroid interface is tangential for anterior fontanelle sagittal scanning but perpendicular to the beam for posterior fontanelle sagittal scanning. This may account for the better visualization of clot adherent to the choroid on posterior fontanelle scanning in three of our cases. Coronal anterior fontanelle scanning gives poor vis-

Received May 9, 1990; revision requested July 30, 1990; revision received October 4, 1990; accepted October 9, 1990.

¹ Both authors: Department of Radiology, Christchurch Women's Hospital, 885 Colombo St., Christchurch 1, New Zealand. Address reprint requests to N. Anderson.

Fig. 1.—A, Sagittal view of occipital horn of a normal-sized lateral ventricle seen via posterior fontanelle, which has a prominent calcar avis. c = choroid, oh = occipital horn, ca = calcar avis.

B, Diagram of sagittal view of lateral ventricle scanned through posterior fontanelle.

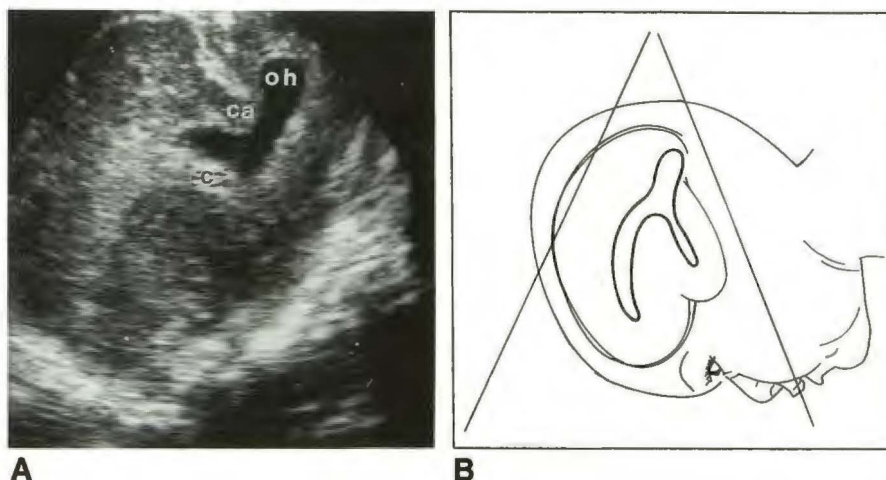


Fig. 2.—Coronal “owl’s eye” view through posterior fontanelle shows mildly dilated lateral ventricles. This view is obtained by angling transducer down through occipital lobes. Choroid is not seen at this level. oh = occipital horn, dotted line = tentorium cerebelli.

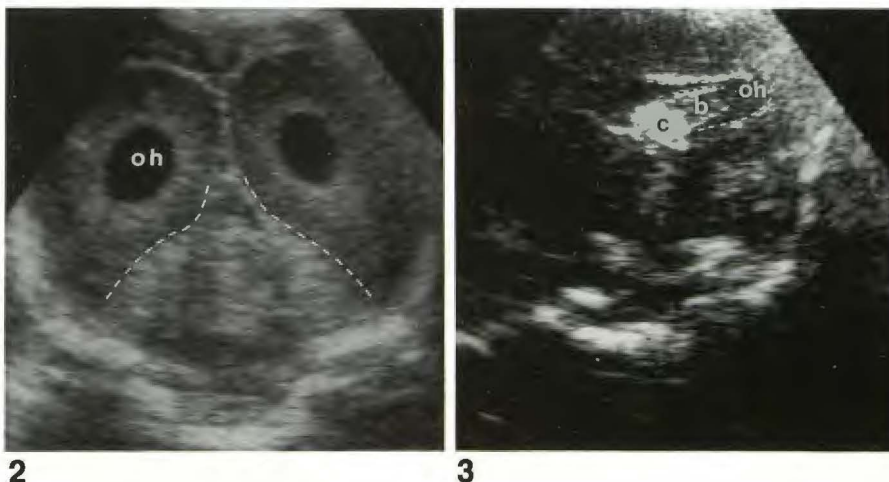


Fig. 3.—Sagittal view through posterior fontanelle shows blood within occipital horn, which was confirmed on coronal scan. The blood with an echogenic margin is adherent to the choroid. c = choroid, b = blood, oh = occipital horn.

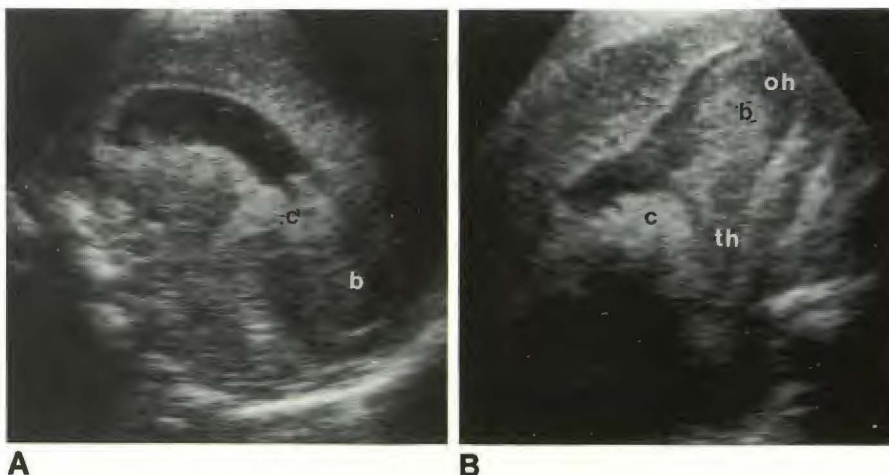


Fig. 4.—A, Sagittal view through anterior fontanelle shows blood posteriorly in right lateral ventricle.

B, Comparable view through posterior fontanelle confirms blood-filled occipital and temporal horns. c = choroid, b = blood, oh = occipital horn, th = temporal horn.

ualization of the posterior margins of the occipital horns, where small clots collect, but this area is very well seen on posterior fontanelle coronal scans (Fig. 2).

In the premature infant, the normal choroid is bulky and may bulge into the occipital horns [1]. The normal choroid was misinterpreted as germinal matrix hemorrhage or IVH in

15/27 false-positive diagnoses in one correlative sonographic/autopsy study [1]. Clear visualization of the choroid on posterior fontanelle scans using the occipital horn as an acoustic window allows differentiation of bulky choroid from IVH.

The advantages of posterior fontanelle scanning for IVH include better visualization of the occipital horns, clear visual-

ization of the calcarine fissure pseudomass [6], better differentiation of blood-filled ventricle from surrounding brain, and clear images of the choroid plexus at the trigone of the lateral ventricle. The disadvantages include the inability to diagnose germinal matrix hemorrhage and lack of visualization of the frontal horns of the lateral ventricles (unless they are dilated). Posterior fontanelle scanning is technically more difficult to perform, especially in the term infant; but because of refinements in transducer design, it is less cumbersome now than when it was first described [3, 4].

It is important to diagnose IVH accurately so that the individual neonate is managed appropriately. The findings in this study suggest that combining anterior and posterior fontanelle scanning will improve the accuracy of IVH diagnosis. We are advocating posterior fontanelle scanning to complement, not replace, anterior fontanelle scanning.

REFERENCES

1. Hope PL, Gould SJ, Howard S, et al. Precision of ultrasound diagnosis of pathologically verified lesions in the brains of very preterm infants. *Dev Med Child Neurol* **1988**;30:457-471
2. Mack LA, Wright K, Hirsch JH, et al. Intracranial hemorrhage in premature infants: accuracy of sonographic evaluation. *AJR* **1981**;137:245-250
3. Bejar R, Curbelo V, Coen RW, et al. Diagnosis and follow-up of intraventricular and intracerebral hemorrhages by ultrasound study of the infant's brain through the fontanelles and sutures. *Pediatrics* **1980**;66:661-673
4. Babcock DS, Han BK, Le Quesne GW. B mode gray scale ultrasound of the head in the newborn and young infant. *AJR* **1980**;134:457-468
5. Bowerman RA, Donn SM, Silver TM, Jaffe MH. Natural history of neonatal periventricular/intraventricular hemorrhage and its complications: sonographic observations. *AJR* **1984**; 143:1041-1052
6. Vade A, Otto R. Cranial sonography of the occipital horns and gyral patterns in the occipital lobes. *AJNR* **1986**;7:873-877