



## Get Clarity On Generics

Cost-Effective CT & MRI Contrast Agents



FRESENIUS  
KABI

WATCH VIDEO

# AJNR

## Cystic intraparenchymal meningioma in a child: case report.

A C Mamourian, A E Lewandowski and J Towfighi

*AJNR Am J Neuroradiol* 1991, 12 (2) 366-367

<http://www.ajnr.org/content/12/2/366.citation>

This information is current as  
of August 1, 2025.

## Cystic Intraparenchymal Meningioma in a Child: Case Report

Alexander C. Mamourian,<sup>1</sup> Anne E. Lewandowski,<sup>1,2</sup> and Javad Towfighi<sup>3</sup>

Meningiomas may have atypical features on CT scans [1]. These variations in appearance may be misleading in terms of predicting the histology of such lesions preoperatively. Among these variations, cystic meningiomas are particularly confusing [2]. We encountered an unusual case of a cystic and intraparenchymal meningioma in a child. This combination of features has not been reported previously.

### Case Report

A 27-month-old girl was admitted to the hospital for evaluation of fever (40°C), vomiting, and diarrhea. At the time of admission, phys-

ical examination revealed a large head and an open anterior fontanelle. The child's head circumference was about the 95th percentile for age. The remainder of the physical examination was normal. The mother reported that the patient was born by spontaneous vaginal delivery at 42-weeks gestation after an uncomplicated pregnancy. Medical history was remarkable only for a large head at birth, but transillumination was negative for hydrocephalus and no imaging studies were performed at that time.

On this admission a CT scan of the head showed a 9.5-cm calcified cystic mass in the left frontal region (Figs. 1A and 1B). After administration of contrast material there was some enhancement in the interstices of the heterogeneous mass. Digital subtraction angiography of the left common carotid arterial system was performed under

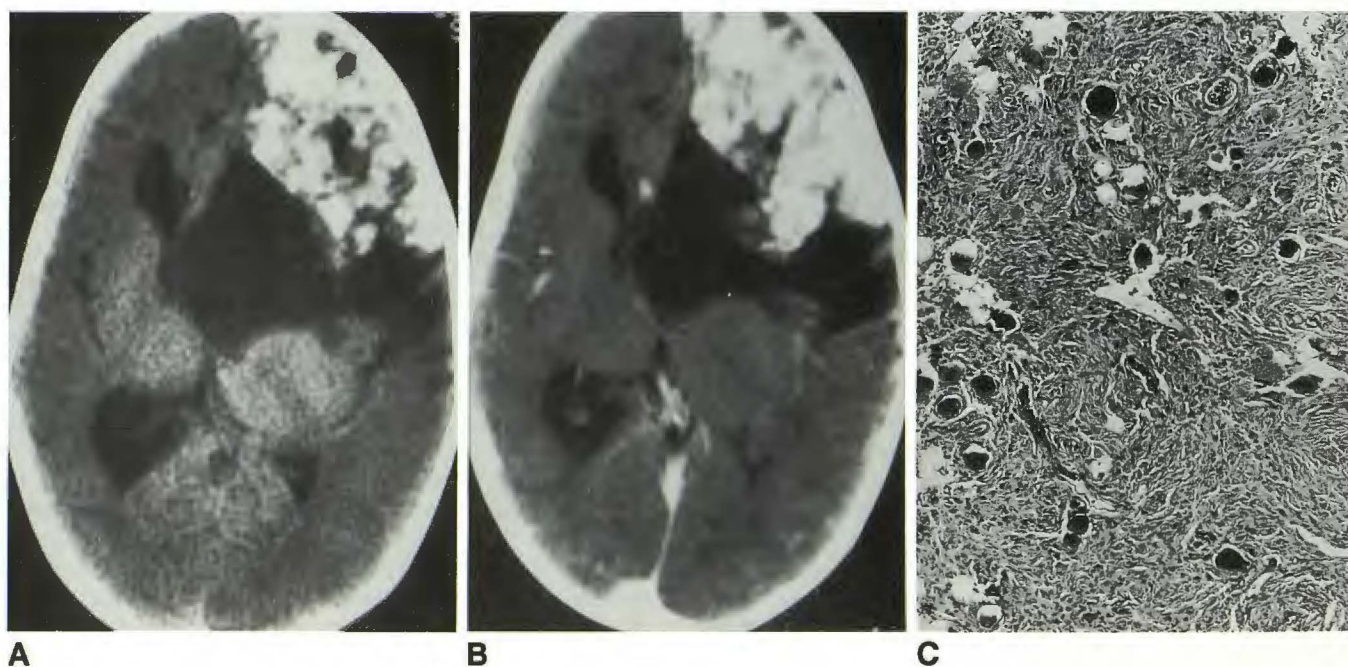


Fig. 1.—A, Unenhanced CT scan of the brain shows a large complex mass in left frontal region. Mass contains dense calcifications as well as cystic components. Compression of left lateral ventricle and shift of midline structures is evident.  
B, After contrast administration, enhancement can be seen within calcified portion of mass.  
C, Histology of meningioma shows dark round psammoma bodies. (H and E,  $\times 130$ )

Received January 19, 1990; returned for revision May 11, 1990; revision received October 23, 1990; accepted October 26, 1990.

<sup>1</sup> Department of Radiology, Milton S. Hershey Medical Center, Hershey, PA 17033. Address reprint requests to A. C. Mamourian.

<sup>2</sup> Present address: Department of Radiology, Lancaster General Hospital, 555 N. Duke St., Lancaster, PA 17602.

<sup>3</sup> Department of Pathology, Milton S. Hershey Medical Center, Hershey, PA 17033.



general anesthesia. The mass was avascular and there were no enlarged meningeal vessels. Differential diagnosis included oligodendroglioma and teratoma.

Following these studies, the patient underwent craniotomy and excision of the tumor. At surgery, the mass was pale yellow with multiple areas of calcification. While it appeared attached to the arachnoid in the floor of the frontal fossa, no dural attachment was noted. A large cyst was entered during the procedure and emptied of its xanthochromic fluid contents. Gross total removal of the tumor was performed. Microscopic examination showed a heavily calcified meningioma with fibrous and psammomatous components (Fig. 1C). Small meningeothelial components and microcystic changes were present also.

The patient was discharged on postoperative day 7 without neurologic deficit. Fifteen weeks after surgery a CT scan of the brain revealed the surgical defect in the frontal lobe but no residual tumor.

## Discussion

Meningiomas are thought to arise from meningotheial cells that line the arachnoid. Most are dural based, but they also may be intraventricular or entirely intraparenchymal. In these cases the tumor is believed to arise from meningotheial cells in the stroma of the choroid plexus, tela choroidea, and pia mater. While the term intraparenchymal is used to describe tumors that arise within the brain substance, it also has been used to describe meningiomas that are not dural based [3]. The radiologic appearance of intraparenchymal meningiomas may pose a diagnostic problem. As was noted in our case, there was no evidence of an external carotid supply to the tumor nor was a tumor stain noted on cerebral angiography. While the presence of both these features is considered typical for meningiomas, they are uncommon with the cystic lesions [4].

The pathogenesis of the cyst formation in meningiomas remains uncertain. The cysts have been characterized by Nauta et al. [5] on the basis of their location relative to the meningioma. These cysts may be within the meningioma or at the periphery, interposed between the tumor and brain substance. The fluid is xanthochromic with an elevated protein content (1600–9000 mg/dl), resembling the cysts associated with gliomas but often with a lower SGOT and LDH [4]. The variability of cyst location suggests more than one mechanism of cyst formation.

Meningiomas in children are quite rare, constituting only 1–2% of intracranial tumors [6, 7]. Only 16 other cases of cystic meningiomas in children (17 years and under) have been reported [8]. There are even fewer reports of intraparenchymal meningiomas [3, 6, 7]. In our case the tumor was both cystic and intraparenchymal. In adults, an association of cyst formation with intraparenchymal meningiomas has been noted, but this combination has not been described previously in children [2]. In a review of 18 childhood meningiomas,

however, Sano et al. [7] found that cyst formation (16.7%) and absence of dural attachment (12.5%) were relatively common features.

The correct diagnosis was not made preoperatively in our case. While angiography of meningiomas usually demonstrates their external carotid supply, this was not present in our case. On a review of the literature, Fortuna et al. [9] concluded that the correct diagnosis of cystic meningioma could be made by angiography in only 13% of cases. In reviewing several articles with angiographic results, there was an external carotid supply to the tumor in 50% [3–6, 10, 11]. Reports of other cystic meningiomas describe CT enhancement similar to that in our case, but in one case, also a child, no enhancement was seen on CT [3]. Calcification was reported in two other cases [3, 6], but was not described in reports of large series of cystic meningiomas [1, 8, 9]. The literature does not reveal any unique imaging features of cystic meningiomas.

A preoperative MR study was not performed, and no reports have been published on the MR appearance of cystic meningiomas. On the basis of the difficulties in discriminating these lesions from gliomas both on CT and histologically [2], it seems unlikely that MR will permit their characterization, but this awaits further experience. MR may be helpful when a broad dural attachment may be more apparent on coronal or sagittal images than might be appreciated on axial CT. It remains essential that the possibility of a meningioma be considered whenever a cystic intracranial mass is identified in a patient of any age.

## REFERENCES

1. Russell EJ, George AE, Kricheff II, Budzilovich G. Atypical computed tomographic features of intracranial meningiomas. *Radiology* 1980;135:673–682
2. Henry JM, Schwartz FT, Sartawi MA, Fox JL. Cystic meningiomas simulating astrocytomas. *J Neurosurg* 1974;40:647–650
3. Schroeder BA, Samaraweera RN, Starshak RJ, Oechler HW. Intraparenchymal meningioma in a child: CT and MR findings. *J Comput Assist Tomogr* 1987;11(1):192–200.
4. Worthington C, Carron JL, Melanson D, Leblanc R. Meningioma cysts. *Neurology* 1985;35:1720–1724
5. Nauta HJ, Tucker WS, Horsey WJ, Bilbao JM, Gonsalves C. Xanthochromic cysts associated with meningioma. *J Neurol Neurosurg Psychiatry* 1979;42:529–535
6. Leguis E, Vles JS, Casar P, Plets C, Dom R. Intraparenchymal meningioma in a 14-month-old infant: a case report. *Brain Dev* 1985;7:622–624
7. Sano K, Wakai S, Ochiai C, Takakura K. Characteristics of intracranial meningiomas in childhood. *Childs Nerv Syst* 1981;8:98–106
8. Umansky F, Pappo I, Pizov G, Shalit M. Cystic changes in intracranial meningiomas, a review. *Acta Neurochir (Wien)* 1988;95:13–18
9. Fortuna A, Ferrante M, Acqui M, Guglielmi G, Mastronardi L. Cystic meningiomas. *Acta Neurochir (Wien)* 1988;90:23–30
10. Becker D, Norman D, Wilson C. Computerized tomography and pathological correlation in cystic meningiomas. *J Neurosurg* 1979;50:103–105
11. Amano K, Miura N, Jajika Y, et al. Cystic meningioma in a 10 month old infant. *J Neurosurg* 1980;52:829–833