



Discover Generics

Cost-Effective CT & MRI Contrast Agents



WATCH VIDEO

AJNR

Management of vascular perforations that occur during neurointerventional procedures.

V V Halbach, R T Higashida, C F Dowd, S L Barnwell and G B Hieshima

AJNR Am J Neuroradiol 1991, 12 (2) 319-327

<http://www.ajnr.org/content/12/2/319>

This information is current as of June 17, 2025.

Management of Vascular Perforations That Occur During Neurointerventional Procedures

Van V. Halbach^{1,2}
 Randall T. Higashida^{1,2}
 Christopher F. Dowd¹
 Stanley L. Barnwell²
 Grant B. Hieshima^{1,2}

This article describes a number of treatment strategies for the management of perforations that occur during neurointerventional procedures. During the past 5 years, we have performed over 1200 endovascular procedures to treat vascular disorders involving the brain and spinal cord (400 cerebral arteriovenous malformations, 230 tumors, 197 carotid cavernous fistulas, 183 aneurysms, 130 dural fistulas, 80 spinal arteriovenous malformations, 18 vein of Galen aneurysms, and 20 cases of vasospasm). Fifteen patients (1.1%) sustained a vascular perforation as a direct result of these procedures. Among these 15 patients, indications for endovascular treatment were six symptomatic arteriovenous malformations, two spinal cord arteriovenous malformations, two cavernous sinus dural fistulas, one transverse sinus fistula, one case of vasospasm following subarachnoid hemorrhage, one direct carotid cavernous fistula, one vein of Galen malformation, and one ruptured basilar artery aneurysm. The vascular perforations were grouped into three probable mechanisms: mechanical perforation of a normal vessel (six patients), mechanical disruption of a dysplastic vessel or aneurysm (five patients), and fluid overinjection (four patients). Treatment of the perforations included immediate reversal of anticoagulants (12 patients) and direct closure of the perforation site with coils (five patients). In addition, closure of the intravascular compartment adjacent to the perforation was achieved with coils (six patients), liquid adhesives (four patients), balloons (two patients), or particles (two patients). In two patients a detachable balloon was placed transiently across the perforation site for several minutes, deflated, and removed when no further extravasation was noted. Five patients were started on anticonvulsant therapy, two of whom have had a new onset seizure related to the perforation. Immediate consequences of the perforation induced headaches (nine patients), seizures (two patients), hydrocephalus (one patient), paraplegia (one patient), right upper extremity dysmetria (one patient), diabetes insipidus (two patients), and two deaths. One patient survived for 2 years without symptoms but died from unrelated causes. Long-term sequelae in the remaining 12 patients include diabetes insipidus in one and stable hydrocephalus in one. No documented episodes of rehemorrhage have occurred, and the patients were followed for a mean of 30 months.

Despite the development of softer steerable guidewires and microcatheters, soft detachable balloons, and roadmapping techniques, vascular perforations may sometimes occur during endovascular procedures involving the brain and spinal cord. Prompt recognition and closure of the perforation is essential for a good outcome.

AJNR 12: 319–327, March/April 1991

Received October 4, 1989; revision requested December 4, 1989; revision received August 27, 1990; accepted October 10, 1990.

¹ Department of Radiology, L352, UCSF Hospitals, 505 Parnassus Ave., San Francisco, CA 94143. Address reprint requests to V. V. Halbach.

² Department of Neurological Surgery, UCSF Hospitals, San Francisco, CA 94143.

0195-6108/91/1202-0319

© American Society of Neuroradiology

Vascular perforations have been reported with both diagnostic and therapeutic procedures outside the CNS [1–11]. The majority of these are repaired surgically. Only a few reports have dealt with vascular perforations occurring within the CNS. These are usually a consequence of diagnostic procedures [12–14]. Recently, vascular perforations have been reported during intracranial navigation with steerable microcatheters [15]. Treatment has included surgical closure of the perforation [15], closure with silk suture emboli, or conservative management (Ferguson R, personal communication). The outcome in these patients has ranged from asymp-

tomatic (Horton J, personal communication) to massive hemorrhage and death (Kerber C, Vinuela F, personal communications). We report the first series listing the frequency and possible cause of these complications, including their management and outcome.

Materials and Methods

Between August 1984 and August 1989 we performed over 1200 neurointerventional procedures. In 15 of these cases (1.2%) vascular perforation occurred during the procedure. The patients' age, sex, disease treated, site of perforation, result of perforation, outcome, and follow-up are summarized in Table 1. The individual treatment, presence of continued hemorrhage, and rehemorrhage are summarized in Table 2. The suspected mechanisms of perforation are listed in Table 3, as well as possible methods to reduce or eliminate their occurrence.

Representative Case Reports

Case 3

A 34-year-old woman with an occipital lobe arteriovenous malformation (AVM) had recent clipping of a distal basilar artery aneurysm

(Fig. 1A). She was referred to us for preoperative embolization of the posterior cerebral arterial feeders. The catheter could not be navigated via the vertebral basilar approach because of excessive tortuosity. Using a prototype Terumo (Mediatech, NJ) 0.014-in. guidewire, we navigated a 3.2-French Tracker catheter through the internal carotid and posterior communicating arteries, where the guidewire and catheter were noted to leave the intravascular compartment. The anticoagulation was immediately reversed. A small injection of non-ionic contrast material confirmed the extravascular location (Figs. 1B and 1C), and an angiogram revealed the perforation in the ambient segment of the posterior cerebral artery at the site of a small microaneurysm (Figs. 1A and 1B). A detachable balloon was positioned transiently across the suspected perforation site still attached to the delivery catheter. The Tracker catheter was slowly withdrawn until a segment of normal artery was entered at the site of the perforation (the lateral posterior choroidal artery). A prototype curved platinum coil (Target Therapeutics, San Jose, CA) was then positioned through, across, and proximal to the perforation site in the lateral posterior choroidal artery. The catheter was withdrawn back into the posterior cerebral artery, the balloon deflated, and no extravasation was observed. Since the AVM's draining veins would interfere with surgical exposure of the perforation site should delayed pseudoaneurysm formation occur, it was elected to embolize the AVM. By using

TABLE 1: Summary of Vascular Perforations

Case No.	Age (years)	Sex	Pathology	Vessel Catheterized	Result of Perforation	Immediate Outcome	Long-Term Outcome	Follow-up (months)
1	50	F	AVM	Ant ch	IVH	HA	0	26
2	8 days	M	Vein of Galen	Vein of Galen	IVH	Hydrocephalus	Hydrocephalus	13
3	34	F	AVM	PCA	SAH, IVH	Mild HA	0	26
4	55	M	AVM	Ant ch	IVH	Mild HA	0	18
5	62	F	TS DAVF	TS	Small subdural	0	0	28
6	72	F	CS DAVF	CS	0	DI	DI	13
7	71	F	Direct CCF	IPS	SAH	HA	0	54
8	33	F	AVM	Ant ch	IVH	HA	0	16
9	45	F	Vasospasm	PCA	Massive SAH	Death		
10	41	F	AVM/aneurysm	PCA	SAH	HA	0	24*
11	20	M	Spinal AVM	Ant spinal	SAH	Paraplegia	Recovered	14
12	26	F	Spinal AVM	Ant spinal	SAH	Seizure, HA	0	68
13	48	F	CS DAVF	IPS	Cerebellar hemorrhage	Dysmetria	Recovered	20
14	30	M	AVM	MCA branch	SAH	DI, seizure	0	11
15	68	M	AVM	PCA	Massive SAH	Death		

* Died of unrelated causes.

Note.—AVM = arteriovenous malformations, HA = headaches, PCA = posterior cerebral artery, SAH = subarachnoid hemorrhage, TS = transverse sinus, CS = cavernous sinus, DAVF = dural arteriovenous fistula, CCF = carotid cavernous fistula, IBCA = isobutyl cyanoacrylate, NBCA = normal butylcyanoacrylate, IVH = intraventricular hemorrhage, IPS = inferior petrosal sinus, DI = diabetes insipidus, ant ch = anterior choroidal, MCA = middle cerebral artery, 0 = neurologically intact without symptoms.

TABLE 2: Summary of Treatment

Case No.	Reverse Heparin	Anticonvulsant Therapy	Coil Across Perforation	Adjacent Coils	Intravascular Compartment Closed			Continual Hemorrhage	Rehemorrhage
					IBCA/NBCA	PVA Particles	Balloon		
1	Yes	Yes	No	No	Yes	No	No	No	No
2	Yes	Yes	Yes	Yes	No	No	No	No	No
3	Yes	No	Yes	No	No	No	Transient	No	No
4	Yes	No	No	No	No	No	Transient	No	No
5	Yes	No	Yes	Yes	Yes	No	No	No	No
6	DNA	No	No	Yes	Yes	No	No	No	No
7	DNA	No	Yes	Yes	No	No	No	No	No
8	Yes	Yes	No	No	No	Yes	No	No	No
9	Yes	No	No	No	No	No	No	Yes	Died
10	Yes	No	No	No	No	No	Permanent	No	No
11	Yes	No	No	No	No	No	Permanent	No	No
12	Yes	Yes	No	No	Yes	No	No	No	No
13	DNA	No	No	Yes	No	No	No	No	No
14	Yes	Yes	Yes	Yes	No	Yes	No	No	No
15	Yes	No	No	No	No	No	No	Yes	Died

Note.—DNA = does not apply.

TABLE 3: Mechanisms of Perforation

Type	Reason	Relevant Case Nos.	Methods to Avoid Complications
Overinjection	Pressure exceeded compliance of vascular pedicle	7, 8, 12, 13	Smaller, less frequent injections. Pressure measurements?
Mechanical perforation of normal vessel	Direct force of guidewire, catheter, or balloon disrupted vascular integrity	5, 6, 9, 11, 14, 15	Roadmapping. Softer guidewire + catheter. Low-friction guidewire. Careful navigation through curves. Latex bulb tip?
Mechanical perforation of aneurysm or dysplastic vessel	Tear in thin-walled, abnormal vascular ectasia or aneurysm	1, 2, 3, 4, 10	Pretreatment recognition of aneurysms. Roadmapping to prevent overinflation. Soft materials.

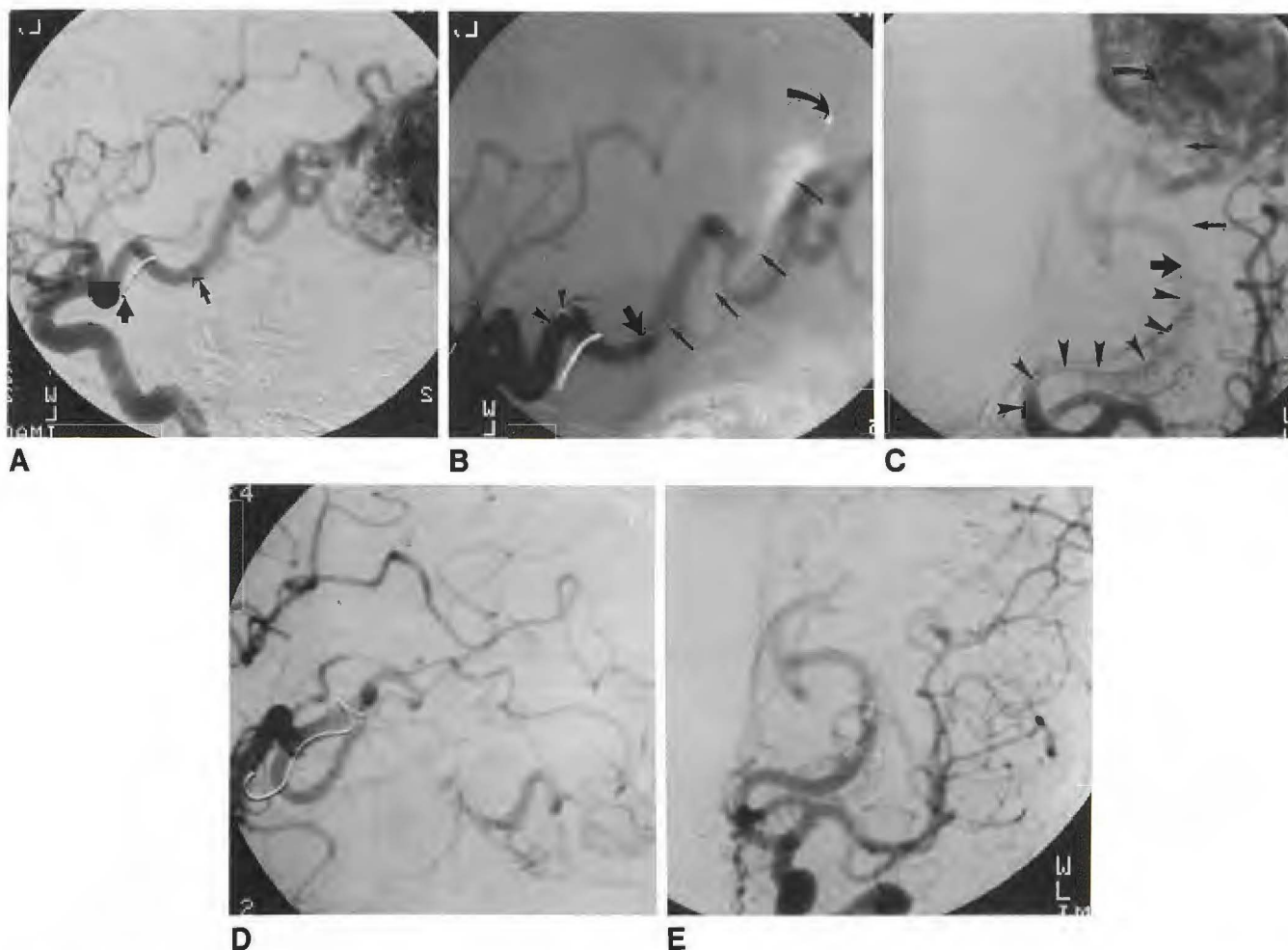


Fig. 1.—Case 3: 34-year-old woman who had previous clipping of a distal basilar aneurysm. She had an occipital lobe malformation, which was embolized preoperatively.

A, Left internal carotid injection, lateral projection, shows surgical clip (thick arrow) and large occipital lobe arteriovenous malformation. A small aneurysm is noted in ambient segment (thin arrow).

B and C, Left internal carotid angiogram, lateral (B) and Towne's (C) projections, during attempted subselective catheterization of posterior cerebral artery. Tracker catheter is seen within posterior communicating and proximal posterior cerebral arteries (arrowheads) and is noted to leave vascular system in ambient segment of posterior cerebral artery (thick straight arrow). Tip of catheter (curved arrow), lying in subarachnoid space, is surrounded by contrast material. Extravascular course of catheter is outlined by thin straight arrows.

D and E, Left internal carotid angiogram, lateral (D) and Towne's (E) projections, after closure of perforation site by a single platinum coil and particle embolization of posterior cerebral artery.

proximal flow arrest with the balloon inflated, the posterior cerebral artery feeders were embolized. The balloon and catheter were then removed. A control arteriogram (Figs. 1D and 1E) confirmed occlusion of the perforation site without pseudoaneurysm formation or extravasation. A postembolization CT scan showed the dense contrast material within the ambient wing cistern. The patient remained neu-

rologically intact, and the single complaint of mild headaches resolved within 6 hr. The malformation was resected without incident 1 week later. A postoperative arteriogram demonstrated complete excision of the AVM without pseudoaneurysm formation. At follow-up 2 years later the patient remains neurologically intact with a partial field cut resulting from the surgical excision.

Case 12

A 26-year-old woman had a ruptured intramedullary spinal AVM and associated pseudoaneurysm (Figs. 2A and 2B). During contrast injection extravasation was observed at the hairpin turn of the artery of Adamkiewicz. The patient developed back pain and generalized seizure (caused by the ionic contrast medium in the subarachnoid space) and was treated effectively with Dilantin, phenobarbital, and diazepam. The artery and perforation site were sealed with a small injection of IBCA (Fig. 2C). The patient recovered, and a second embolization resulted in closure of the pseudoaneurysm and AVM. The patient has had subsequent symptomatic improvement above baseline, remains seizure free, and has had no further hemorrhage.

Case 8

A 33-year-old woman with a right frontal temporal AVM underwent uneventful preoperative embolization of the middle cerebral supply (Figs. 3A–3C). During superselective embolization with polyvinyl alcohol particles (400–500 μ m) of the remaining anterior choroidal supply, extravasation was noted in the lateral ventricle (Fig. 3D). Anticoagulation was reversed immediately. Continued particle embolization sealed the perforation site. A postembolization CT scan (Fig. 3E) demonstrated mild hydrocephalus resulting from intraventricular contrast material and hemorrhage. She remained neurologically intact despite moderate headache, and on the following day had complete surgical excision of the malformation. A follow-up arteriogram showed normal filling of the anterior choroidal artery.

Case 2

A newborn boy presented with intractable congestive heart failure. Arteriography at 8 days disclosed a large vein of Galen malformation with numerous small arterial feeders (Fig. 4A). During a transfemoral transthoracic venous approach (Fig. 4B) with a Tracker 25 catheter and 0.22-in. guidewire, the guidewire was noted to leave the confines of the vein of Galen (Fig. 4C). The catheter was immediately advanced over the wire across the perforation site (Fig. 4C). Anticoagulation was reversed and a small injection of contrast material confirmed the

extravascular and intraventricular location of the catheter. A 0.25-in. Gianturco coil, 3 mm in diameter and 4 cm long, was then deposited. The tip of the coil was in the ventricle, and the proximal portion of the coil was positioned through the perforation and inside the vein of Galen (Fig. 4D). Forty-two additional coils were rapidly deposited into the vein of Galen to promote thrombosis near the perforation site (Fig. 4C). A CT scan obtained immediately after embolization and repair of the perforation showed contrast material concentrated in the right lateral ventricle (Fig. 4B). A postembolization angiogram 2 days later confirmed occlusion and thrombosis around the perforation site without evidence of pseudoaneurysm formation (Fig. 4D). The patient developed hydrocephalus after the procedure; however, he improved after shunting. The heart failure was alleviated. He was doing well at follow-up 13 months later.

Results

The specific diseases in which vascular perforations occurred included six intracranial AVMs, two spinal AVMs, two cavernous sinus dural fistulas, one transverse sinus dural fistula, one vasospasm following subarachnoid hemorrhage, one direct carotid cavernous fistula, one vein of Galen malformation, and one ruptured basilar aneurysm. In 15 patients, a CT scan was obtained immediately after the repair of the perforation. Contrast material and/or blood was present in the following locations: intraventricular (four patients), subarachnoid (seven patients), subdural (one patient), within the cerebellum (one patient), and subarachnoid and intraventricular (one patient). In one patient (case 6) neither blood nor contrast material could be documented. The presumed mechanisms for producing the perforation were overinjection (four patients), mechanical disruption of normal vessels (six patients), and mechanical disruption of the aneurysm or dysplastic vessel (five patients).

Methods of managing the perforation are summarized in Table 2. Reversal of anticoagulation with protamine sulfate was accomplished in all 12 patients on heparin. Anticonvul-

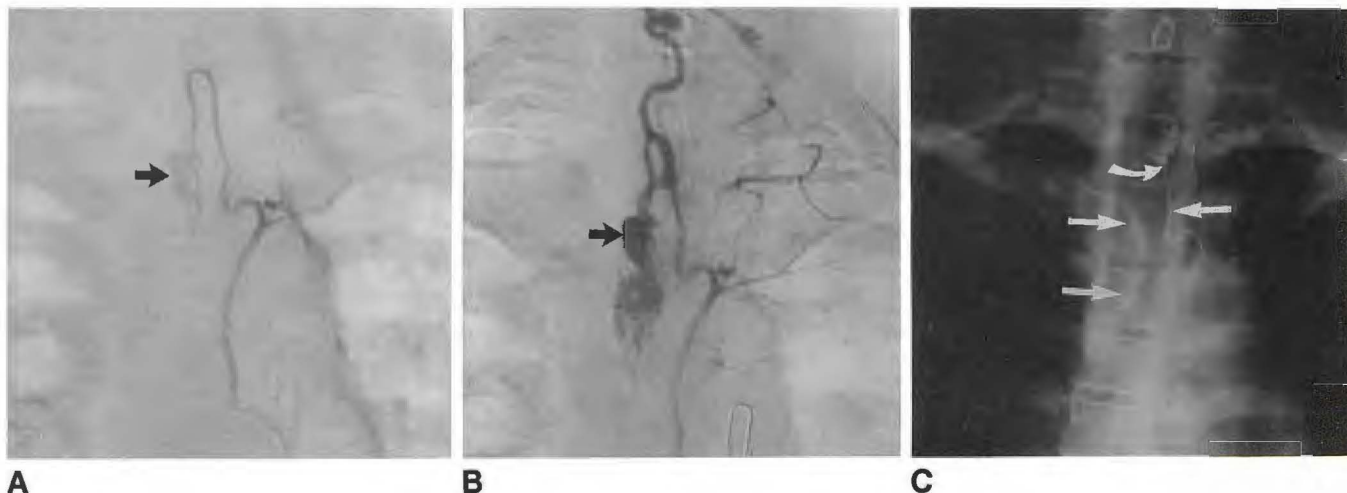

Fig. 2.—Case 12: 26-year-old woman with 13-year history of pain and recent hemorrhage from an intramedullary spinal arteriovenous malformation. A and B, Left T4 early (A) and mid (B) arterial injection shows lobulated pseudoaneurysm (arrow) in feeding artery to intramedullary arteriovenous malformation. During selective catheterization of hairpin curve of Adamkiewicz artery, extravasation was noted and embolized with liquid adhesives. C, Plain radiograph shows cast of Pantopaque/bucrylate within nidus of malformation and feeding arteries (straight arrows) as well as the point of extravasation into subarachnoid space (curved arrow).

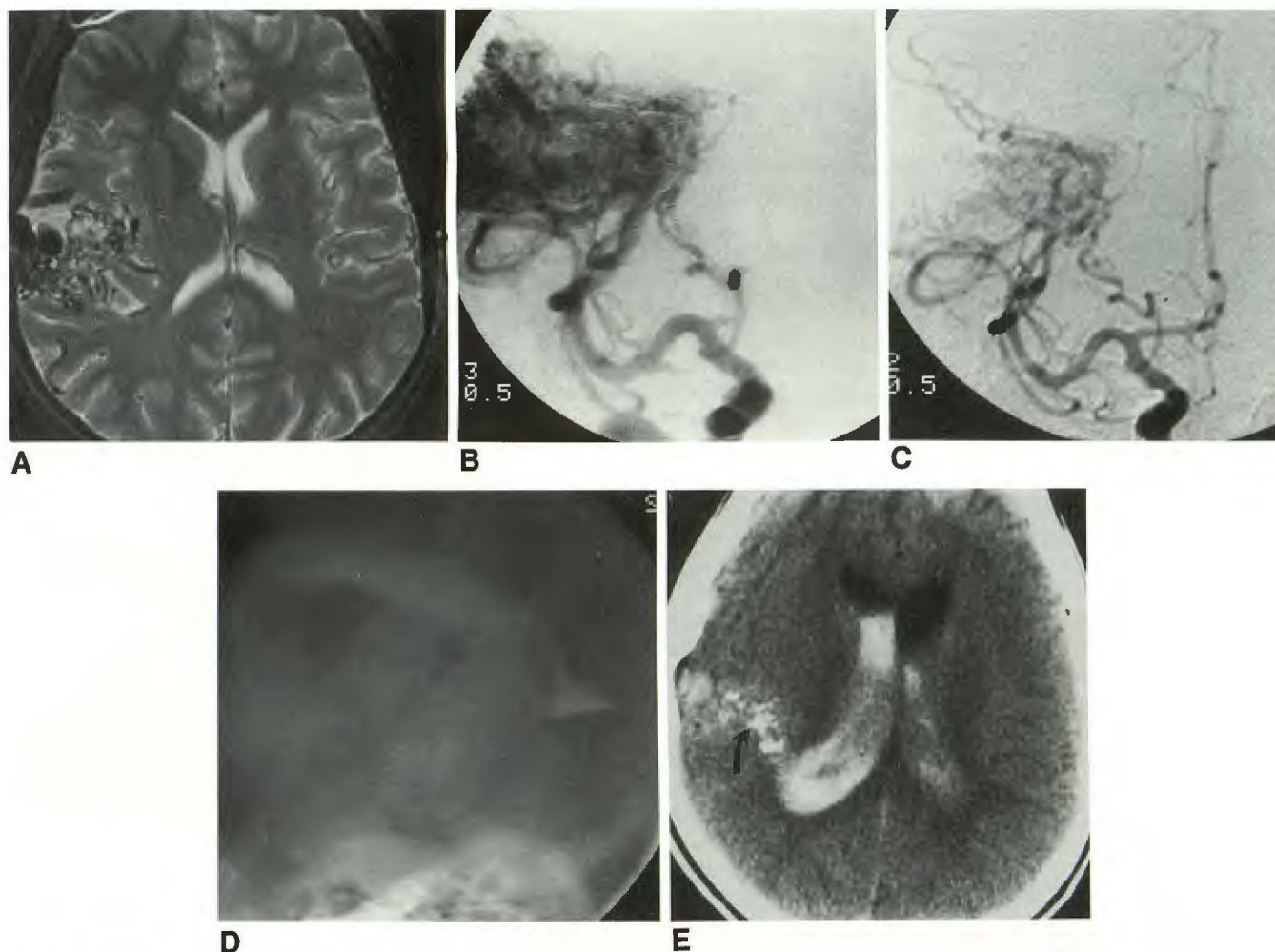


Fig. 3.—Case 8: 33-year-old woman with frontal temporal arteriovenous malformation had preoperative embolization.

A, Axial MR image (2800/80) shows large arteriovenous malformation in posterior frontal and temporal lobes. Note normal ventricular size.

B, Right internal carotid angiogram, anterior posterior projection, shows a large arteriovenous malformation supplied by multiple middle cerebral branches and secondary supply from anterior choroidal artery.

C, Same injection and projections, after embolization of middle cerebral contribution, shows persistent supply from anterior choroidal artery. During selective embolization of this vessel, extravasation was noted distally into the ventricular system.

D, Lateral plain radiograph shows contrast material within right lateral ventricle pooling in the occipital horn.

E, CT scan obtained immediately after embolization shows high-density embolic material within malformation (arrow) as well as high-density contrast agent and/or blood within right lateral ventricle. Note moderate amount of hydrocephalus.

sants were administered to five patients (in two cases following a new onset of a seizure related to the extravasation of blood or contrast material). In five patients a coil (Target Therapeutics, San Jose, CA) was placed across the perforation site. The immediately adjacent intravascular compartment was occluded with coils in six patients; with liquid adhesives (NBCA, CRX Inc., Raleigh, NC, or IBCA, Ethicon Inc., Somerville, NJ) in three patients; with polyvinyl alcohol particles (400–500 μ m, Interventional Therapeutics Corp., So. San Francisco, CA) in two patients; with temporary balloons in two patients; with permanent balloons (Interventional Therapeutics Corp.) in two patients. Combinations of coils, liquid adhesives, and particles were used in the remaining three patients. In two patients, both with massive subarachnoid

hemorrhage, death occurred before definitive treatment could be instituted.

The immediate (less than 24 h) outcome of the perforation and/or treatment included headaches in seven, diabetes insipidus in two, seizures in two, dysmetria in one, paraplegia in one, hydrocephalus in one, and death in two. The long-term (more than 2 weeks) sequelae resulting from the perforation or treatment included stable hydrocephalus in a vein of Galen malformation and diabetes insipidus possibly relating to closure of a cavernous dural arteriovenous fistula with liquid adhesive. One patient died 2 years after treatment from an unrelated cause. The 12 surviving patients are alive and well and have been followed for an average of 30 months. None has had evidence of rehemorrhage.

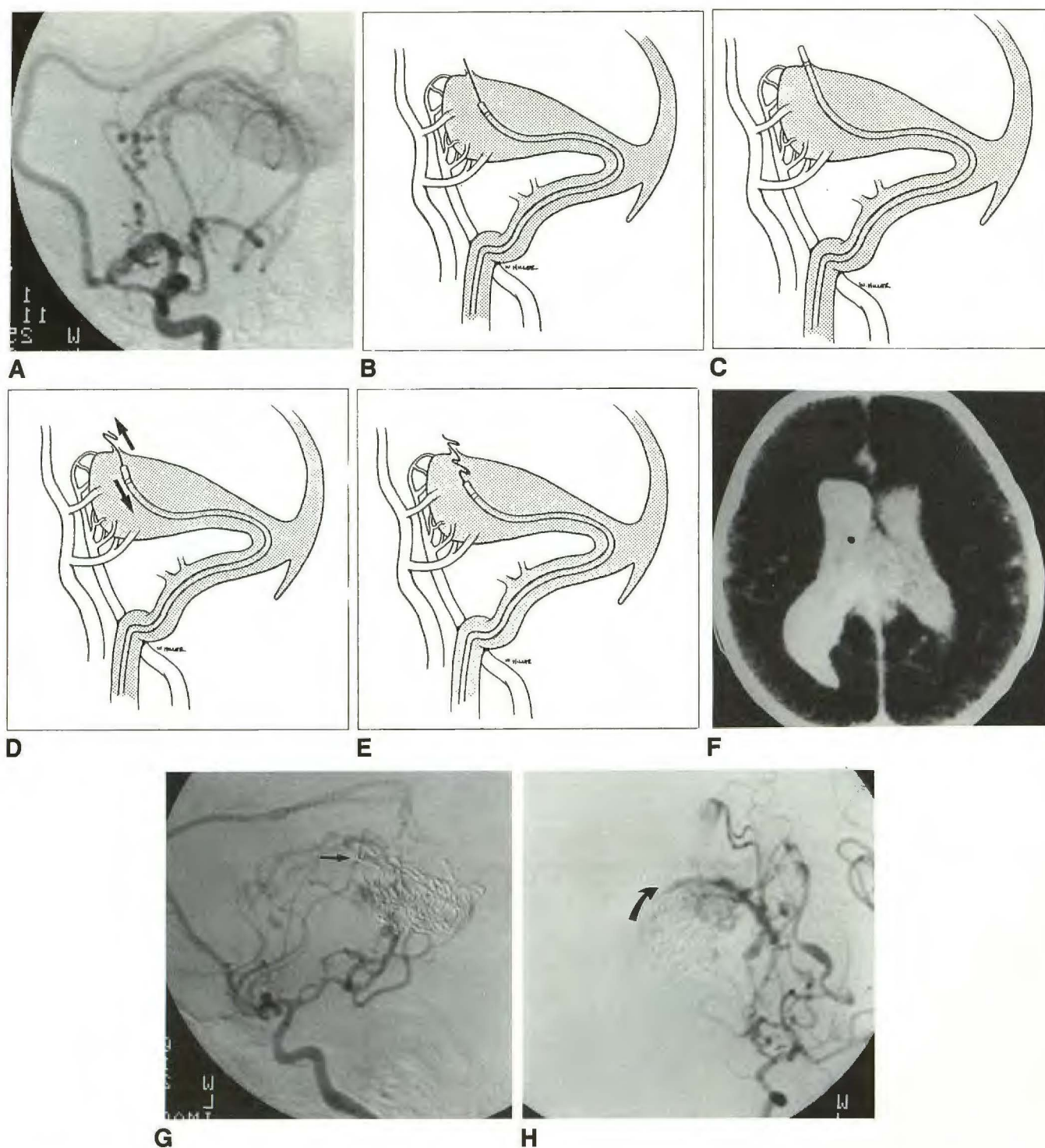


Fig. 4.—Case 2: 8-day-old boy with severe intractable congestive heart failure.

A, Left internal carotid injection, lateral projection, shows a vein of Galen malformation supplied by distal anterior cerebral artery, thalamoperforator arteries, and striate arteries.

B–E, Artist's conception of sequence of events during transvenous catheterization of vein of Galen.

B, During navigation of catheter into vein of Galen, the 0.22-in. guidewire was noted fluoroscopically to leave confines of vein of Galen.

C, Catheter was immediately advanced over guidewire through perforation site. Contrast injected here confirmed an extravascular location.

D, A Gianturco 0.25-in. coil was pushed through the catheter and the end deposited outside the perforation (arrows).

E, Simultaneously, the catheter was withdrawn to leave the coil outside, through, and inside the perforation site. An additional 42 coils were placed into vein of Galen to promote thrombosis.

F, CT scan obtained immediately after completion of initial embolization and repair of perforation shows contrast material within ventricular system and subarachnoid space, with greatest concentration of contrast material in right lateral ventricle. A small air bubble is additionally noted within ventricle.

G, Follow-up angiogram obtained 3 days after transvenous embolization with 43 Gianturco coils shows single coil (arrow) that sealed the perforation produced during previous embolization.

H, Left internal carotid injection, right anterior oblique projection, shows site of perforation, which is closed by the single coil across perforation site (arrow) without evidence of pseudoaneurysm formation.

Discussion

Vascular perforations occurring during placement and manipulation of catheters and guidewires are well described in regions outside the CNS [1–11]. In the vast majority of these cases treatment has consisted of surgical repair of the perforation. The relatively new development of smaller microcatheters, balloons, and steerable microguidewires has only recently allowed direct access to the cerebral and spinal cord vasculature. Many of the disease areas currently treated by endovascular surgeons contain thin-walled feeding arteries or veins, which are at an increased risk of rupture. While surgical repair of vascular perforations is an accepted practice outside the CNS, it is frequently not practical or possible within the cranial cavity. The CNS is exquisitely sensitive to even small amounts of extraluminal blood; therefore, immediate cessation of hemorrhage is essential for a good outcome. Even emergency neurological surgery may take hours before a bleeding site is approached, during which continued hemorrhage can be catastrophic. In addition, many of the vascular lesions currently treated by endovascular techniques are in surgically unapproachable regions. For example, the feeding arteries most often embolized as a preoperative adjunct for AVMs lie deep to the malformation and are most difficult to access surgically, as in cases 1, 3, 4, and 8. The most expeditious treatment would be occlusion of the perforation by the offending catheter or balloon.

Feeding arteries and draining veins often enlarge in caliber in response to the high-flow, low-resistance shunting of AVMs and fistulas. These vessels can become thin-walled and develop loss of intimal integrity [16]. Several perforations in our series occurred as a result of mechanical perforation of an artery, usually at a sharp bend or angulation. A guidewire near the tip of the catheter adds stiffness to the overall system and can puncture the artery. In case 3 a prototype guidewire with an unusually stiff tip was probably responsible for the perforation. Since this time, wire tips have been designed that are much softer than those used in our series. Stiff catheters have also been implicated in venous perforations occurring during central venous catheterization [17]. The development of softer guidewires and catheters should reduce the risk of such perforations. Additionally, low-friction guidewires and catheters enable the perception of increased resistance of a sharp bend or curve before a perforation occurs. Of note in our series is the high percentages of ruptures involving the anterior choroidal artery, an artery infrequently catheterized. In two patients (cases 1 and 4), a sharp angulation of the origin of this vessel (best appreciated in a Towne's projection), made catheterization difficult. This angulation was the perforation site in both instances.

In the third instance (case 8), a distal pseudoaneurysm ruptured during embolization with polyvinyl alcohol particles. The small anterior choroidal artery may have had some degree of flow restriction by the Tracker catheter. When the arteriovenous shunting was reduced with partial embolization, the pressure of each additional injection may have exceeded the compliance of the pseudoaneurysm. This important mechanism must be recognized when embolizing in a small compartment, such as transvenously in the cavernous sinus.

During embolization of a cavernous sinus dural fistula with venous outflow obstruction, high pressure generated by the fluid used to inject silk suture embolic material may produce rupture of a posterior fossa vein, as in case 13. This can be avoided by injecting small volumes of liquid and increasing the time between each injection, thus allowing for equilibration and equalization of pressure. Pressure injection has been suggested as a reason for 34 reported cases of aneurysmal rerupture during cerebral angiography [12, 13]. Duckwiler et al. (paper presented at International Neuroradiology Conference, Val d'Isere, France, January 1989) and Jungreis [18] have demonstrated the usefulness of pressure monitoring during embolization, which may offer additional clues to the risk of this complication.

Mechanical rupture of an aneurysm or dysplastic vessel can occur with minimal overdilation of a balloon. To avoid such an occurrence, roadmaps should be of excellent quality to ensure inflation to the desired volume, and any distortion in the shape of the balloon should be carefully monitored, since this can be an early clue to a restricted amount of space. The use of soft balloons, such as the newer, softer silicone elastomer balloons, can minimize the stress on the wall of the aneurysm. The use of balloons that require a low detachment force will reduce the risk of tearing or stretching the neck of the aneurysm but carries the increased risk of premature detachment. Placement of a second balloon transiently within the parent artery during detachment can reduce the risk that the intraaneurysmal balloon will dilate and tear the neck of the aneurysm. Allowing full solidification of the balloon contents prevents the balloon from elongating and distorting, again reducing the stress placed on the neck of the aneurysm during detachment. If rupture of an aneurysm occurs, few options are available. The balloon within the aneurysm can be slightly overinflated (as in case 10) to seal the perforation. If parent artery occlusion can be tolerated, then balloon trapping may be performed. Systemic hypotension, an adjunct often used in surgery to reduce uncontrolled hemorrhage, could be useful in the acute stages, but was not evaluated in this series.

Perforation can also occur during advancement or withdrawal of a microcatheter. If drip perfusion between the guidewire and catheter is excessive, or forceful injections made through the catheter exceed the compliance of this small vessel, perforation can ensue. We avoided this complication in our series by observing the hub of the Tracker for a vacuum phenomenon (lowering the fluid level while withdrawing the guidewire), which may be a clue that the tip of the catheter is occlusive. We always injected a small amount of contrast material (0.1 ml) upon a blank roadmap (subtracted image) slowly over several seconds. If a small perforator was observed, the injection was terminated and the catheter withdrawn. If nothing was observed with the slow injection of contrast material—owing to washout in a large, fast-feeding vessel—then a more vigorous injection was administered. An alternative method to prevent inadvertent catheterization of small perforators is the use of a latex bulb on the catheter tip, which increases the size and allows better navigation through curves [19].

Perforation of a feeding artery by a guidewire or catheter

may have a better prognosis than rupture of a dysplastic vessel or aneurysm. The muscular wall of a normal artery can contract to seal a small perforation. Perforation of an aneurysm or dysplastic artery produces a tear in the thin-walled structure. Lacking a muscular wall, flowing blood can enlarge such a tear. Surgical experience with ruptured aneurysms shows that rapid closure or blockage of the tear is essential to prevent extension of the tear and more massive bleeding. Of the 34 reported cases of aneurysmal rupture occurring during cerebral angiography [12, 13], 23 (68%) of the patients died, five (15%) developed strokes, leaving only three (9%) neurologically intact. In case 10, aneurysm rupture was recognized immediately via fluoroscopy, and was signaled by the onset of headaches. The balloon was slightly overinflated to seal the perforation successfully.

After a perforation is managed successfully, CT should be performed to document the location of the perforation and assess any resulting hematomas or hydrocephalus. The high concentration of contrast material is generally much denser than subarachnoid blood, and makes detection and quantification of the hemorrhage difficult. Antiseizure medication can be administered, especially if a high concentration of localized contrast agent is noted, as happened in two of our cases.

Immediate recognition of the perforation is essential to allow for prompt reversal of anticoagulation (if utilized) and definitive closure. As mentioned earlier, excellent-quality roadmapping allows guiding of balloons, catheters, and guidewires within the vascular system, and allows instantaneous recognition of a perforation. In such an instance, the offending balloon, guidewire, or catheter may be occluding the rupture site, and therefore should not be withdrawn immediately. In cases where the guidewire alone has produced a perforation, the catheter may be advanced over the wire to seal the hole and allow deposition of a wire coil to seal the site of perforation. Once the catheter tip is outside the vascular system, the wire can be withdrawn. Aspiration of CSF can confirm the location within the subarachnoid or intraventricular space. If no fluid can be aspirated, then a blank roadmap can be used to visualize a small injection of contrast material. Ionic contrast medium has a greater anticoagulant effect than does newer, nonionic contrast material. In addition, the high osmotic concentration of ionic contrast medium can produce seizures, and the less irritating nonionic contrast medium is preferable.

Once the extravascular location is determined, as much contrast material as possible should be aspirated back to minimize the risks of seizure. The small amount of remaining contrast medium can be used as reference to document the site of rupture and serve as a baseline for the acute development of hydrocephalus (as in case 8) (Fig. 3D). Any systemic anticoagulation should be reversed immediately, and control clotting parameters checked to ensure return of baseline clotting function. Even small amounts of hemorrhage will produce a severe headache, often within seconds. Nausea may accompany this reaction, so it is important to make the patient comfortable with analgesics and antiemetics. However, phenothiazines, such as Compazine, could lower the seizure threshold and should be avoided. In cases 2, 3, 5, 7, and 14, a coil or coils were advanced to the tip of the catheter

and deposited outside, across, and proximal to the perforation. In case 4, in which the site of perforation was close to the origin of the anterior choroidal artery, a nondetachable balloon was placed across the perforation site for several minutes before and after the catheter was removed. No extravasation was noted after the balloon was deflated. In the three patients (cases 6, 9, and 14) in whom the site of perforation was distal to the catheter tip, embolization with polyvinyl alcohol particles and liquid adhesives was adequate to seal the rupture site. The choice of embolic agent depends on the position of the catheter in relation to the perforation site as well as the normal vascular territory supplied by that artery.

Two deaths occurred in this series, both resulting from massive subarachnoid hemorrhage. In case 15, we were trying to dislodge an errant embolus from the basilar tip with a balloon, when rupture, massive bleeding, and death occurred. In the second case, motion prevented recognition of the rupture site. Of the remaining 13 patients, one died from unrelated causes and 12 are alive and well. The two patients (cases 12 and 14) who initially suffered a single seizure from contrast material and/or blood, remain seizure-free and off all medications. The two patients who developed new neurologic deficits secondary to their rupture, have completely recovered from their deficits. Two long-term sequelae in the surviving patients in this series include a hydrocephalus treated with shunting in one patient and diabetes insipidus in the other. The infant developed hydrocephalus within several weeks of the perforation and repair. He was shunted and the hydrocephalus resolved. He is now neurologically intact and without symptoms at 13 months after the procedure. The second patient had a history consistent with diabetes insipidus prior to treatment. The perforation was sealed with liquid adhesive injected into the cavernous sinus. She developed laboratory-documented diabetes insipidus and has been effectively treated with exogenous administration of synthetic antidiuretic hormone.

Owing to recent advancements in the field of interventional neuroradiology—including high-resolution fluoroscopy, roadmapping techniques, newer embolic agents, softer microcatheters, and steerable guidewires—it is now possible to access the distal intracerebral vasculature for treatment of vascular malformations and aneurysms. Concomitant with these advances is the inherent risks of perforations and damage to the intravascular system. If these perforations can be immediately recognized and prompt therapy instituted, then damage to the brain can be minimized.

REFERENCES

1. Girault A. Detection precoce des perforations vasculaires lors du catheterisme des veines sous-clavieres. *Presse Med* 1985;14:432
2. Otteni JC, Gaudias J, Mayer JF. Lesions veineuses en relation avec les injections et l'utilisation de catheters. *Phlebologie* 1985;38:575-588
3. Girault A. Traitement des perforations vasculaires cours du catheterisme de la sous-claviere. *Presse Med* 1986;15:81
4. Arakawa A, Nagata Y, Inami H, Takahashi M. Arterial rupture as a complication of steal coil embolization in neurofibromatosis. *Rinsho Hoshasen* 1987;32:955-957

5. Jensen SR, Voegeli DR, Crummy AB, Turnipaseed WD, Acher CW, Goodson S. Iliac artery rupture during transluminal angioplasty: treatment by embolization and surgical bypass. *AJR* **1985**;145:381-382
6. Sata T, Higashi Y, Ono Y. Sonography of gallbladder perforation: a complication of transcatheter hepatic arterial embolization. *J Ultrasound Med* **1986**;5:715-718
7. Lina JR, Jaques P, Mandell V. Aneurysm rupture secondary to transcatheter embolization. *AJR* **1979**;132:553-556
8. Otteni JC, Grandhavye N, Dupeyron JP, Gauthier Lafaye JP. Deux complications frequentes des catheters veineux: les fausses routes et les perforations vasculaires. Interet dun controle radiographique systematique du catheter. *Anesth Analg* **1971**;28:1149-1170
9. Neveisteen A, Suy R. Arterial rupture and pseudoaneurysm formation secondary to the use of the Fogarty balloon catheter. *Acta Chir Belg* **1987**;87:300-303
10. Dean RH, Callis JT, Smith BM, Meacham PW. Failed percutaneous transluminal renal angioplasty: experience with lesions requiring operative intervention. *J Vasc Surg* **1987**;6:301-307
11. Katzen BT. Percutaneous transluminal angioplasty for arterial disease of the lower extremities. *AJR* **1984**;142:23-25
12. Tsementzis SA, Kennett RP, Hitchcock ER. Rupture of intracranial vascular lesions during arteriography. *J Neurol Neurosurg Psychiatry* **1984**;47:795-798
13. Dublin AB, French BN. Cerebral aneurysm rupture during arteriography with confirmation by computed tomography. A review of intra angiography aneurysmal rupture. *Surg Neurol* **1980**;13:19-27
14. Shiu PC, Hanafee WN, Wilson GH, Rand RW. Cavernous sinus venography. *Radiology* **1968**;104:57-62
15. Purdy PD, Samson D, Batjer HH, Risser RC. Preoperative embolization of cerebral arteriovenous malformations with polyvinyl alcohol particles: experience in 51 adults. *AJNR* **1990**;11:501-510
16. Pile Spellman J, Baker KF, Liszczak TM, et al. High-flow angiopathy: cerebral blood vessel changes in experimental chronic arteriovenous fistula. *AJNR* **1986**;7:811-815
17. Berster AD, Williams DR, Phillips GD. Central venous catheter stiffness and its relation to vascular perforation. *Anaesth Intensive Care* **1988**;16:342-351
18. Jungreis CA, Horton JA, Hecht ST. Blood pressure changes in feeders to cerebral arteriovenous malformations during therapeutic embolization. *AJNR* **1989**;10:575-577
19. Vinuela F, Dion J, Lylyk P, Duckwiler G. Update on interventional neuroradiology. *AJR* **1989**;153:23-33