



Discover Generics

Cost-Effective CT & MRI Contrast Agents



WATCH VIDEO

AJNR

Nasopharyngeal carcinoma: CT evaluation of patterns of tumor spread.

J S Sham, Y K Cheung, D Choy, F L Chan and L Leong

AJNR Am J Neuroradiol 1991, 12 (2) 265-270

<http://www.ajnr.org/content/12/2/265>

This information is current as
of June 19, 2025.

Nasopharyngeal Carcinoma: CT Evaluation of Patterns of Tumor Spread

Jonathan S. T. Sham¹
Y. K. Cheung²
D. Choy¹
F. L. Chan²
Lilian Leong²

In a prospective study using CT as the initial means of radiologic evaluation in 262 patients with proved nasopharyngeal carcinoma, the paranasopharyngeal space was found to be the most commonly involved region (84.4%), both uni- and bilaterally. Unilateral involvement was found in 44.3% of patients (116/262) and bilateral involvement in 40.1% (105/262). The other structures or regions that were involved, in decreasing order of frequency, were the sphenoid sinus (26.7%), nasal fossa (21.8%), and ethmoid sinus (18.3%). Erosion of the base of the skull and intracranial extension into the middle cranial fossa were common (31.3% and 12.2%, respectively). The primary tumor in the nasopharynx was found to be contiguous with metastatic upper cervical nodes through paranasopharyngeal extension of tumor in 35 patients (13.4%). A qualitative method to assess the degree of paranasopharyngeal extension is proposed. The extent of paranasopharyngeal extension so evaluated was correlated with other attributes of tumor extent ($p = .0001$), namely, nasal or oropharyngeal extension, which constitutes a T3-level tumor, and erosion of the base of the skull or orbit, which constitutes a T4-level tumor. The extent of paranasopharyngeal extension was also correlated with local control of the tumors ($p = .0001$). At a median follow-up of 27 months, only three (7.9%) of the 38 patients with no paranasopharyngeal extension had nasopharyngeal relapse, while 12 (11.2%) of the 107 and 17 (34.7%) of the 49 patients with types 1 and 2 paranasopharyngeal extension, respectively, had nasopharyngeal relapse.

CT was useful in (1) delineating the extent of tumor, especially erosion of the base of the skull and intracranial extension of tumor; (2) evaluating lateral extension of tumor to the paranasopharyngeal space; and (3) documenting extensive posterolateral extension of tumor contiguous with metastatic cervical nodes.

AJNR 12:265-270, March/April 1991

In the staging of nasopharyngeal carcinoma (NPC) emphasis has always been on the number of side walls involved by tumor, the anterior extension to the nasal fossa, the inferior extension to the oropharynx, and the superior extension to erode the base of the skull [1]. Little emphasis has been placed on lateral and posterolateral extension of tumor. Experience with CT shows that lateral and posterolateral extension of this tumor occurs early in the course of this disease [2, 3], a propensity for early extension to the paranasopharyngeal space is characteristic of NPC, and this type of extension is a point in differentiating NPC from other malignant tumors extending or spreading to involve the nasopharynx [2].

A large body of literature has accumulated on the use of CT in the evaluation of the nasopharynx and tumors arising from this region. However, most of the articles on NPC describe small or selected groups of patients, probably because this tumor is not common in most parts of the world. NPC is common in Hong Kong, since 98% of the population are of Southern Chinese origin. In recent years we have used CT as a routine baseline study for new NPC patients. We report our experience with the CT evaluation of tumor spread at initial presentation, with special emphasis on the qualitative assessment of paranasopharyngeal extension of tumor.

Received April 30, 1990; revision requested July 3, 1990; final revision received October 12, 1990; accepted October 17, 1990.

This work was supported by grants from the Asian Oceanian Clinical Oncology Association.

¹ Department of Radiotherapy and Oncology, Queen Mary Hospital, Pokfulam, Hong Kong. Address reprint requests to J. S. T. Sham.

² Department of Diagnostic Radiology, Queen Mary Hospital, Pokfulam, Hong Kong.

0195-6108/91/1202-0265

© American Society of Neuroradiology

Subjects and Methods

We prospectively studied 262 patients with newly diagnosed NPC who were seen between January 1987 and December 1988 in the Department of Radiotherapy and Oncology, Queen Mary Hospital, Hong Kong. Over this period, 271 consecutive patients were seen in this department; nine patients were excluded from the study because CT was not performed before treatment was started.

Pretreatment CT consisted of contiguous axial scans obtained at 5-mm intervals with the infraorbitomeatal line parallel to the gantry.

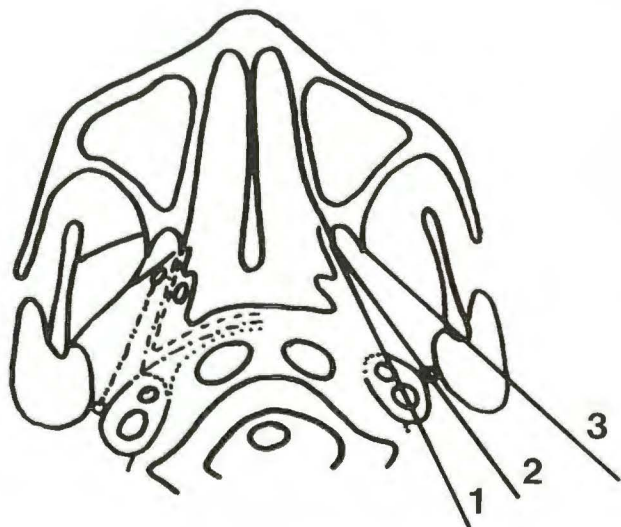


Fig. 1.—Schematic drawing outlines pharyngobasilar fascia (broken line), buccopharyngeal fascia (dot-dash line), prevertebral fascia (dotted line), and tensor palatini fascia (dash-dot-dot line), on right side. On left side are the three lines for evaluating degree of paranasopharyngeal extension: 1 = into retrostyloid space; 2 = into prestyloid space; 3 = into anterior part of masticator space.

Scans were obtained from the suprasellar cistern to the C3 vertebra for evaluation of the base of the skull, nasopharynx, and paranasopharyngeal space. IV contrast material was injected as a bolus followed by rapid infusion in order to enhance the difference between the tumor and normal tissue and to delineate the carotid arteries and jugular veins. Ten patients were not injected because of an allergic history to iodine. Coronal CT was not used as a routine investigation.

All the scans were evaluated for the involvement or destruction of the structures or regions adjacent to the nasopharynx, especially the base of the skull, and also for involvement of the upper neck by direct extension of tumor or metastatic lymphadenopathy. Erosion of the base of the skull is present when there is erosion of the sphenoid sinus, clivus, petrooccipital fissure, petrous temporal bone, or greater wing of the sphenoid.

Involvement of the paranasopharyngeal space was evaluated with reference to three lines: The first line extends from the free edge of the medial pterygoid plate posterolaterally to the lateral border of the carotid artery, corresponding to the pharyngobasilar fascia before it reflects medially over the prevertebral muscles to end in the median raphe [4]. The second line extends from the scaphoid fossa at the base of the medial pterygoid plate posterolaterally to the styloid process, corresponding to the tensor palatini fascia [5]. The third line extends from the free edge of the lateral pterygoid plate posterolaterally to the posterior border of the ascending ramus of the mandible; this is an arbitrary line chosen because of the relatively constant landmarks. The first line marks the boundary of the nasopharynx proper from the paranasopharyngeal space laterally. The third line divides the masticator space. The second paranasopharyngeal line separates the prestyloid space anteriorly from the retrostyloid space posteriorly. The tumor is considered confined to the nasopharynx, with no paranasopharyngeal extension, if the tumor is confined medial to the first line. Tumors extending into the retrostyloid space, prestyloid space, and anterior part of the masticator space, by reaching or extending beyond the first, second, and third lines, respectively, were ranked as types 1–3 paranasopharyngeal extension, respectively (Fig. 1).

Correlations between the degree of paranasopharyngeal extension on two sides, between erosion of the base of the skull and intracranial

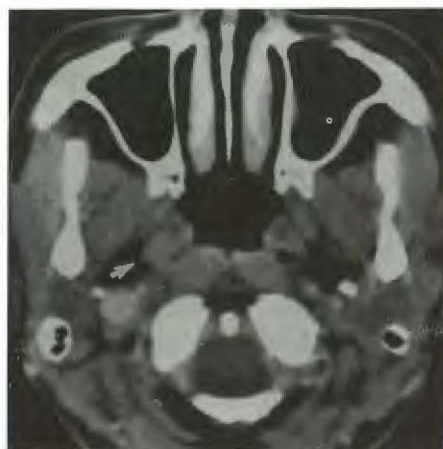


Fig. 2.—Type 1 paranasopharyngeal extension on right side. Tumor (arrow) has extended beyond line joining medial pterygoid plate and lateral border of carotid artery. Note absence of paranasopharyngeal extension on left side.

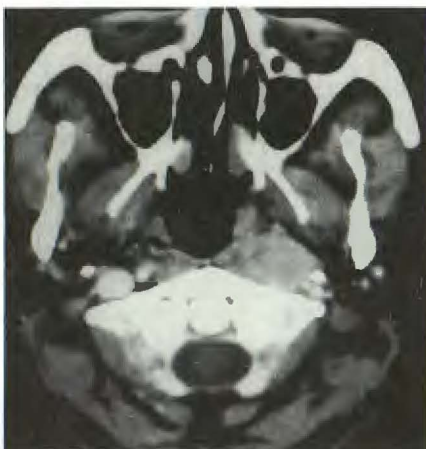

Fig. 3.—Type 2 paranasopharyngeal extension on left side. Tumor has extended beyond line joining scaphoid fossa at base of medial pterygoid plate and styloid process. Note absence of paranasopharyngeal extension on right side.

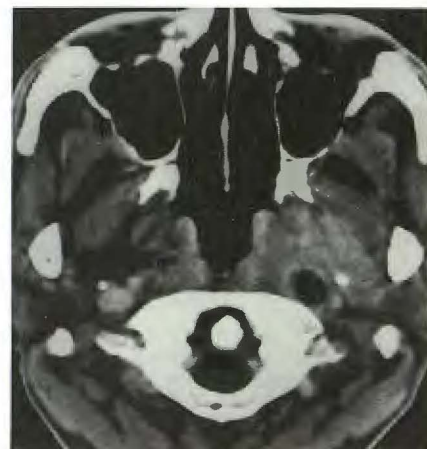


Fig. 4.—Type 3 paranasopharyngeal extension on left side. Tumor has extended beyond line joining lateral pterygoid plate and posterior border of ascending ramus of mandible. Note central necrosis of node in left paranasopharyngeal space and absence of paranasopharyngeal extension on right side.

extension of tumor, and between the degree of paranasopharyngeal extension and extension of tumor in other directions were computed by chi-square test.

Results

The paranasopharyngeal space was the most commonly involved region. Some degree of paranasopharyngeal extension was found in 221 patients (84.4%); 44.3% (116/262) had unilateral involvement and 40.1% (105/262) had bilateral involvement. The occurrence and degree of paranasopharyngeal extension of tumor on the two sides were not interrelated (Figs. 2–4; Table 1). The other structures or regions that were involved, in decreasing order of frequency, were sphenoid sinus (26.7%), nasal fossa (21.8%), and ethmoid sinus (18.3%). The sphenoid sinus was also the second most commonly involved region bilaterally (Table 2).

Erosion of the base of the skull and intracranial extension into the middle cranial fossa were common (31.3% and 12.2%, respectively) (Figs. 5–7). Thirty-two patients had intracranial extension of the tumor into the middle cranial fossa, 11 and 15 with unilateral involvement of the right and left

sides, respectively, and six patients with bilateral involvement. There was associated erosion of the base of the skull on the ipsilateral side in all except one patient in whom there was unilateral erosion of the base of the skull on the right side but bilateral intracranial extension (Table 3). It was not uncommon to find patients with erosion of the base of the skull unaccompanied by CT-detectable gross intracranial tumor extension. Intracranial extension into the posterior cranial fossa was not so common (Fig. 6), and no patient had erosion of the floor of, or intracranial extension into, the anterior cranial fossa (Table 2).

The primary tumor in the nasopharynx was found to be contiguous with the metastatic upper cervical nodes, indirectly through paranasopharyngeal extension of the tumor, in 35 patients (13.4%). This occurred unilaterally in 33 patients and bilaterally in another two patients (Figs. 7D and 8).

Of the 262 patients, 109 (41.6%) either had evidence of nasal or oropharyngeal extension, which qualified their tumors as T3 disease, or had erosion of the base of the skull, qualifying their tumors as T4 disease according to the staging system of the American Joint Committee on Cancer (AJCC) [1]; some had even more extensive disease, with tumor involving the infratemporal fossa or orbit. The other 153 patients (58.4%) had no such extension. The degrees of paranasopharyngeal extension for those patients with nasal or oropharyngeal extension (T3 tumor), those with base of skull or orbit erosion (T4 tumor), and those with no such extension (T1 or T2 tumor) are shown in Table 4 for the right and left sides. There was significant correlation between the degree of paranasopharyngeal extension on each side and these known attributes of tumor extent ($p = .0001$ for both sides).

TABLE 1: Correlation of Degrees of Paranasopharyngeal Extension on Right and Left Sides

Right Paranasopharyngeal Space	Left Paranasopharyngeal Space (n = 262)			
	Not Involved	Type 1	Type 2	Type 3
Not involved	41	45	12	2
Type 1	34	41	19	2
Type 2	16	19	15	3
Type 3	7	3	2	1

Note.—Type 1 tumors extended into the retrostyloid space; type 2, the prestyloid space; and type 3, the anterior part of the masticator space. ($p = .22$)

TABLE 2: Frequency of Involvement of Individual Structures and Regions

Structure or Region	No. of Patients (n = 262)		
	Not Involved	Unilateral Involvement	Bilateral Involvement
Paranasopharyngeal extension	41	116	105
Anterior cranial fossa extension	262	0	0
Middle cranial fossa extension	230	26	6
Sphenoid sinus	192	29	41
Clivus	234	17	11
Greater wing of sphenoid	228	27	7
Petrooccipital fissure	239	17	6
Petrous temporal bone	233	24	5
Posterior cranial fossa extension	251	7	4
Posterior ethmoid	214	27	21
Anterior ethmoid	240	12	10
Nasal fossa	205	46	11
Pterygoid plates	232	28	2
Pterygomaxillary fissure	237	22	3
Infraorbital fissure	225	31	6
Antrum	245	15	2
Orbit	255	7	0
Oropharyngeal extension	227	33	2

Discussion

Although it has been documented that the paranasopharyngeal space is involved early in the course of NPC, no simple way has been proposed to assess the extent of paranasopharyngeal involvement [2, 3]. We have proposed a simple means, based on anatomic planes, to qualitatively assess paranasopharyngeal extension of NPC, and have found it is an important attribute in describing the extent of NPC. It was also found that most cases of intracranial extension into the middle cranial fossa were associated with erosion of the base of the skull. Although such a finding had no direct bearing on the radiation therapy technique, it furthers our understanding of this tumor. It also demonstrates the usefulness of CT in the evaluation of subtle bone erosion, which perhaps explains the previous belief that NPC, by nature of its infiltrative behavior, more often extends intracranially through the foramen lacerum (perivascular spread) into the cavernous sinus, or through the foramen ovale (perineural spread), than by erosion of the base of the skull [3].

For the evaluation of NPC, MR imaging has a distinct advantage over CT. It offers superior tissue contrast and provides better distinction between tumor and surrounding soft tissue [6], so that the true tumor margin and the involvement of adjacent muscles and spaces can be better defined.

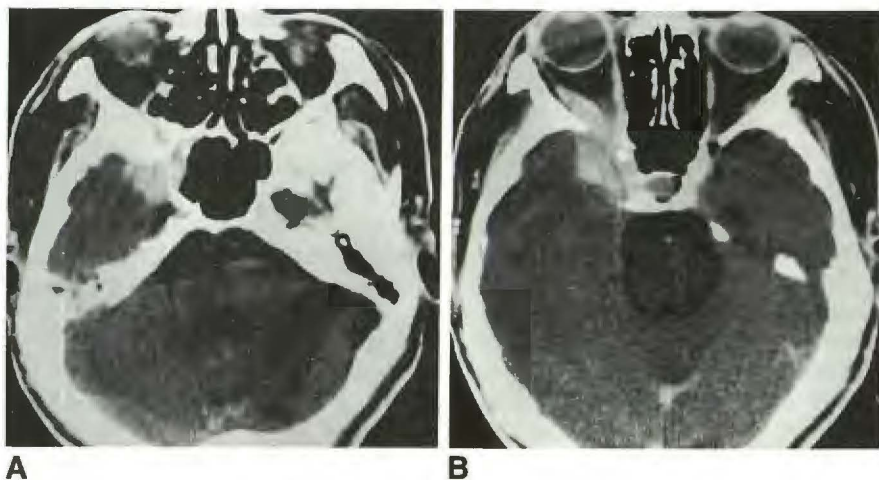
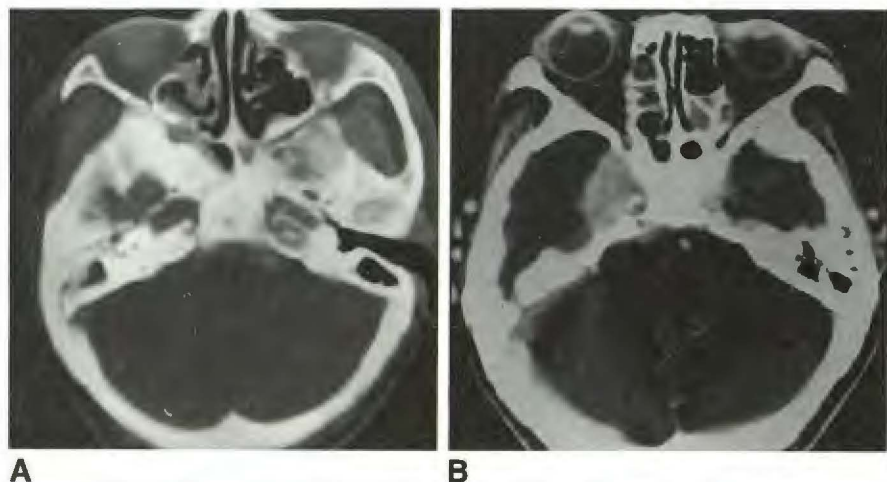


Fig. 5.—**A**, Tumor erosion of sphenoid sinus and infraorbital fissure and tumor extension into middle cranial fossa.

B, More cephalad image shows involvement of temporal lobe and erosion and extension into right orbit with associated proptosis.

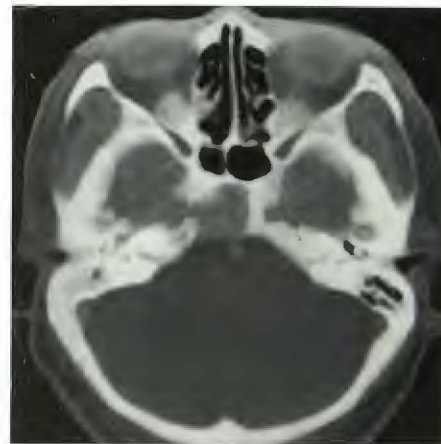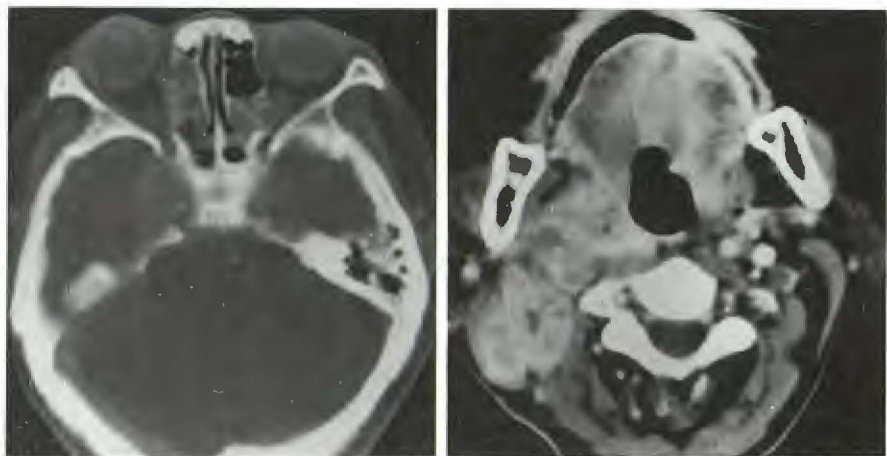


Fig. 6.—Erosion of clivus with extension into posterior cranial fossa.



A

B



C

D

Fig. 7.—**A**, Erosion of right infraorbital fissure, tumor extension to adjacent ethmoid cells, and sclerosis and erosion of greater wing of sphenoid and petrous temporal bone.

B and **C**, More cephalad images show extension of tumor into middle cranial fossa and bilateral ethmoid inflammatory changes.

D, More caudal image shows right oropharyngeal extension of tumor contiguous with metastatic neck nodes and associated vascular encasement.

Sinus mucosal thickening resulting from obstruction can be differentiated from tumor invasion easily with MR. Vessels and their relationship to the tumor are readily demonstrated by MR without injection of IV contrast material. The direct

multiplanar capability and lack of beam-hardening artifacts in MR also allow more accurate assessment of superoinferior tumor extension and intracranial spread.

Unfortunately, MR is not widely available in this part of the

TABLE 3: Correlation Between Intracranial Extension of Tumor into Middle Cranial Fossa and Erosion of Skull Base

Type of Tumor Extension into Middle Cranial Fossa	Type of Skull-Base Erosion (n = 262)			
	None	Right Side	Left Side	Bilateral
None	180	13	12	25
Right side	0	6	0	5
Left side	0	0	6	9
Bilateral	0	1	0	5

Note.— $p = .0001$.

TABLE 4: Correlation of Tumor Extension to Base of Skull, Nasal Fossa, and Oropharynx with Right and Left Paranasopharyngeal Extension of Tumor

Side of Paranasopharyngeal Extension/Type	No. (%)		
	Extension to Skull Base, Orbit, or Infratemporal Fossa (n = 67)	Extension to Nasal Fossa or Oropharynx (n = 42)	No Corresponding Extension (n = 153)
Right			
None	14 (20.9)	12 (28.6)	74 (48.4)
Type 1	18 (26.9)	12 (28.6)	66 (43.1)
Type 2	23 (34.3)	17 (40.4)	13 (8.5)
Type 3	12 (17.9)	1 (2.4)	0
Left			
None	19 (28.3)	14 (33.3)	65 (42.5)
Type 1	20 (29.9)	18 (42.9)	70 (45.7)
Type 2	20 (29.9)	10 (23.8)	18 (11.8)
Type 3	8 (11.9)	0	0

Note.—Type 1 tumors extended into the retrostyloid space; type 2, the prestyloid space; and type 3, the anterior part of the masticator space. ($p = .0001$)

world, where NPC is common. The application of MR in the evaluation of our patient population thus is limited. MR also has its limitations: its longer scanning time makes it more susceptible to motion artifacts, and subtle bone erosion is still better demonstrated by CT. Although the soft-tissue contrast resolution of CT is not as good as that of MR, by paying attention to obliteration or displacement of deglutitional and masticatory muscle layers and by noting abnormalities of the fibrofatty spaces, one can detect relatively early soft-tissue changes of NPC [7, 8].

The early involvement of the paranasopharyngeal space is not unexpected in NPC. At the level of nasopharynx the superior pharyngeal constrictor is attenuated to become the pharyngobasilar fascia [9]. On this fascia, next to the pharyngeal recess, is an opening (the sinus of Morgagni) through which the levator palatini passes from its origin on the part of temporal bone lateral to the attachment of the pharyngobasilar fascia to within the nasopharynx [10]. This opening offers relatively little resistance to the spread of tumor to the paranasopharyngeal space [11]. The proximity of this opening to the pharyngeal recess, which is the preferred site for the development of NPC [12], can easily explain the early invasion of the paranasopharyngeal space compared with tumor extension to the nasal fossa, oropharynx, and other structures, and the erosion of base of skull.

It is also easy to explain the emphasis of the AJCC staging system on superior, anterior, and inferior extension of tumor

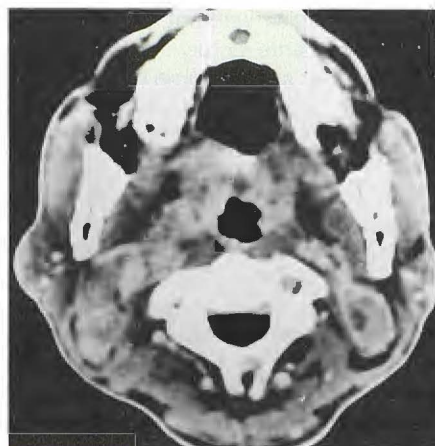


Fig. 8.—Bilateral enlarged metastatic neck nodes. Nodes on right side are contiguous with paranasopharyngeal extension of tumor. There is associated vascular involvement on right side.

by the anatomy of the nasopharynx, which is situated in the center of the head. Superiorly the nasopharynx is in juxtaposition to the base of the skull, laterally it is bounded by the ascending rami of the mandible, posteriorly it is bounded by the vertebral column, anteriorly it is continuous with the nasal fossa, and inferiorly it is continuous with the oropharynx. It can be envisaged that extension into the nasal fossa and oropharynx are easily assessable by clinical examination, while upward extension to involve the base of the skull can be monitored by conventional radiography. Before the use of CT [13], lateral and posterolateral extension of tumor was not easily assessed until the tumor became palpable clinically, while tumor erosion of the mandible to the degree that it became detectable on plain radiographs occurred late and was uncommon.

It is interesting to note that, in many of the reported series on NPC, there was an unusual T-stage distribution. T staging measures the extent of the primary tumor. The proportion of patients with nasal or oropharyngeal involvement, which qualifies as more extensive disease than tumor confined to the nasopharynx, varies from 2.8% to 21% [14–18], and was usually less than 10%; the proportions of patients with tumor confined to the nasopharynx and with tumor more extensive than T3 disease were around 60% and 25%, respectively. It is difficult to imagine why the tumors either were localized and confined to the nasopharynx or were very advanced with erosion of the base of the skull, with very few cases being intermediate in extent. The prognosis of patients with tumor limited to the nasopharynx has been reported as comparable to that of patients with nasal or oropharyngeal extension [14, 17]. This indicates the presence of other attributes of tumor extent, which are not measured by the current staging systems, that mask the difference between these two groups of patients and that may account for the polarization of cases to the extremes of the T-stage distribution. Sham and Choy [18] have reported the adverse prognostic significance of ear symptoms in patients with T1 tumor. It has been shown that serous otitis media is related to paranasopharyngeal extension of tumor [3, 19]. It is possible that paranasopharyngeal

extension of tumor, which was not evaluated in their study [18], was a hidden adverse factor.

We have shown that some degree of paranasopharyngeal extension of tumor, unilateral or bilateral, occurred in more than 80% of patients. Of the 159 patients who had no nasal or oropharyngeal extension nor erosion of the base of the skull to qualify their tumor as T3 or T4 disease in the AJCC staging system, 78.4% (120/153) had different degrees of paranasopharyngeal involvement. This finding concurs with the experience of Yu et al. [20].

We have further shown that qualitative evaluation with the use of the three anatomic reference lines separated lateral tumor extension into groups that correlate with the known attributes of tumor extent, namely, nasal and oropharyngeal extension and erosion into the base of the skull (Table 4). Furthermore, interim analysis of the subgroup of patients with T3 or less advanced disease, at a median follow-up of 27 months, showed that the degree of paranasopharyngeal involvement as evaluated by this qualitative method correlated with local control of tumor ($p = .0001$, Table 5). It is likely that this qualitative evaluation of paranasopharyngeal extension will be useful as an additional measure of tumor extent, perhaps to supplement the existing staging systems, especially for early cases.

Another finding of this study not previously reported in the literature is that the tumor in the nasopharynx is not uncommonly contiguous with the metastatic neck nodes, through its paranasopharyngeal extension. This is unusual for other head and neck tumors such as laryngeal and tongue cancers. Such a finding has an important bearing on the technique of radiotherapy for NPC; it has not been unusual for primary tumor and the neck lymphatics to be considered as two separate entities and treated as such [21, 22]. The target volume for the treatment of the primary tumor and neck nodes for patients with such CT features should be one unit, rather than two separate volumes, as there is virtually no tumor-free zone between the two areas.

In conclusion, CT has a definitive role in the evaluation of patients with NPC in places where MR equipment is not readily available. CT can accurately assess the extent of the tumor, especially extension to the paranasopharyngeal space.

TABLE 5: Correlation Between Local Control of Tumor and Degree of Paranasopharyngeal Extension for Tumors Not Exceeding Tumor Category T3

Degree of Paranasopharyngeal Extension	Relapse in Nasopharynx (n = 262)	
	Yes	No
None	35	3
Uni- or bilateral		
Not beyond retrostyloid space	95	12
Not beyond prestyloid space	32	17
Into anterior part of masticator space	0	1

Note.— $p = .0001$.

This aspect of tumor extension is likely to have a significant impact on prognosis. When paranasopharyngeal spread of tumor is extensive, especially when it is contiguous with the metastatic neck nodes, the technique of radiation therapy has to be modified accordingly.

REFERENCES

1. American Joint Committee on Cancer. *Manual for staging of cancer*, 3rd ed. Philadelphia: Lippincott, 1988
2. Hoover LA, Hanafee WN. Differential diagnosis of nasopharyngeal tumors by computed tomography. *Arch Otolaryngol Head Neck Surg* 1983;109:43-47
3. Silver AJ, Mawad ME, Hilal SK, Sane P, Ganti SR. Computed tomography of the nasopharynx and related spaces. Part II: Pathology. *Radiology* 1983;147:733-738
4. Mancuso AA, Bohman L, Hanafee W, Maxwell D. Computed tomography of the nasopharynx: normal and variants of normal. *Radiology* 1980;137:113-121
5. Tabor EK, Curtin HD. MR of the salivary glands. *Radiol Clin North Am* 1989;27:379-392
6. Dillon WP, Mills CM, Kjob B, et al. Magnetic resonance imaging of the nasopharynx. *Radiology* 1984;152:731-738
7. Silver AJ, Sane P, Hilal SK. CT of the nasopharyngeal region. Normal and pathologic anatomy. *Radiol Clin North Am* 1984;22:161-176
8. Hoe J. CT of nasopharyngeal carcinoma: significance of widening of the pre-occipital soft tissue on axial scans. *AJR* 1989;153:867-872
9. Romanes GJ. *Cunningham's manual of practical anatomy*. Vol III. *Head and neck and brain*, 13th ed. London: Oxford University, 1966:124-159
10. Proctor B. Anatomy of the eustachian tube. *Arch Otolaryngol Head Neck Surg* 1973;97:2-8
11. Batsakis JH. *Tumors of the head and neck: clinical and pathological considerations*, 2nd ed. Baltimore: Williams & Wilkins, 1979:188-199
12. Sham JST, Wei WI, Zong YS, et al. Detection of subclinical nasopharyngeal carcinoma by fiberoptic endoscopy and multiple biopsy. *Lancet* 1990;335:371-374
13. Silver AJ, Mawad ME, Hilal SK, Sane P, Ganti SR. Computed tomography of the nasopharynx and related spaces. Part I: Anatomy. *Radiology* 1983;147:725-731
14. Dickson RI, Flores AD. Nasopharyngeal carcinoma: an evaluation of 134 patients treated between 1971-1980. *Laryngoscope* 1985;95:276-283
15. Vikram B, Mishra UM, Strong EW. Pattern of failure in carcinoma of the nasopharynx: I. Failure at the primary site. *Int J Radiat Oncol Biol Phys* 1985;11:1455-1459
16. Moench HC, Phillips TL. Carcinoma of the nasopharynx, review of 146 patients with emphasis on radiation dose and time factor. *Am J Surg* 1972;124:515-518
17. Bedwinek JM, Perez CA, Keys DJ. Analysis of failures after definitive irradiation of epidermoid carcinoma of the nasopharynx. *Cancer* 1980;45:2725-2729
18. Sham JST, Choy D. Prognostic factors of nasopharyngeal carcinoma: a review of 759 patients. *Br J Radiol* 1990;63:51-58
19. Honjo I. Nasopharyngeal carcinoma and otitis media with effusion. In: Honjo I, ed. *Eustachian tube and middle ear diseases*. New York: Springer-Verlag, 1988:91-112
20. Yu ZH, Xu GZ, Huang YR, Hu YH, Su XG, Gu XZ. Value of computed tomography in staging the primary lesion (T-staging) of nasopharyngeal carcinoma (NPC): an analysis of 54 patients with special reference to the parapharyngeal space. *Int J Radiat Biol Phys Oncol* 1985;11:2143-2147
21. Qin D, Hu Y, Yan J, et al. Analysis of 1379 patients with nasopharyngeal carcinoma treated by radiation. *Cancer* 1988;61:1117-1124
22. Ho JHC. Nasopharynx. In: Halnan K, ed. *Treatment of cancer*. London: Chapman & Hall, 1982:249-267