



Discover Generics

Cost-Effective CT & MRI Contrast Agents

 FRESENIUS
KABI

[WATCH VIDEO](#)

AJNR

Subcutaneous sacrococcygeal myxopapillary ependymoma: CT and MR findings.

R C Domingues, D Mikulis, B Swearingen, R Tompkins and B R Rosen

AJNR Am J Neuroradiol 1991, 12 (1) 171-172

<http://www.ajnr.org/content/12/1/171.citation>

This information is current as
of June 6, 2025.

Subcutaneous Sacrococcygeal Myxopapillary Ependymoma: CT and MR Findings

We report a case of a primary subcutaneous sacrococcygeal ependymoma in a young woman. The differential diagnosis of palpable masses in the sacrococcygeal region must include the possibility of ependymoma.

Case Report

A 22-year-old woman had had pain in her coccyx for approximately 8 years. The pain was sharp, occurred at any time of day, and had no clear precipitating event. For the past 2 to 3 years, she had noted a lump in the cleft of the buttocks that she thought was slowly increasing in size.

Neurologic and physical examinations were normal except for the presence of a tender subcutaneous mass over the tip of the coccyx. On rectal examination, the anterior surface of the coccyx was smooth. CT scans showed a 3- to 4-cm well-defined midline lesion immediately deep to the natal cleft (Figs. 1A and 1B). The lesion was in contact with the dorsal surface of the coccyx, and no evidence of bone erosion or destruction was seen on bone-window scans. No other lesions were identified. Plain and contrast-enhanced MR studies (1.5 T) were performed to exclude myelomeningocele and tethered cord. The mass was sharply defined, slightly lobulated, and in contact with the dorsal surface of the distal coccyx over a distance of approximately 3–4 cm. It was isointense relative to muscle on a short TR/short TE spin-echo sequence and showed heterogeneous enhancement on the same sequence after injection of contrast material (Figs. 1C and 1D). The distal thecal sac, cauda equina, and conus were normal. No evidence was seen of intraspinal tumor, myelomeningocele, or tethering of the spinal cord. A myxopapillary ependymoma was diagnosed on the basis of the results of CT-guided needle biopsy.

At surgery, a fleshy, somewhat hemorrhagic-appearing tumor was found approximately 1 cm below the surface of the skin. The coccygeal fascia did not appear to be involved, and a clear plane was developed along the coccygeal fascia to the tip of the coccyx itself. The mass was removed in its entirety. The lateral margin of the coccyx appeared to have been somewhat eroded although not di-

rectly involved. Histologic examination of the biopsy specimen confirmed the diagnosis of myxopapillary ependymoma.

Discussion

Fifty to sixty percent of tumors of the spinal cord of glial origin are ependymomas; the remaining are mostly astrocytomas, usually of low grade [1]. According to Kernohan et al. [1] ependymomas account for 50% of neoplasms of the filum terminale, when they are of the papillary or myxopapillary type. Ependymomas outside the CNS are rare [2]. Such tumors are (1) metastases or direct extension from CNS primary tumors after surgical excision [3]; (2) direct extension to the soft tissues of the sacrococcygeal area from a primary ependymoma of the lower spinal cord, cauda equina, or filum terminale [4]; (3) primary presacral tumors [5]; and (4) primary tumors of the skin and subcutaneous tissue of the sacrococcygeal area without connection to the spinal cord [2, 3]. Subcutaneous ependymomas are rare. Only 40 cases have been reported in the world's literature since the original description by Mallory in 1902 [6].

The origin of sacrococcygeal myxopapillary ependymoma of the skin and subcutaneous tissue has not been clarified fully. The source of ependymal cells in the postsacral region has been attributed to embryologic rests located within this region. It is thought that tumors in this area arise from extradural remnants of the filum terminale [1]. The tail in human embryos during the sixth gestational week contains an irregular section of neural tissue. By this time, the tail has reached its maximal length. Subsequently, both the tail and its contained neural tube undergo regressive changes and disappear [7]. However, a remnant of the caudal portion of the neural tube remains beneath the skin over the end of the coccyx as an ependyma-lined cavity, known as the coccygeal medullary vestige. It is thought that the coccygeal medullary vestige is the source of ependymal cells that later can lead to the development of an ependymal neoplasm. Neoplastic development from these rests is slow; the mean age at presentation is 17 years (range, 10 months–47 years). Both sexes are affected equally [2, 4].

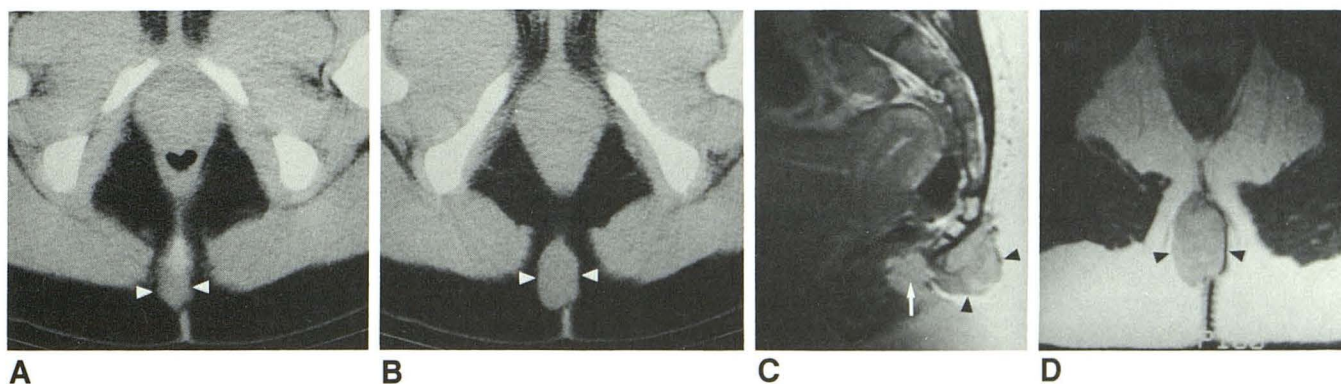


Fig. 1.—Subcutaneous sacrococcygeal myxopapillary ependymoma.

A and B, Axial CT scans at level of coccyx (A) and 3 cm below it (B) show a midline lesion 3 × 4 cm (arrowheads) immediately deep to natal cleft. Lesion is in contact with dorsal surface of coccyx without evidence of bone erosion.

C and D, Contrast-enhanced sagittal (C) and axial (D) T1-weighted, 700/20/2, MR images show a sharply defined mass (arrowheads) in contact with dorsal surface of distal coccyx. Heterogeneous, enhancing mass (arrowheads) is hyperintense relative to muscle. Tissue immediately in front of tumor (arrow) is normal fat. High signal in marrow space of distal coccygeal segments is due to fatty tissue and not enhancement.

These extraspinal ependymomas occur in two characteristic locations: the intergluteal fold overlying the sacrum and coccyx (pilonidal area) or the pelvis anterior to the sacrum in the retrorectal space [5]. Those dorsal to the sacrum are the more common group in terms of soft-tissue tumors [8]. Characteristically, the tumor presents as a long-standing, asymptomatic mass in the intergluteal fold. In some patients, ependymomas occasionally can cause pain or discomfort on sitting. Physical examination is usually normal except for the presence of a palpable soft-tissue mass. The differential diagnosis includes pilonidal cyst or sinus, meningocele or myelomeningocele, teratoma, lipoma, sweat gland tumor, and lesions related to trauma [2, 4, 5, 8]. The diagnosis of subcutaneous sacrococcygeal myxopapillary ependymoma is not made clinically. At surgery, the tumor usually is a well-defined lobulated mass, and total local excision frequently can be performed [2, 4, 5]. When the lesion cannot be removed completely, adjunctive postoperative radiation therapy is administered. Metastases occur in 20% of cases over 5–15 years after diagnosis [2]. Unfortunately, no clinical or histologic indicators of metastatic potential are known [2].

Romeu C. Domingues
David Mikulis

Brooke Swearingen

Ronald Tompkins

Bruce R. Rosen

Massachusetts General Hospital
Boston, MA 02114

REFERENCES

1. Kernohan JW, Fletcher-Kernohan EM. Ependymomas: a study of 109 cases. *Assoc Res Nerv Ment Dis* **1935**;16:182–209
2. Helwig EB, Stern JB. Subcutaneous sacrococcygeal myxopapillary ependymoma: a clinicopathologic study of 32 cases. *Am J Clin Pathol* **1984**;81:156–161
3. Wolff M, Santiago H, Duby MM. Delayed distant metastasis from a subcutaneous sacrococcygeal ependymoma: case report, with tissue culture ultrastructural observations, and review of the literature. *Cancer* **1972**;30:1046–1067
4. Anderson MS. Myxopapillary ependymomas presenting in the soft tissue over the sacrococcygeal region. *Cancer* **1966**;19:585–590
5. Morantz RA, Kepes JJ, Batnitzky S, Masterson BJ. Extraspinal ependymomas. *J Neurosurg* **1979**;51:383–391
6. Mallory FB. Three gliomata of ependymal origin: two in the fourth ventricle, one subcutaneous over the coccyx. *J Med Res* **1902**;8:1–10
7. Willis RA. *The borderland of embryology and pathology*, 2nd ed. London: Butterworths, **1952**
8. Enzinger FM, Weiss SW. *Soft tissue tumors*, 2nd ed. St. Louis: Mosby, **1988**:810–813