



Discover Generics

Cost-Effective CT & MRI Contrast Agents



WATCH VIDEO

AJNR

Technical note: radiolucent operating room table extension to facilitate intraoperative angiography.

S T Hecht, S S Kemp and C W Kerber

AJNR Am J Neuroradiol 1991, 12 (1) 130

<http://www.ajnr.org/content/12/1/130.citation>

This information is current as
of June 18, 2025.

Technical Note: Radiolucent Operating Room Table Extension to Facilitate Intraoperative Angiography

Stephen T. Hecht,¹⁻³ Susan S. Kemp,¹ and Charles W. Kerber⁴

Recent improvements in digital C-arm radiographic units permit the safe and effective performance of cerebral angiography in the operating room. Intraoperative cerebral angiography, in turn, facilitates more effective aneurysm surgery and arteriovenous malformation therapy [1, 2]. A variety of radiolucent carbon fiber head holders are now available for use in neurosurgical procedures that involve angiography. Radiolucent operating room tables, suitable for angiography, are also now commercially available. Most operating room tables currently in active use, however, have been designed without consideration of possible use as angiography tables. Radiographic visualization of the aortic arch is essential for the performance of cerebral angiography, and radiopaque tables obscure this structure. During angiography on radiopaque tables, the aortic arch can often be visualized by proper angulation of the C-arm unit, although the resulting projections are disorienting.

Frontal viewing of the aortic arch is made possible with any operating room table by the addition of a durable, weight-bearing, radiolucent table extension that can be easily and inexpensively fabricated. The patient's chest is supported by the radiolucent extension, which projects over the edge of the radiopaque table. At present, there are no commercially available radiolucent table extensions to adapt radiopaque operating room tables for cerebral angiography.

The extension can be made from 1/4-in. carbon fiber sheeting, 5/8-in. Plexiglas, or 3/4-in. plywood. A 2 × 5 ft sheet of the radiolucent material (carbon fiber, Plexiglas, or plywood) is placed on the operating room table with approximately 20–25 cm projecting off the head end (Fig. 1). A soft pad is placed over the sheet of radiolucent material, which is then held in place by the weight of the patient. Prior to attaching the head holder, test the system by pressing on the head end of the board to be certain it is stable. To avoid unintended motion, the extension board is taped to the operating room table. The

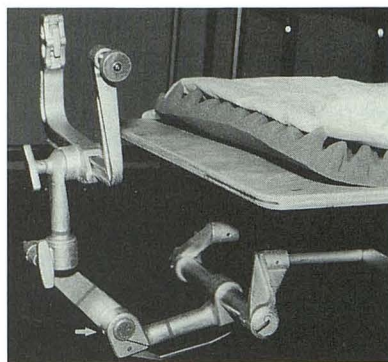


Fig. 1.—Three-quarter-in. plywood board on operating room table. Board is covered by foam rubber pad. Head holder is attached to operating room table. Note that elbow joint of head holder (arrow) is in an extended position, allowing increased clearance for C-arm.

head holder (in an extended position) is attached to the operating room table, and the patient is then positioned in the usual fashion. The 20–25 cm projection of the patient over the end of the table is enough to allow visualization of the aortic arch in the anteroposterior projection, thereby improving the ease and speed of catheterization of the arch vessels.

The extension board confers another, more important, benefit to the angiographer. All neurosurgical head holders contain an elbow joint (Fig. 1, arrow). The elbow joint is usually flexed (i.e., it points toward the floor and thus obstructs movement of the C-arm). Extending the patient cranially allows the elbow joint to extend, allowing an additional 7–15 cm of clearance for the C-arm components.

REFERENCES

1. Kerber CW, Alksne JF, Hesselink JR, et al. Intraoperative neuroangiography with digital subtraction and roadmapping: technique and cost effectiveness. *Neurosurgery* 1990;73:526–533
2. Martin NA, Bentson J, Viñuela F, et al. Intraoperative digital subtraction angiography in the surgical treatment of intracranial aneurysms and vascular malformations. *J Neurosurg* (in press)

The reader's attention is directed to the commentary on this article, which appears on pages 133–134.

Received May 21, 1990; revision requested July 19, 1990; revision received August 2, 1990; accepted August 6, 1990.

¹ Department of Radiology, University of Pittsburgh, Presbyterian-University Hospital, Pittsburgh, PA 15213.

² Department of Neurological Surgery, University of Pittsburgh, Presbyterian-University Hospital, Pittsburgh, PA 15213.

³ Present address: Departments of Radiology and Neurological Surgery, University of California, Davis Medical Center, 2516 Stockton Blvd., Sacramento, CA 95617. Address reprint requests to S. T. Hecht.

⁴ Departments of Radiology and Neurological Surgery, UCSD Medical Center, San Diego, CA 92103.

Books Received

Receipt of books is acknowledged as a courtesy to the sender. Books considered to be of sufficient interest will be reviewed as space permits.

Therapeutic Endoscopy and Radiology of the Gut. Edited by John R. Bennett and Richard H. Hunt. Baltimore: Williams & Wilkins, 386 pp., 1990. \$120

Radiology of the Eye and Orbit. (Vol. 4 in Modern Neuroradiology.) Edited by Thomas H. Newton and Larissa T. Bilaniuk. New York: Raven, 311 pp., 1990. \$115

Neural Monitoring. The Prevention of Intraoperative Injury. Edited by Steven K. Salzman. Clifton, NJ: Humana, 336 pp., 1990. \$69.50

Envisioning Information. By Edward R. Tufte. Cheshire, CT: Graphics Press, 126 pp., 1990. \$48

Magnetic Resonance Imaging and Computed Tomography of the Head and Spine. By C. Barrie Grossman. Baltimore: Williams & Wilkins, 465 pp., 1990. \$125

Textbook of Uroradiology. By N. Reed Dunnick, Ronald W. McCallum and Carl M. Sandler. Baltimore: Williams & Wilkins, 505 pp., 1991. \$125

Erratum

In the technical note "Radiolucent Operating Room Table Extension to Facilitate Intraoperative Angiography" by Stephen T. Hecht, Susan S. Kemp, and Charles W. Kerber (*AJNR* 1991; 12:130), publication information regarding the two references was inadvertently transposed. The first article is still in press and the second article was published as follows: *J Neurosurg* 1990; 73:526-533. *AJNR* apologizes for this error.