



Providing Choice & Value
Generic CT and MRI Contrast Agents

**FRESENIUS
KABI**

CONTACT REP

AJNR

**Brain damage from perinatal asphyxia:
correlation of MR findings with gestational age.**

A J Barkovich and C L Truwit

AJNR Am J Neuroradiol 1990, 11 (6) 1087-1096

<http://www.ajnr.org/content/11/6/1087>

This information is current as
of July 29, 2025.

Brain Damage from Perinatal Asphyxia: Correlation of MR Findings with Gestational Age

A. James Barkovich¹
Charles L. Truwit

MR scans of 25 patients who suffered asphyxia at known gestational ages were reviewed retrospectively. The gestational ages of the patients at the time of the asphyxia ranged from 24 to 46 weeks. The MR pattern of brain damage in patients with prolonged partial asphyxia was seen to evolve in a predictable manner corresponding to the known maturation of the brain and its vascular supply. Patients at 24- and 26-weeks gestational age had irregularly enlarged ventricular trigones with minimal periventricular gliosis. Patients at 28-34 weeks had variably dilated ventricles with periventricular gliosis. The 36-week neonate had mild cortical and subcortical atrophy and gliosis superimposed on deep white matter and periventricular gliosis. Term neonates had significant cortical and subcortical gliosis and atrophy in the parasagittal watershed areas. Postterm neonates (44-46 weeks) showed cortical and subcortical watershed gliosis and atrophy with sparing of the immediate periventricular region. Two children suffered cardiocirculatory arrest; their scans revealed a different pattern of brain damage, demonstrating primarily brainstem, thalamic, and basal ganglia involvement.

MR appears to be a powerful tool in the assessment of brain damage resulting from perinatal asphyxia that gives important clues to the time and nature of the asphyxia.

AJNR 11:1087-1096, November/December 1990

The introduction of MR imaging as a diagnostic study has had an enormous impact on pediatric neuroradiology. Subtle structural abnormalities that heretofore could be detected only in surgical or autopsy suites are now detected routinely with MR [1, 2]. In addition to its superb anatomic resolution, MR is very sensitive to structural brain damage as a result of its high sensitivity to differing amounts of free water in the brain [3-5].

It is known that the response of the brain to injury changes as it matures in utero [6, 7]. For example, ischemic damage to the first-trimester brain results in congenital malformations, whereas a similar insult to the early third-trimester brain results in periventricular leukomalacia [6]. Since the timing of injury often has profound implications, we postulated that MR may be able to detect subtle differences in the pattern of asphyxic damage suffered at different gestational ages. This article reports the MR findings in a series of patients who suffered asphyxia at a known time between 24 and 46 gestational weeks.

Materials and Methods

MR scans from 25 patients with documented asphyxia at known gestational ages were reviewed retrospectively. The patients varied from 24- to 46-weeks gestational age at the time of asphyxia (mean, 35 weeks; median, 33 weeks, Table 1). Fifteen patients were born prematurely, seven at term, and three were postmature. The age of the patients at the time of the MR examination varied from 2 weeks to 19 years (mean, 5.4 years; median, 2.3 years). The mothers in all cases were healthy and the pregnancies uneventful until delivery, except for one case of well-documented peritoneal hemorrhage in the mother at 30 weeks. Twelve

Received December 27, 1989; revision requested April 16, 1990; revision received May 9, 1990; accepted June 1, 1990.

¹ Both authors: Department of Radiology, Box 0628, Neuroradiology Section, L371, University of California, San Francisco, 505 Parnassus Ave., San Francisco, CA 94143. Address reprint requests to A. J. Barkovich.

0195-6108/90/1106-1087
© American Society of Neuroradiology

TABLE 1: MR Findings After Perinatal Asphyxia

Case No.	Age at Asphyxia (wk)	Age at Scan	Basal Ganglia	Cerebral Cortex	Corpus Callosum	White Matter	Posterior Fossa	Myelination	Ventricles
1	24	2½ yr	Normal	Normal	Thin splenium	Diminished peritrigonally	Normal	Normal	Large, irregular trigones
2	26	10 yr	Normal	Normal	Very thin, especially POST	Diffusely diminished	Normal	Normal	Large, irregular body & trigones
3	28	9 mo	Normal	Normal	Very thin diffusely	Diminished; ↑ T2	Normal	Normal	Large, irregular
4	28	5 yr	Normal	Normal	Thin POST body & splenium	Diminished; ↑ T2 in POST body & trigones	Normal	Normal	Large, irregular body & trigones
5	28	10 yr	Normal	Normal	Very thin diffusely	Markedly diminished; slightly ↑ T2	Thin brain stem	Normal	Irregular, diffusely
6	29	9 yr	Normal	Normal	Thin POST body	Diminished; ↑ T2 peritrigonally	Normal	Normal	Slightly irregular; large trigones
7	30	2½ yr	Normal	Normal	Thin POST body & splenium	Diminished; ↑ T1 & T2 peritrigonally	Normal	Normal	Irregular; large trigones
8	30	12 mo	Normal	Normal	Diffusely thin	Diminished; ↑ T2 perifrontally & trigonally	Normal	Delayed	Irregular trigones
9	32	9 yr	Normal	Normal	Thin POST body & splenium	Diminished, ↑ T1, T2 peria-tri-ally & POST body	Normal	Normal	Large, irregular trigones
10	32	24 mo	Normal	Normal	Thin POST body & splenium	Diminished; ↑ T1, T2 peria-tri-ally & POST body	Normal	Normal	Large, irregular trigones
11	33	2½ yr	Normal	Normal	Thin POST body & splenium	Diminished; ↑ T2 peria-tri-ally & body	Normal	Normal	Large, irregular trigones
12	34	20 mo	Normal	Normal	Thin POST body & splenium	Diminished; ↑ T2 peria-tri-ally & body	Normal	Normal	Irregular body & trigone walls
13	34	16 mo	Normal	Normal	Thin POST body & splenium	Diminished; ↑ T1, T2 peria-tri-ally & POST body	Normal	Normal	Normal; irregular R trigone
14	34	3 yr	Small thalami	Normal	Diffusely thin	Diffusely diminished; diffusely ↑ T1, T2	Normal	Normal	Large, irregular diffusely
15	36	14½ yr	Normal	Slight thinning of watershed	Thin, especially body	Diffusely thin; ↑ T2 perifrontally, peria-tri-ally, & subcortical watershed	Normal	Normal	Normal
16	Term	3 wk	Foci of ↓ T1, ↓ T2; small thalami	Normal	Slightly thin POST body	Diminished, L > R	Small dorsal midbrain	Delayed	Smooth ↑ on L; third slightly large
17	Term	2 wk	Negligible	Normal	Negligible	↑ T1 in subcortical watershed	Negligible	Normal	Normal
18	Term	1 mo	Foci of ↓ T1, ↓ T2, ↑ T2	Negligible	Negligible	Negligible	Negligible	Delayed	Normal
18	Term	16 mo	Normal signal; small lentiform nuclei	Negligible	Diffusely thin	Diminished; foci of ↑ T2	Negligible	Delayed	Smooth, ex vacuo enlargement
19	Term	2 mo	Foci of ↓ T1, ↓ T2	Thin in ANT & POST watershed	Diffusely thin	Diminished; ↑ T2 diffusely	Thin pons	Delayed	Smooth, slightly large
20	Term	4 yr	↑ T2; focal ↓ T2 on L	Thin in ANT & POST watershed, L >> R	Thin POST body & splenium	Diminished; ↑ T2 L > R	Normal	Normal on R; delayed on L	Smooth, ex vacuo enlargement

Table 1 continues

Table 1—Continued

Case No.	Age at Asphyxia (wk)	Age at Scan	Basal Ganglia	Cerebral Cortex	Corpus Callosum	White Matter	Posterior Fossa	Myelination	Ventricles
21	Term	4 yr	↓ T2	Very thin in ANT & POST watersheds	Diffusely thin	Diminished in watersheds; ↑ T1, T2 diffusely	Normal	Delayed	Smooth, ex vacuo dilatation
22	Term	5 yr	Focus of ↑ T2 in L caudate	Thin in ANT POST watersheds	Thin POST body & splenium	Diminished, ↑ T1, T2 in watersheds, ventricle to cortex	Normal	Normal	Smooth ex vacuo, especially trigones, L > R
23	44	18 yr	Normal	Thin in ANT & POST watersheds	Thin POST body & splenium	Diminished; ↑ T2, especially in watersheds	Normal	Normal	Smooth, ex vacuo dilatation
24	44	19 yr	↓ T2	Very thin in ANT & POST watersheds	Diffusely thin	Markedly diminished; ↑ T2 in watersheds	Normal	Normal	Smooth, ex vacuo, especially trigones
25	46	9 mo	↓ T2	Very thin in ANT & POST watersheds	Diffusely thin	↑ T1 & T2 in subcortical watersheds	Normal	Delayed	Smooth, ex vacuo dilatation

Note.—“Watershed” refers to mature watershed regions. POST = posterior; ANT = anterior; R = right; L = left; ↑ = prolonged T1 or T2 relaxation time; ↓ = shortened T1 or T2 relaxation time.

patients had complicated vaginal deliveries with intrapartum asphyxia that was believed to be the cause of the brain damage. Eleven had episodes of hypoxia/ischemia after birth related to hyaline membrane disease (seven), meconium aspiration (one), neonatal pneumonia (two), or unknown causes (one). One infant suffered asphyxia from suffocation and one from hypotension secondary to the retroperitoneal hemorrhage described above. All patients were clearly hypoxic for periods ranging from 5 to 20 min. Two patients (cases 16 and 17) suffered complete cardiocirculatory arrest for periods of 8–10 min. Fifteen patients were classified as having spastic diplegia, five had spastic diplegia and cortical blindness, two were hypotonic, and three had spastic quadriplegia. Twenty-two patients were imaged in the chronic phase, months to years after the asphyxia. Cases 16–18, however, were imaged subacutely, at 3, 2, and 4 weeks, respectively, after their episodes. One of these (case 18) was imaged again 16 months after asphyxia. Three patients were severely mentally retarded (intelligence quotient less than 50); seven others were developmentally delayed.

Nineteen scans were obtained with superconducting magnets operating at 1.5 T. Five-millimeter sagittal spin-echo (SE) 600–700/20/2 (TR/TE/excitations) and axial 5-mm SE 2500–3000/30–60, 70–120 images were obtained in all patients imaged at 1.5 T. Ten patients were also imaged in the axial plane with an SE 600/20 sequence and five patients had coronal SE 2500–3000/30–60, 70–100 sequences. The remaining patients were scanned at 0.35 T (two), 0.5 T (two), and 0.6 T (one) using sagittal SE 500–733/30–40 and axial SE 2000–2500/40, 80–100 sequences.

The images were assessed for tissue loss and evidence of tissue damage (“gliosis”) as demonstrated by areas of prolonged T1 and/or T2 relaxation. In particular, the corpus callosum, periventricular and subcortical white matter, cerebral cortex, basal ganglia, thalami, and brainstem were scrutinized. The white matter was, furthermore, examined for evidence of delayed or accelerated myelination. The

contour of the ventricles was examined for irregularity that might suggest incorporation of periventricular cavities. Finally, the cerebellum and brainstem were evaluated for evidence of associated damage.

Results

Patient data, including age at the time of asphyxia, age at the time of the MR, and MR findings, are summarized in Table 1. Two patients (cases 1 and 2), who were born at 24 and 26 weeks, had similar patterns of brain damage. Both had dilated trigones and occipital horns of the lateral ventricles with scalloped, irregular ventricular walls (Fig. 1). The periventricular white matter was diminished, evidenced by close approximation of the posterior temporal and occipital cortex to the ventricular wall and by thinning of the posterior body and splenium of the corpus callosum. The signal intensity of the remaining white matter was normal. The cerebral cortex, basal ganglia, posterior fossa, and myelination patterns were normal.

Twelve neonates (cases 3–14), born at 28–34 gestational weeks, had similar thinning of the posterior periventricular white matter. In addition, however, these patients had an irregular stripe of prolonged T2 relaxation surrounding the lateral ventricles in the region of the tissue loss (Fig. 2); it was most common in the peritrigonal region, often with extension posteriorly along the occipital horn and anteriorly along the ventricular body. In all age groups, the thickness of this band of prolonged T2 relaxation was to some degree dependent on how much tissue was remaining between the ventricle and

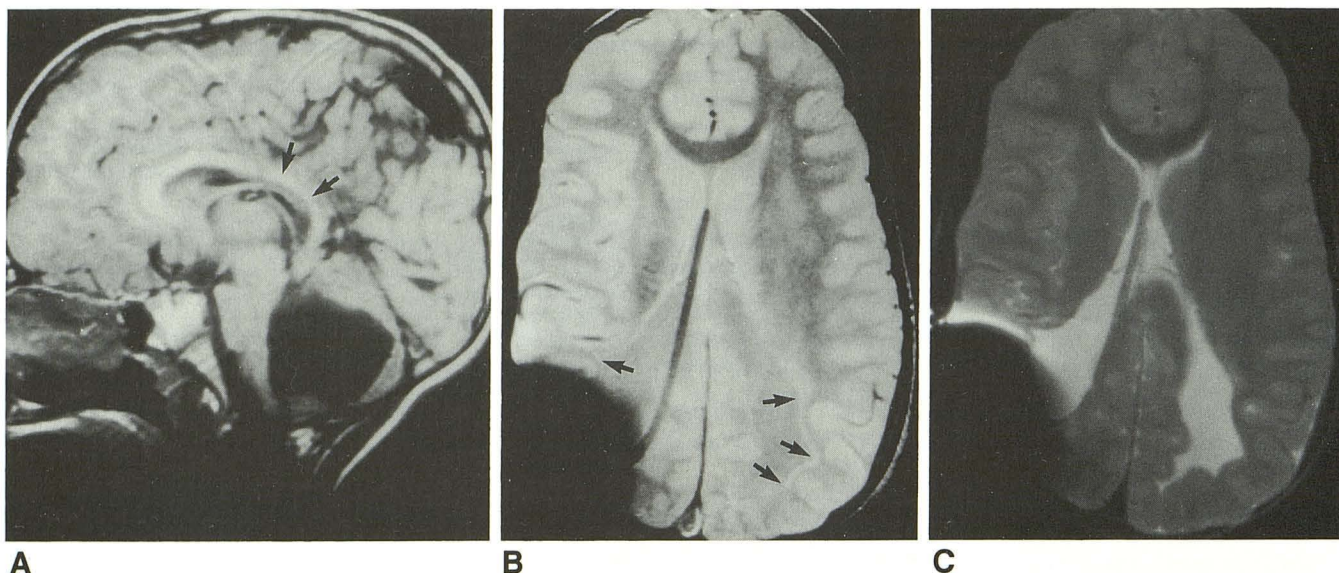


Fig. 1.—Case 1: Partial asphyxia at 24 weeks; scan at 2½ years.

A, Sagittal SE 600/20 image shows thinning of posterior body and splenium of corpus callosum (arrows). Posterior fossa CSF collection is an isolated fourth ventricle as a result of previous intraventricular hemorrhage.

B, Axial SE 2500/30 image shows ventriculostomy tube entering from right occipital area with its tip near foramen of Monro. Trigones of lateral ventricles are irregularly dilated (arrows). Minimal amount of periventricular high signal is significantly less than was seen when asphyxia occurred at 28 weeks or later. Cerebral cortex nearly apposes ventricular wall in several areas, indicative of loss of a large amount of periventricular white matter. This finding is classic for periventricular leukomalacia. Signal dropout in right occipital region is caused by metallic shunt component.

C, SE 2500/80 image. Ventricle and periventricular gliosis are isointense. Therefore, long TR/short TE sequence is necessary to separate gliosis from ventricle.

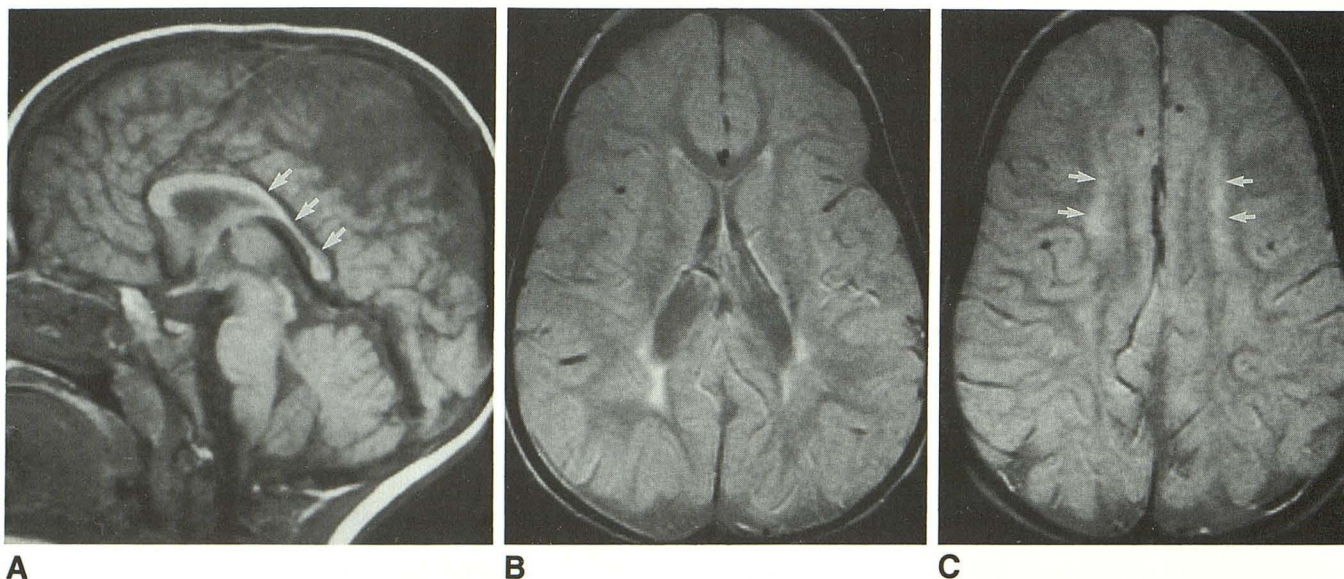


Fig. 2.—Case 12: Partial asphyxia at 34 weeks; scan at 20 months.

A, Sagittal SE 600/20 image shows abnormal thinning of posterior body and anterior splenium of corpus callosum (arrows).

B, Axial SE 2500/30 image shows loss of periventricular white matter in trigonal region. Note how posterior sylvian cortex nearly apposes ventricular wall bilaterally. Immediately peritrigonal white matter shows prolonged T2 relaxation.

C, Axial SE 2500/30 image shows prolonged T2 relaxation extending anteriorly along periventricular white matter (arrows) but sparing subcortical white matter and cortex.

the cortex. In those regions with a large amount of white matter loss, the band of high intensity was necessarily thinner than in those where the periventricular white matter layer was thicker. In cases 3 and 8, this stripe of increased T2 relaxation

extended anteriorly to the frontal horns. The basal ganglia, posterior fossa, and myelination were normal except for a small brainstem in case 5, probably resulting from wallerian degeneration of descending cortical tracts. Thinning of the

corpus callosum (Fig. 2) reflected hemispheric white matter loss. The white matter around the trigones, occipital horns, and posterior bodies of the lateral ventricles was primarily involved; the cortex and subcortical white matter were spared.

In case 15, intrapartum asphyxia suffered during delivery at 36-weeks gestational age resulted in marked diminution of white matter in the cerebral hemispheres diffusely. Prolonged T2 relaxation time was seen in the periventricular white matter, particularly around the trigones, occipital horns, and frontal horns. High intensity was also present in the subcortical white matter in the parasagittal watershed regions (Fig. 3), between the middle cerebral artery and the anterior cerebral artery (anteriorly), and between the middle cerebral artery and posterior cerebral artery (posteriorly). The basal ganglia, posterior fossa, and myelination were unremarkable. The corpus callosum was diffusely thin.

Seven patients (cases 16–22) were term infants who suffered asphyxia at some time between 38 and 42 gestational weeks. Cases 16–18 were studied subacutely, 3, 2, and 4 weeks, respectively, after the asphyxic episodes. In two patients (cases 16 and 18) who suffered complete circulatory arrest, foci of markedly shortened T1 relaxation and mildly shortened T2 relaxation were seen in the posterior limb of the internal capsule and lateral thalamus (Figs. 4A–4C). The mid-brain was markedly diminished in size in case 16. Myelination was delayed in both. A follow-up scan in case 18, obtained at age 16 months, showed diffusely diminished hemispheric white matter with foci of prolonged T2 relaxation and delayed myelination (appropriate for an 11-month-old) (Figs. 4D–4F). The corpus callosum was diffusely thin. The lentiform nuclei were diminished in size and displayed prolonged T2 relaxation. Case 17 showed prolonged T1 relaxation in the parasagittal areas, posteriorly more than anteriorly, and right hemisphere greater than left. Long TR/TE images obscured the white matter abnormalities. The brainstem, cerebellum, myelination, and corpus callosum were unremarkable.

Cases 19–22 were imaged between 2 months and 5 years after the asphyxic episode. In these patients, prolonged T1 and T2 relaxation times were seen in the cerebral hemispheric white matter from the periventricular region to the cortex. The

white matter was also diminished in quantity. The watershed areas between the major vascular territories were affected most severely. The cortex was severely thinned, most prominently in the watershed areas as well (Fig. 5). Three patients (cases 19–21) had abnormalities in the basal ganglia, consisting of shortened T1 and T2 relaxation times (Fig. 6). The corpus callosum was thin and the lateral ventricles enlarged in these patients, most likely as a result of white matter degeneration. The walls of the ventricles were smooth. Myelination was diminished.

Three patients (cases 23–25) suffered asphyxic injury at 44- to 46-weeks gestational age. One was born with a degenerated placenta and umbilical cord after a prolonged labor with 50 min of deceleration. The other two suffered postnatal asphyxia. These patients all had diminution in the amount of the cerebral hemispheric white matter with prolonged T1 and T2 relaxation times in the cortex and subcortical white matter. Interestingly, the immediate periventricular white matter showed a normal signal intensity and, therefore, was considered relatively spared (Fig. 7). The cortex was thin and shrunken; both the cortical and white matter abnormalities were more severe in the watershed regions. Images in case 24 showed linear strands of high intensity (Fig. 7) suggestive of glial strands and multicystic encephalomalacia. The ventricles, particularly the frontal and occipital horns, showed smooth, ex vacuo dilatation. The corpus callosum was diffusely thinned. The basal ganglia showed diminished T2 relaxation time in two of the three patients. Myelination was diminished in one. The posterior fossa and brainstem were normal in all three.

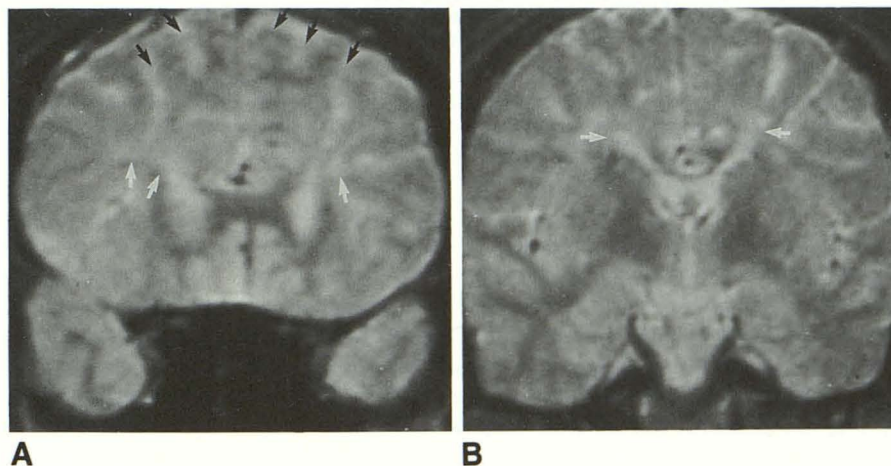
Discussion

Although asphyxia is an important cause of neurologic damage in the peri- and neonatal periods, the clinical examination in these patients is often nonspecific [8]. Furthermore, the prognosis is uncertain; 60% of premature infants with hypoxic-ischemic encephalopathy die, 13% survive with significant neurologic deficit, and 27% develop normally [8]. Term infants with hypoxic-ischemic encephalopathy have a better, but still uncertain, prognosis: 11% die, 25% survive with

Fig. 3.—Case 15: Partial asphyxia at 36 weeks; scan at 14½ years.

A, Coronal SE 2800/70 image shows mild periventricular T2 prolongation (white arrows). There is also some subcortical T2 prolongation and prominence of gyri in parasagittal watershed region (black arrows).

B, Coronal SE 2800/70 image at level of foramina of Monro also shows sulcal prominence in parasagittal regions, with abnormal periventricular white matter immediately adjacent to ventricles (arrows).



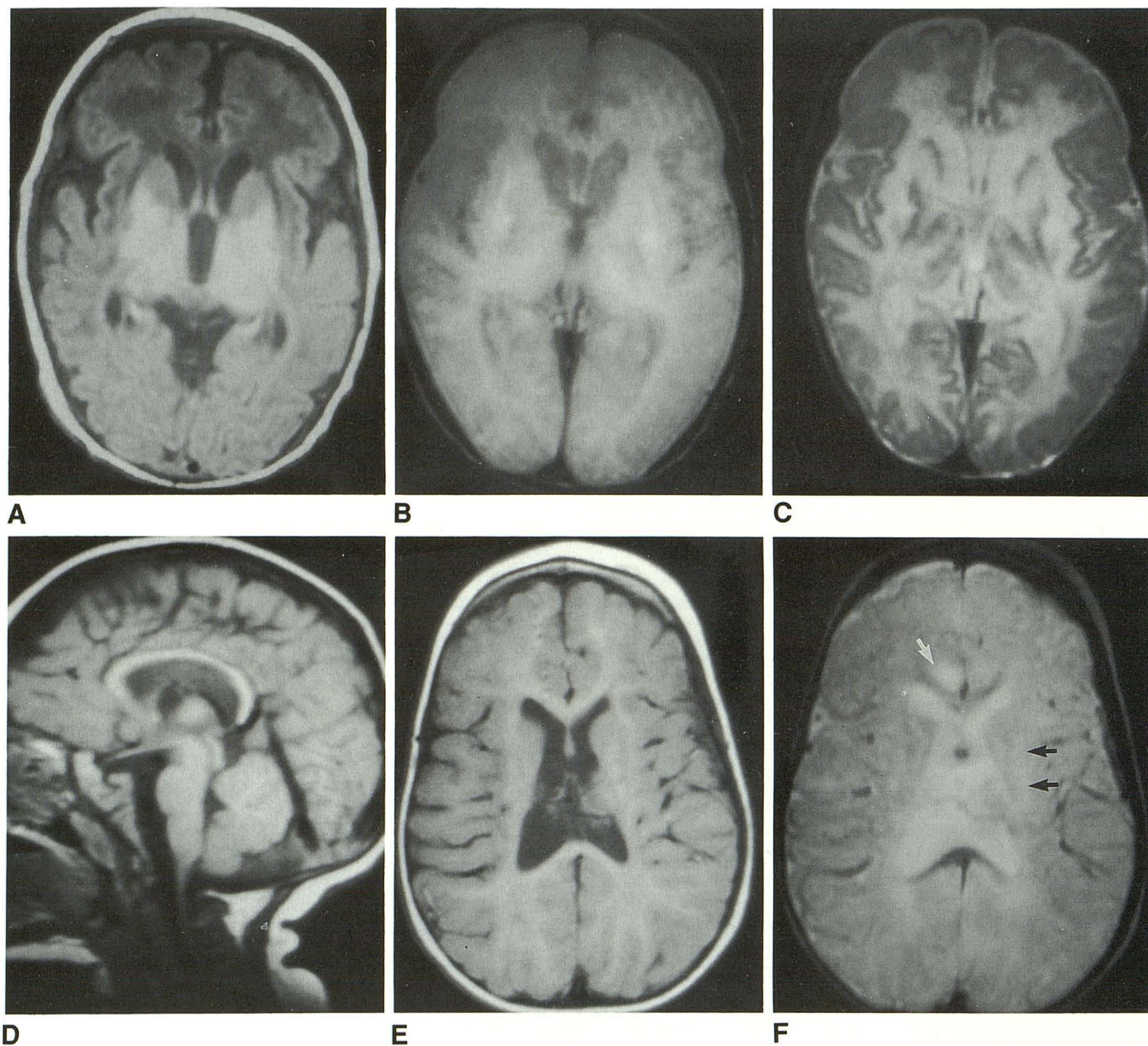


Fig. 4.—Case 18: Anoxia at term.

A–C, Scans at 1 month of age.

A, Axial SE 600/20 image shows large third ventricle and markedly shortened T1 in posterior lentiform nuclei and thalami.

B and C, Axial SE 3000/60, 120 images show foci of short and long T2 in affected deep gray matter nuclei. Normal focus of myelination in posterior limb of internal capsule is missing, indicating delayed myelination.

D–F, At 16 months of age.

D, Sagittal SE 600/20 image shows diffusely diminished size of corpus callosum.

E, Axial SE 600/20 image shows diminished size of lentiform nuclei and diminished amount of cerebral white matter diffusely. Despite prominent sulci, cerebral cortex has a relatively normal thickness, and, in particular, intervascular boundary zones (watershed areas) are spared.

F, Axial SE 2500/80 image shows diminished myelination, prolonged T2 relaxation in basal ganglia (black arrows), and focus of prolonged T2 relaxation in hemispheric white matter (white arrow).

neurologic deficits, and 64% develop normally [8]. CT has been considered a useful tool in assessing the amount of brain damage, which seems to correlate with the degree of neurologic deficit [9–14]. However, CT often underestimates the amount of damage present in the brain [10, 15, 16]. MR has recently been used in some centers to assess brain damage in perinatal and neonatal asphyxia because of its

apparent increased sensitivity to structural damage [3–5, 17]. Moreover, MR studies have shown that myelination, a process that cannot be detected by CT, is delayed in patients who suffer perinatal asphyxia [4, 18].

Our results indicate that the pattern of structural damage in asphyxiated premature neonates is clearly different than that in asphyxiated term neonates. Neonates with asphyxia

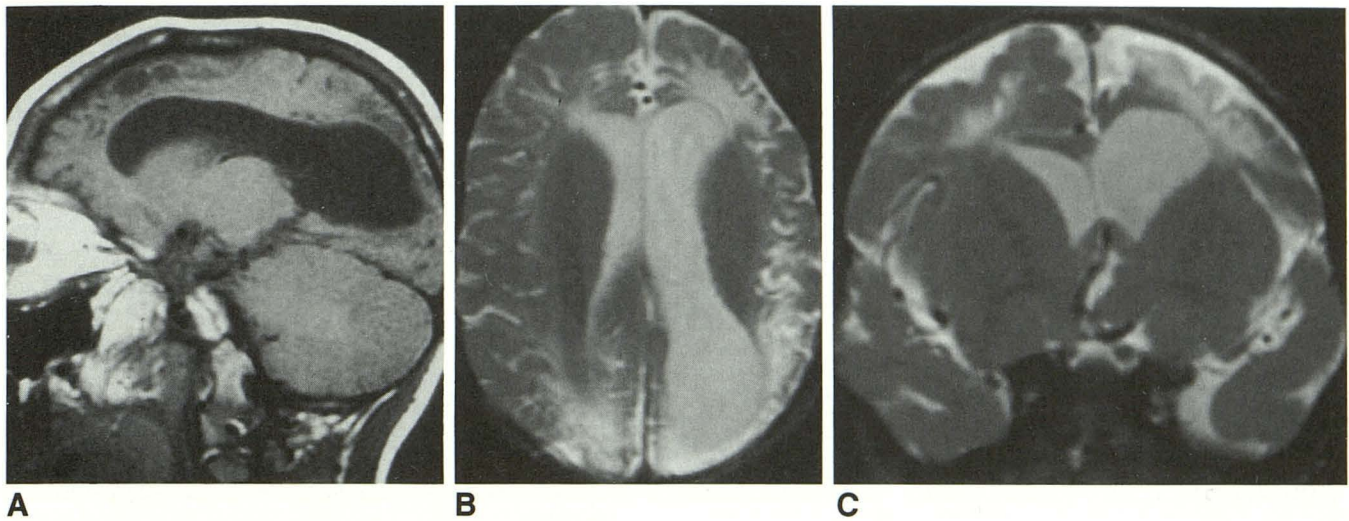


Fig. 5.—Case 22: Partial asphyxia at term; scan at 5 years.
A, Parasagittal SE 600/20 image shows ex vacuo enlargement of left lateral ventricle, cortical thinning, and prolonged T1 of subcortical white matter.
B, Axial SE 2800/80 image shows cortical thinning and prolonged T2 relaxation time of periventricular, deep, and subcortical white matter in mature watershed zones. Left hemisphere is affected more severely.
C, Coronal SE 2800/80 image confirms predominantly parasagittal location of damage.

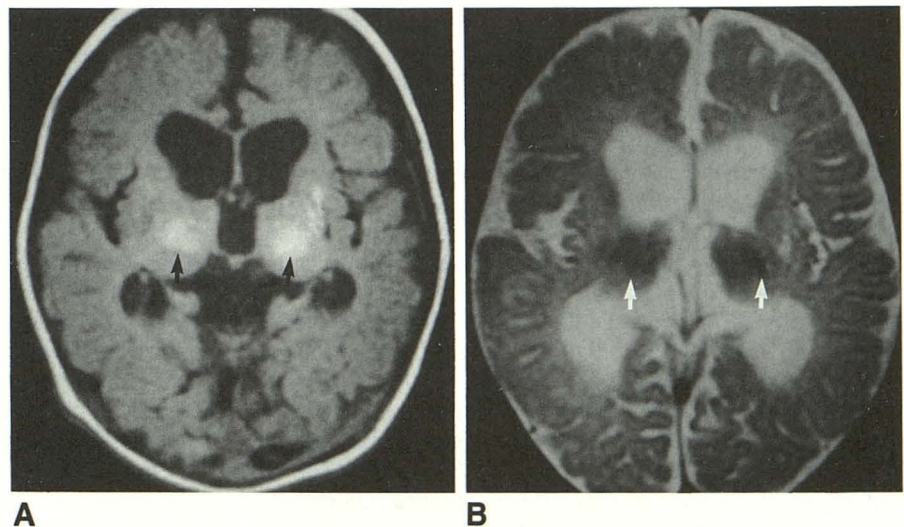


Fig. 6.—Case 19: Partial asphyxia at term; scan at 2 months.
A, Axial SE 700/20 image shows abnormal foci of shortened T1 relaxation (arrows) in thalami and lentiform nuclei. Ventricles are enlarged.
B, Axial SE 3000/70 image shows shortened T2 relaxation time in thalami and lentiform nuclei (arrows).

at 24- to 26-weeks gestational age showed a pattern of localized ventricular enlargement with irregular ventricular margins, presumably secondary to incorporation of periventricular cavities into the ventricle [12]. There was minimal prolongation of T2 relaxation time in the surrounding white matter, suggesting absent or minimal gliosis. As the gestational age at the time of the asphyxia increased, a rim of prolonged T2 relaxation around the ventricular atria developed and grew thicker. In some patients 30- to 34-weeks gestational age, a rim of gliosis up to 1 cm thick was present; however, the cortex and subcortical white matter remained spared. In the 36-week gestational age neonate, minimal involvement of the subcortical white matter was seen, manifest as prolonged T2 relaxation time in the subcortical white matter in the parasagittal watershed areas. In episodes at

term, marked diminution and prolonged T2 relaxation of the hemispheric white matter, both subcortical and deep, was seen, as well as a shrunken, thinned cerebral cortex. These findings were most prominent in the parasagittal watershed regions. Finally, in the postterm neonates, the cortex and subcortical white matter in the watershed regions were most severely involved, with relative sparing of the immediately periventricular white matter.

The observed evolution of the pattern of brain damage as the gestational age increases supports the findings of De-Reuck et al. [19, 20] and of Takashima and Tanaka [21]. These investigators have shown that premature neonates have not yet developed ventriculofugal arteries to the periventricular white matter (ventriculofugal arteries are those that course peripherally from the ventricular wall). Therefore, the

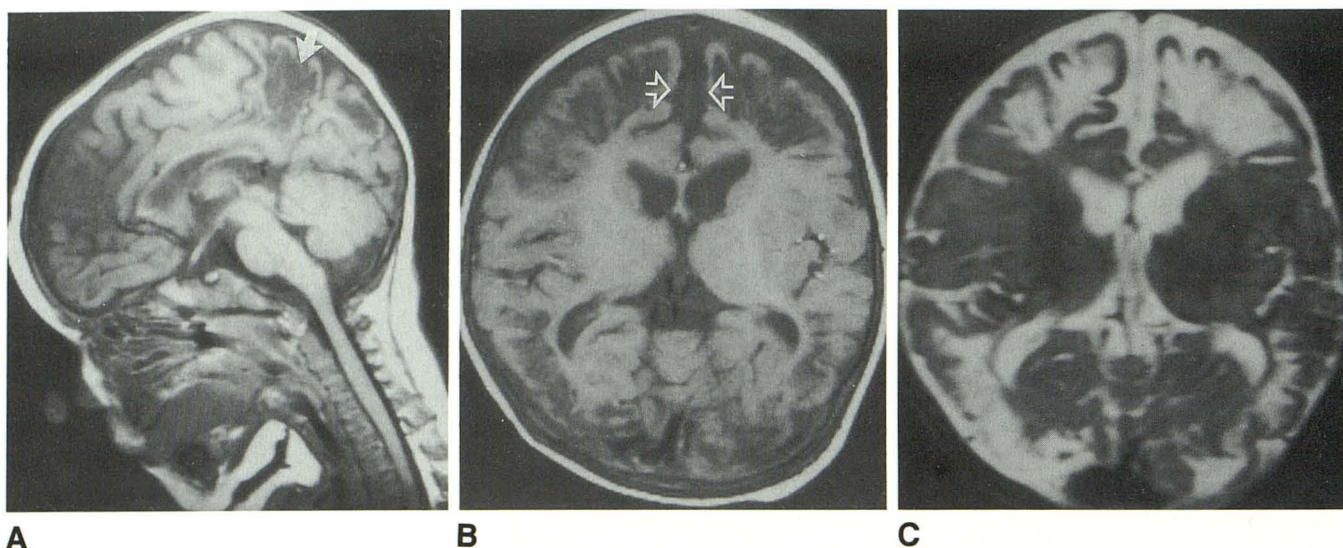


Fig. 7.—Case 24: Partial asphyxia at 44 weeks; scan at 19 years.

A, Sagittal SE 600/20 image shows cortical thinning in watershed area between anterior and posterior cerebral arteries (arrow). Corpus callosum is abnormally thin. Area of low signal intensity in frontal region is volume averaging of CSF in interhemispheric fissure (see B).

B, Axial SE 700/20 image shows cortical thinning and subcortical T1 prolongation (gliosis) in anterior and posterior watershed regions. Immediate periventricular white matter is spared. Prominence of interhemispheric fissure in frontal region (arrows) results from atrophy of adjacent frontal lobes.

C, Axial SE 3000/120 image confirms that the immediately periventricular white matter is unaffected. Compare with Fig. 6.

periventricular white matter is supplied by (ventriculopedal) medullary arteries coursing inward from the cerebral cortex. As a result of this fetal vascular pattern, the watershed regions between the major cerebral arteries in premature neonates are in the periventricular white matter, particularly around the trigones and frontal horns of the lateral ventricles. As the ventriculofugal arteries develop, the watershed areas move peripherally until, in the adult, they lie in the cerebral cortex and subcortical white matter. Takashima and Tanaka [21] found that the development of the ventriculofugal branches is poor or nonexistent in premature neonates of less than 8-months gestation. Over the subsequent 3 months, these vessels slowly grow into the deep white matter; they are well developed in neonates older than 44-weeks gestational age [21]. The temporal sequence of the development of the ventriculofugal arteries exactly parallels and predicts the shift of the principal brain damage from being exclusively periventricular with no cortical involvement at 24–34 weeks to almost entirely cortical and subcortical with sparing of the periventricular region at 44 weeks.

The difference in the amount of tissue displaying prolonged T2 relaxation in the periventricular region in these neonates can also be explained in terms of maturation of the developing nervous system. The immature nervous system is very limited in its ability to react to tissue damage; damaged tissue undergoes liquefaction necrosis and is reabsorbed [6, 7]. As the nervous system matures, it begins to attempt to repair itself. In this process, known as gliosis, the astrocytes in the affected area undergo mitotic division and send out new processes from the cell bodies in areas that have sustained damage [22]. This process is seen on MR as areas of prolonged T2 relaxation because the glial tissue contains more free water than normal brain. It has never been established

exactly when the brain develops the ability to mount this glial response, although most estimate that it occurs in the mid to late second trimester [6, 7]. Our data suggest that a significant amount of tissue with a prolonged T2 relaxation time begins to develop in the periventricular area in response to injury at about 28 gestational weeks. All injuries sustained at 28-weeks gestational age or later were accompanied by a large amount of tissue with abnormally prolonged T2 relaxation in the injured area. Therefore, it can be deduced that the prolonged T2 relaxation time that we see on the MR images of these patients represents a glial response to injury and that significant glial response in the developing brain begins at approximately 28 gestational weeks.

Scans were atypical in three patients in this series. In case 17, the scan was atypical merely because it was obtained subacutely, 2 weeks after the event, in contradistinction to most scans, which were obtained several months to years after asphyxia. As a result of the temporal proximity to the event, the gyri were not yet shrunken but remained normal to slightly prominent in size. Furthermore, because the patient was so young at the time of the scan, the injury to the white matter was not appreciated on the long TR/TE images, the damage being masked by the inherently increased water content and prolonged T2 relaxation of the newborn white matter.

The scans in cases 16 and 18, patients who suffered complete circulatory arrests, were far more atypical, showing primarily basal ganglia, thalamic, and midbrain involvement with sparing of the cortex and subcortical white matter. This pattern of damage is typical for acute total asphyxia in the neonate [23–27]. Reasons for the difference in the pattern of brain damage in prolonged partial asphyxia as compared with acute total asphyxia have been proposed. In prolonged partial

asphyxia, hypotension and cerebral edema almost always ensue [8, 27]. Cerebral vascular autoregulation is lost, resulting in pressure passive flow [8]. As a consequence, watershed regions (mature or immature) are hypoperfused, toxic metabolites accumulate within them, and tissue damage results [8, 27, 28]. The brainstem, thalami, and basal ganglia, however, probably remain well perfused in hypotensive episodes [28, 29]. In complete circulatory arrest, however, there is an absence of blood flow and oxygen in the entire brain. Consequently, the most significant damage occurs in areas with the highest metabolic requirements; that is, the brainstem, thalami, and basal ganglia. Some have proposed that the maturity of the neurons plays a role in the selective vulnerability of these regions [30, 31]. Neuronal maturity may, indeed, be an important factor that is related to metabolic requirements.

It has been reported that delayed myelination accompanies perinatal asphyxia in both premature and term neonates [4, 17, 18]. Delayed myelination was present in seven of our patients, six of whom suffered term or postterm asphyxia. These patients were all 4 years old or less at the time of imaging. The two 4-year-old patients had severe damage to the hemispheric white matter, which showed substantial gliosis. The other four patients were 1 year old or less when first scanned. The fact that none of the older patients had delayed myelination supports the contention of Johnson et al. [4] that there is a window of time during which delayed myelination can be detected. They suggested that delayed myelination cannot be detected past the age of 2. Our results suggest that, in very severe insults, the myelination delay may be detected in children as old as 4 years.

The corpus callosum was abnormally thin in all patients in this study with the possible exception of the two neonates who were scanned before they were 1 month old. In both these patients, MR was performed only a few weeks after the asphyxic event, probably too early for degeneration of transcallosal fibers to have occurred. All other patients showed significant thinning of part or all of the corpus callosum. The thinning was believed to be the result of atrophy because the location within the corpus corresponded to the areas of brain with the greatest loss of white matter. The posterior aspect of the callosal body and the splenium (Figs. 1 and 2) were most commonly narrowed, probably as a result of the frequent destruction of the peritrigonal white matter and posterior watershed area. The entire corpus callosum was thin when the hemisphere was affected more diffusely (Fig. 7). Callosal thinning has previously been described as a result of cerebral hemispheric damage or atrophy [2] and is very suggestive of such damage when seen on sagittal images. The thinning is unlikely to have been a sequela of prior hydrocephalus because it was seen in all patients, whether hydrocephalus had been present or not.

The amount of brain damage seemed to be assessed more easily in patients who were imaged months or years after asphyxia. In the one patient with prolonged partial asphyxia who was imaged 2 weeks after the episode, the abnormalities were subtle. At least part of the reason for this subtlety is the high free water content of the normal immature, unmyelinated

brain [32]. As a consequence of this high water content, damaged tissue, which is easily distinguished in older children and adults by its high free water content, is difficult to detect in neonates. Only after many weeks or months, when the amount of normal free water diminishes and the amount of myelin increases, are the abnormalities seen well. Gliosis, cortical thinning, and ex vacuo ventricular enlargement, the major pathologic features, remained prominent and well visualized 18 and 19 years after the event. It appears, therefore, that MR may be more useful for the detection of asphyxic brain damage in the subacute or chronic phase than acutely.

To summarize, we have reviewed the MR scans of 25 patients who suffered perinatal asphyxia. The pattern of brain damage as detected by MR was seen to evolve in a predictable manner corresponding to the known maturation of the brain and its vascular supply. A different pattern of damage, involving primarily the thalami, basal ganglia, and midbrain, was seen in the two patients who suffered complete circulatory arrest. MR appears to be a powerful tool in assessing brain damage resulting from perinatal asphyxia.

REFERENCES

1. Barkovich AJ, Chuang SH, Norman D. MR of neuronal migration anomalies. *AJNR* 1987;8:1009-1017
2. Barkovich AJ, Norman D. Anomalies of the corpus callosum: correlation with further anomalies of the brain. *AJNR* 1988;9:493-501
3. Wilson DA, Steiner RE. Periventricular leukomalacia: evaluation with MR imaging. *Radiology* 1986;160:507-511
4. Johnson MA, Pennock JM, Bydder GM, Dubowitz LMS, Thomas DJ, Young IR. Serial MR imaging in neonatal cerebral injury. *AJNR* 1987;8:83-92
5. Baker LL, Stevenson DK, Enzmann DR. End stage periventricular leukomalacia: MR evaluation. *Radiology* 1988;168:809-815
6. Raybald C. Destructive lesions of the brain. *Neuroradiology* 1983;25:265-291
7. Gilles FH. Neuropathologic indicators of abnormal development. In: Freeman JM, ed. *Prenatal and perinatal factors associated with brain disorders*. Bethesda: National Institutes of Health, 1985 (publication No. 85-1149)
8. Volpe JJ. *Neurology of the newborn*. Philadelphia: Saunders, 1987:160-279
9. Kulakowski S, Larroche J-C. Cranial CT in cerebral palsy. An attempt at anatomoclinical and radiological correlation. *Neuropediatrics* 1980;4:339-353
10. Flodmark O, Becker LE, Harwood-Nash DC, Fitzhardinge PM, Fitz CR, Chuang SH. Correlation between computed tomography and autopsy in premature and full term neonates that have suffered perinatal asphyxia. *Radiology* 1980;137:93-103
11. Adsett DB, Fitz CR, Hill A. Hypoxic-ischemic cerebral injury in the term newborn: correlation of CT findings with neurological outcome. *Dev Med Child Neurol* 1985;27:155-160
12. Flodmark O, Roland EH, Hill A, Whitfield MR. Periventricular leukomalacia: radiologic diagnosis. *Radiology* 1987;162:119-124
13. Tandorf K, Melchior JC, Pederson H. CT findings in spastic cerebral palsy: clinical, aetiological and prognostic aspects. *Neuropediatrics* 1984;15:120-124
14. Lipp-Zwahlen AE, Deonna T, Chrzanowski R, Micheli JL, Calame A. Temporal evaluation of hypoxic-ischemic brain lesions in asphyxiated full term newborns as assessed by computerized tomography. *Neuroradiology* 1985;27:138-144
15. DiChiro G, Arimitus T, Pellock JM, et al. Periventricular leukomalacia related to neonatal anoxia: recognition by computed tomography. *J Comput Assist Tomogr* 1978;2:352-355
16. Magilner AD, Wertheimer IS. Preliminary results of a CT study of neonatal

- brain hypoxia-ischemia. *J Comput Assist Tomogr* 1980;4:457-463
17. McArdle CB, Richardson CJ, Hayden CK, Nicholas DA, Amparo EG. Abnormalities of the neonatal brain: MR imaging. Part II. Hypoxic-ischemic brain injury. *Radiology* 1987;163:395-403
 18. Van de Bor M, Guit GL, Schreuder AM, Wonderge J, Vielvoye GJ. Early detection of delayed myelination in preterm infants. *Pediatrics* 1989;84:407-411
 19. DeReuck J. The human periventricular arterial blood supply and the anatomy of cerebral infarctions. *Eur Neurol* 1971;5:321-334
 20. DeReuck J, Chattha AS, Richardson EP. Pathogenesis and evolution of periventricular leukomalacia in infancy. *Arch Neurol* 1972;27:229-236
 21. Takashima S, Tanaka K. Development of cerebrovascular architecture and its relationship to periventricular leukomalacia. *Arch Neurol* 1978;35:11-16
 22. Blackwood W. Normal structure and general pathology of the nerve cell and neuroglia. In: Blackwood W, Corsellis JAN, eds. *Greenfield's neuropathology*, 3rd ed. Chicago: Year Book, 1976:27-28
 23. Ranch JB, Windle WF. Brain damage in the monkey, *Macaca malatta*, by asphyxia neonatorum. *Exp Brain Res* 1959;1:130-154
 24. Myers RE. Two patterns of perinatal brain damage and their conditions of occurrence. *Am J Obstet Gynecol* 1972;112:246-276
 25. Schneider H, Ballowitz L, Schachinger H, Hanefeld F, Droszus J-U. Anoxic encephalopathy with predominant involvement of basal ganglia, brainstem, and spinal cord in the perinatal period. *Acta Neuropathol (Berl)* 1975;32:287-298
 26. Leech RW, Alvord EC Jr. Anoxic-ischemic encephalopathy in the human neonatal period: the significance of brainstem involvement. *Arch Neurol* 1977;34:109-113
 27. Wilson ER, Mirra SS, Schwartz JF. Congenital diecephalic and brainstem damage: neuropathologic study of three cases. *Acta Neuropathol (Berl)* 1982;57:70-74
 28. Myers RE. Four patterns of perinatal brain damage and their conditions of occurrence in primates. *Adv Neurol* 1975;10:223-234
 29. Cavazzuti M, Duffy TE. Regulation of local cerebral blood flow in normal and hypoxic newborn dogs. *Ann Neurol* 1982;11:247-257
 30. Roland EH, Hill A, Norman MG, Flodmark O, MacNab AJ. Selective brainstem injury in an asphyxiated newborn. *Ann Neurol* 1988;23:89-92
 31. Duffy TE, Cavazzuti M, Cruz NF, Sokoloff L. Local cerebral glucose metabolism in newborn dogs: effects of hypoxia and halothane anesthesia. *Ann Neurol* 1982;11:233-246
 32. Dobbing J, Sands J. Quantitative growth and development of human brain. *Arch Dis Child* 1973;48:757-767