



Discover Generics

Cost-Effective CT & MRI Contrast Agents



FRESENIUS
KABI

WATCH VIDEO

AJNR

New triple coaxial catheter system for carotid angioplasty with cerebral protection.

J Theron, P Courtheoux, F Alachkar, G Bouvard and D Maiza

AJNR Am J Neuroradiol 1990, 11 (5) 869-874

<http://www.ajnr.org/content/11/5/869.citation>

This information is current as
of June 19, 2025.

New Triple Coaxial Catheter System for Carotid Angioplasty with Cerebral Protection

J. Theron,¹ P. Courtheoux,¹ F. Alachkar,¹ G. Bouvard,² and D. Maiza³

The fear of dislodging an embolus from an ulcerative plaque [1] has slowed down the application of angioplasty [2, 3] to

supraaortic arteries and, particularly, to carotid bifurcations [4–17]. We previously reported an angioplasty technique involving temporary occlusion of the internal carotid artery to prevent cerebral embolization during manipulation of ulcerated plaques [18]. The present article describes a new triple coaxial catheter system (Schneider [Europe] AG, Zurich, Switzerland) (Fig. 1), which simplifies this technique and allows angioplasty with a “cerebral protection” based on the same concept of distal temporary occlusion of the internal carotid artery.

Materials and Methods

Patients

To date, 13 patients have been treated with the complete triple coaxial system. This group includes 12 men and one woman, 55 to 77 years old (mean, 61). The right carotid artery was involved in six cases. In all cases, the carotid stenosis was hemodynamically and angiographically significant. On angiography, the degree of stenosis ranged from 70% to more than 95%, and the plaque was obviously ulcerated in five cases. In all patients the stenosis involved the internal carotid artery; in three patients (cases 3, 4, and 11) it also involved the common carotid artery; and in one patient (case 4) there was an associated preocclusive stenosis of the external carotid artery. All the patients had a Doppler study before and after the procedure, and all were scheduled for a new Doppler at 3 months, 6 months, and 1 year after the angioplasty. The mean follow-up period in this series was 8½ months.

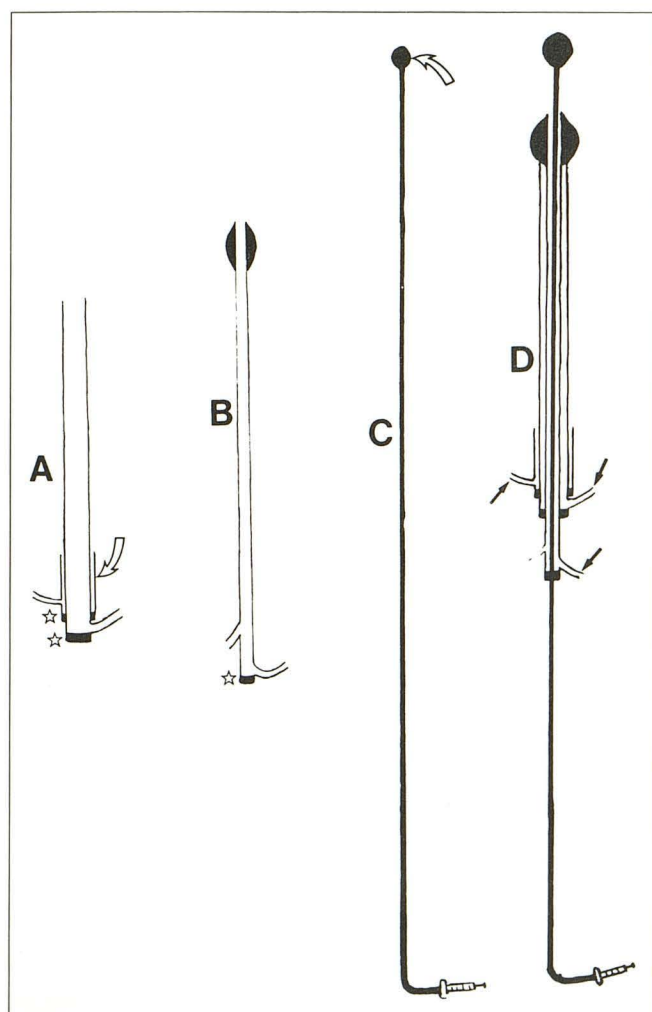


Fig. 1.—Schematic representation of triple coaxial system.

A, 100-cm-long 9-French guiding catheter (2.1-mm inner diameter) in a valve (upper star) introducer (curved arrow) with lateral flushing. A valve (lower star) connector with lateral flushing is at proximal end of guiding catheter.

B, 120-cm-long 5-French angioplasty catheter. The balloon is 1.5 cm long, its diameter ranges from 5 to 7 mm depending on the artery to be dilated. A valve (star) connector with lateral flushing is at its proximal end.

C, 250-cm-long 3-French Teflon catheter with a latex balloon (Ingenor no. 17) attached to its distal end (curved arrow).

D, Complete system with angioplasty and occlusive balloons inflated. Three lateral flushings (arrows) are necessary.

Received August 14, 1989; revision requested October 2, 1989; revision received January 4, 1990; accepted January 6, 1990.

Presented at the annual meeting of the American Society of Neuroradiology, Orlando, March 1989.

¹Department of Neuroradiology and Interventional Radiology, Service de Neuroradiologie et de Radiologie Interventionnelle, C.H.U. de Caen, Avenue de la Cote de Nacre, 14033 Caen, France. Address reprint requests to J. Theron.

²Department of Nuclear Medicine, Caen, France.

³Department of Cardiovascular Surgery, Caen, France.

TABLE 1: Clinical Presentations and Results of Carotid Angioplasty

Case No.	Symptoms	Before Angioplasty			After Angioplasty	
		Lesion Location	Percent Stenosis	Ulceration	Percent Stenosis	No. of Follow-up Months Without New Symptoms
1	TIA, left side	ICA	95	Yes	30	3
2	TIA, right side	ICA	95	No	0	13
3	TIA, left side; CT = deep hypodensity	ICA, CCA	95	No	20	8
4	Hemiplegia without clinical deficit; CT = deep hypodensity	ICA, ECA, CCA	95	Yes	50 (ICA), 100 (ECA)	9
5	Right hemiplegia, minor deficit inferior limb; CT = hypodensity	ICA	90	Yes	10	7
6	Transient aphasia	ICA	90	No	0	12
7	TIA, left upper limb	ICA	85	Yes	0	11
8	TIA, left upper limb	ICA	90	Yes	0	10
9	Transient aphasia	ICA	90	No	0	11
10	Intellectual deterioration; CT = right frontal infarction	ICA	90	No	0	9
11	Asymptomatic; low cerebral blood flow, no increase after Diamox	ICA, CCA	95	No	0	9
12	Asymptomatic; low cerebral blood flow, no increase after Diamox	ICA	95	No	0	12
13	Asymptomatic; low cerebral blood flow, asymmetric after Diamox	ICA	70	No	10	8

Note.—TIA = transient ischemic attack; ICA = internal carotid artery; CCA = common carotid artery; ECA = external carotid artery.

Table 1 gives the clinical presentations and results of carotid angioplasty in the 13 patients. Ten patients presented with neurologic symptoms: two (cases 7 and 8) had transient upper limb palsy, three (cases 1, 2, and 3) had transient hemiplegia, two (cases 6 and 9) had transient aphasia, one (case 4) had hemiplegia of 36 hr duration without residual clinical deficit, one (case 5) had hemiplegia with residual minor deficit of the inferior limb, and one (case 10) had acute intellectual deterioration with small right frontal infarction on CT. In three patients (cases 11, 12, and 13), the carotid stenosis was discovered on asymptomatic patients in the course of angiographic investigations for multiple atherosclerotic lesions. In these three cases, the cerebral blood flow studies showed low numbers as compared with normal values, and no increase (cases 11 and 12) or an asymmetric augmentation (case 13) during vasodilatory acetazolamide (Diamox) challenge [19, 20].

Technique

All patients were given platelet antiagregant (250 mg of aspirin or, preferentially, 500 mg of ticlopidine [Ticlid] every day) one week before the procedure. The technique (Figs. 2 and 3) proceeded as follows: (A) The guiding catheter was positioned in the common carotid artery. (B) The occlusive and angioplasty catheters were introduced into the guiding catheter, and the latex balloon was positioned at the level of the stenosis. (C) Before the occlusive latex balloon (Ingenor, Paris) was inflated, 6000 units of heparin were administered. After inflation, clinical tolerance to the occlusion was tested. Because the occlusion time is usually very short (rarely more than 10 min), only a simple check on the patient's level of consciousness and motor function was necessary. (D) The angioplasty balloon was inflated, making sure that the guiding catheter was at the inferior edge of the inflated balloon to prevent inferior and superior displace-

ment upon inflation. (E) The angioplasty balloon was deflated and the catheter was withdrawn while the occlusive balloon remained inflated. The tip of the angioplasty catheter remained at the valve connector of the guiding catheter. Potential atherosclerotic particles or clots that could have been dislodged during inflation of the angioplasty balloon were aspirated forcefully with a 20-ml syringe through the lateral line of the valve connector at the proximal end of the guiding catheter. Saline was injected forcefully after aspiration to push the potential residual fragments toward the external carotid artery. The chances of having a fragment in the ophthalmic artery via the facial or the middle meningeal artery remain in our opinion extremely low. Given the risk of leaving a residual fragment at the site of angioplasty, we prefer that they flow into one or more of the many nondangerous branches of the external carotid artery. (F) The occlusive latex balloon was deflated, and an angiographic series was performed. When the morphologic result was not totally satisfactory (two cases), a balloon angioplasty catheter of the same size or larger was again advanced on the Teflon catheter and a new dilatation was performed. (G) After angioplasty, the valve introducer was left in the femoral artery until the blood coagulation returned to normal. Antiagregants (aspirin or ticlopidine) were maintained for 2 months.

A special variant of this technique (Fig. 4) was used on two patients (cases 3 and 11) whose carotid stenosis involved both the internal and common carotid arteries. To obtain an efficient dilatation of the common carotid without overdilatation of the internal carotid, a second angioplasty catheter (5-French 4.5 mm–2 cm balloon [Cook, Paris]) was introduced into the other femoral artery and positioned partly in the common carotid and partly in the origin of the external carotid. The complete triple coaxial system (5-French 5 mm–1.5 cm balloon) was similarly positioned in part in the common carotid artery and in part in the internal carotid. Inflation of the two angioplasty balloons allowed, in their inferior portions located in the common

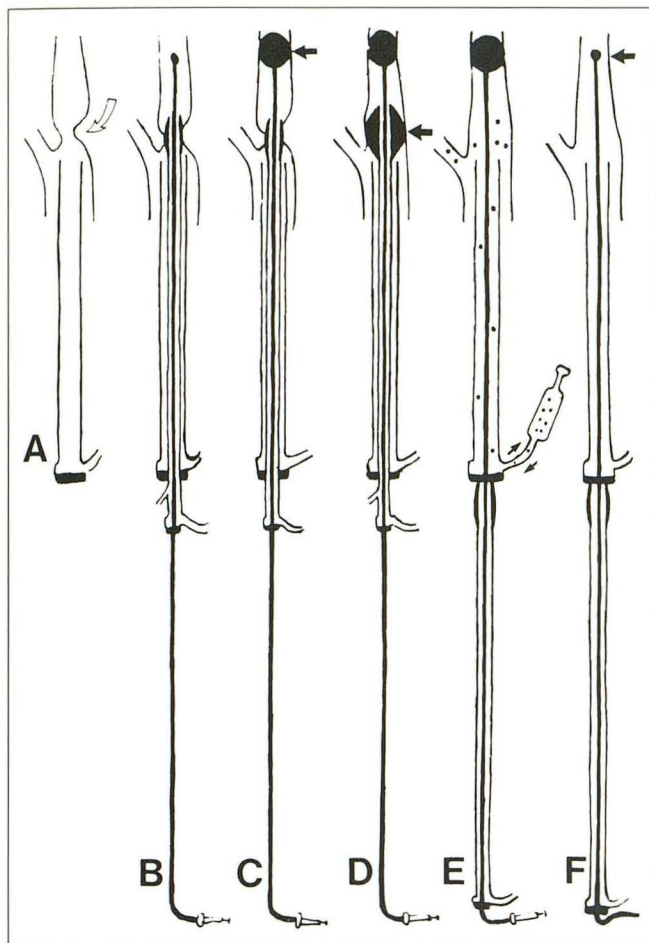


Fig. 2.—Schematic representation of angioplasty procedure. The valve introducer positioned in femoral artery is not shown (see Fig. 1).

A, Guiding catheter is positioned in common carotid artery close to the stenosis (curved arrow).

B, Angioplasty and occlusive catheters are positioned in internal carotid artery.

C, Occlusive latex balloon (arrow) is inflated.

D, Angioplasty balloon (arrow) is inflated.

E, Angioplasty catheter is deflated and withdrawn. Occlusive balloon remains inflated. Atherosclerotic particles or clots are aspirated via the valve connector of the guiding catheter (arrows).

F, Occlusive balloon (arrow) is deflated.

carotid artery, a "kissing" balloon dilatation of 4.5 mm + 5 mm. At the origin of the internal carotid, only a 5-mm dilatation was consequently obtained without overdilatation.

Results

A normal or subnormal diameter of the dilated artery was obtained on 10 cases. The aspirated blood after angioplasty showed, in four of the six analyzed cases, cholesterol crystals whose size ranged from 600 to 1200 μ m. In one patient (case 1) with preocclusive stenosis of the internal carotid artery and an ulceration of the plaque (Fig. 5), there was a 30% residual stenosis on the immediate postangioplasty angiogram but the arterial wall appeared smooth and there was no residual hemodynamic modification at Doppler. In another patient (case 4), in whom the plaque involved the right common and

internal carotid arteries with an associated preocclusive stenosis of the external carotid, angioplasty of the internal carotid did not succeed in fully dilating the stenosis of the internal carotid and occluded the external carotid. A persistent 50% stenosis of the internal carotid was hemodynamically significant at Doppler. This case led us to design the variant of the technique with two angioplasty balloons, as previously described, which was successfully used in cases 3 and 11. A normal caliber of the artery was obtained in one patient (case 11, Fig. 4), and a 20% residual stenosis, which was not significant at Doppler, was obtained in the second patient (case 3). There was no local or neurologic complication during or after the procedure. No patient who had transient neurologic symptoms has manifested further symptoms since the procedure. The three asymptomatic patients with abnormal blood flow studies showed a restoration of the cerebral vascular reserve at acetazolamide challenge and have experienced a marked subjective clinical improvement.

Discussion

The fear of cerebral embolization has delayed the application of angioplasty to the carotid bifurcation. Angiographically observed embolization is usually asymptomatic and occurs in 5% of peripheral angioplasties [21]. The atherosclerotic plaque of the carotid bifurcation is frequently ulcerated [1] and the area supplied is less likely to be clinically silent. Our experience in embolization with temporary occlusion of the internal carotid artery and vertebral artery [22] had led us to propose in 1987 a similar technique for carotid angioplasty [18]. The new system that we present in this article has the following technical advantages: (1) There is, with the exception of the described special variant, only one femoral artery used. (2) A 9-French guiding catheter accommodates both the angioplasty and occlusive balloon catheters. (3) Only one catheterization of the common carotid artery is necessary. (4) The occlusive latex balloon attached on the 3-French Teflon catheter makes the passage of the stenosis very gentle even when the arterial diameter is markedly narrowed (Fig. 5). (5) The inner diameter of the guiding catheter is wide (2.1 mm) and allows not only aspiration of cholesterol crystals [23] but also the eventual aspiration of bigger particles. This represents, in our opinion, a major advantage over other systems recently proposed, whose aspiration lumen is smaller [24]. (6) The angioplasty balloon is maintained during dilatation by the guiding catheter and there is no possibility of distal sliding of the balloon, which, in our opinion, is a major causative factor of particle detachment. The risk of clot detachment during or after angioplasty is also much lower in our opinion if a strong platelet antiagregant such as ticlopidine is given [25].

Considering the magnitude of the trials necessary to establish the value of endarterectomy in stroke prevention [26], the definitive place of angioplasty in this disease will probably not be determined in the near future. If it were to be a viable alternative to surgery, it would have to be successful with a similar or lower morbidity than is found with endarterectomy. In most cases, angioplasty dramatically increases the flow in the dilated carotid artery. Ulcerations are prominently men-

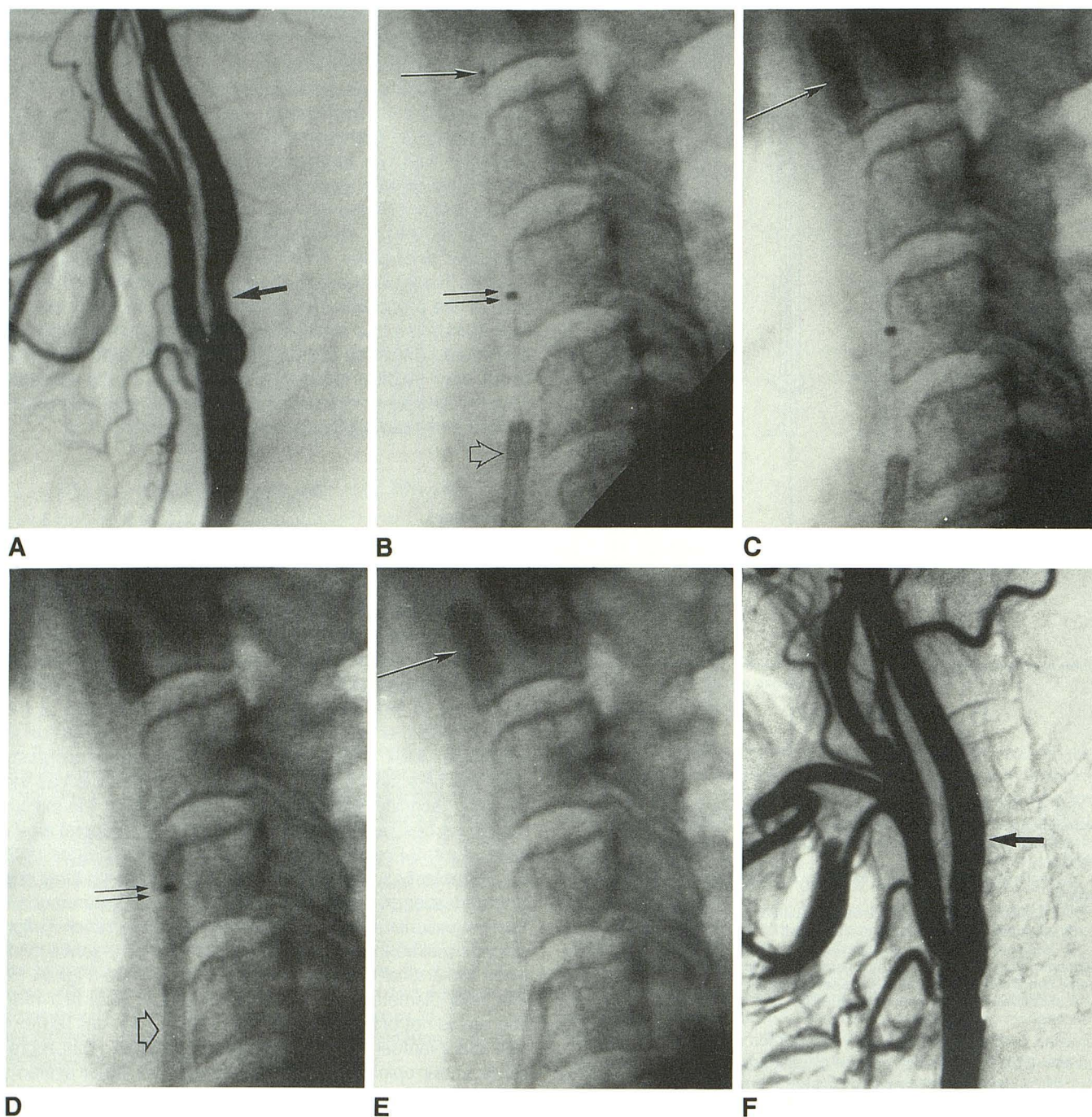


Fig. 3.—Case 13: Angioplasty of a stenosis of the internal carotid artery.

A, 70% stenosis (arrow).

B, Stenosis is passed; occlusive catheter (arrow) and angioplasty catheter (double arrow) are introduced into guiding catheter (open arrow). Angioplasty balloon has only one central radiopaque mark.

C, Occlusive balloon (arrow) is inflated.

D, 6-mm angioplasty balloon (double arrow) is inflated. Angioplasty balloon is restrained from moving by the guiding catheter (open arrow).

E, Angioplasty balloon is deflated and catheter is withdrawn. Occlusive balloon remains inflated (arrow). The potential atherosclerotic particles or clots are aspirated through the guiding catheter.

F, Angiographic series after angioplasty shows a normal diameter of the artery (arrow).

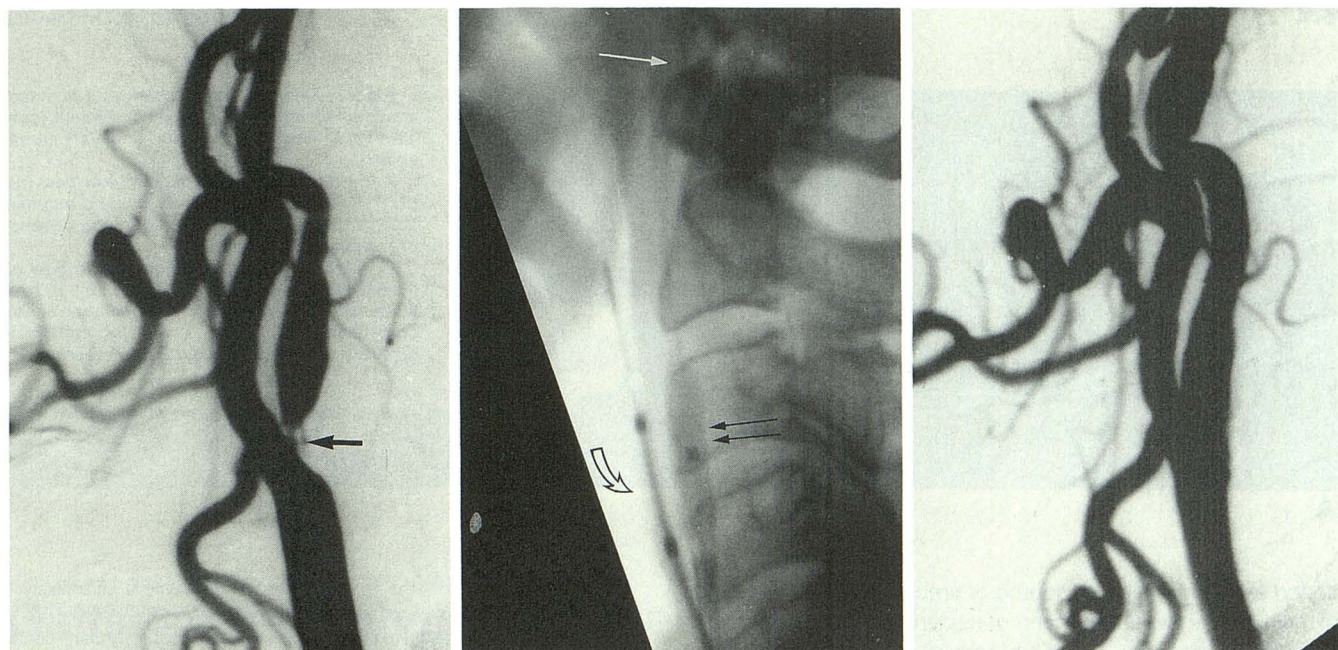


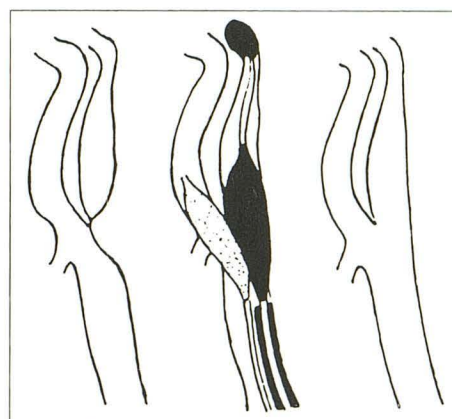
Fig. 4.—Case 11: Preocclusive stenosis of carotid artery involving common and internal segments. Treatment involved a special variant of the technique (see text).

A, Series before angioplasty shows preocclusive stenosis of internal carotid artery (arrow).

B, Positioning of triple coaxial system: occlusive balloon (white arrow), 5-mm angioplasty balloon (double arrow) partly in the internal and partly in the common carotid arteries. A second angioplasty catheter (4.5 mm–2 cm 5-French balloon) (curved arrow) is positioned in the external and partly in the common carotid arteries.

C, Series after angioplasty.

D, Schematic representation of technique that allows efficient dilatation of internal carotid artery (5 mm) and common carotid artery (5 mm + 4.5 mm) without overdilatation of internal carotid artery.



D

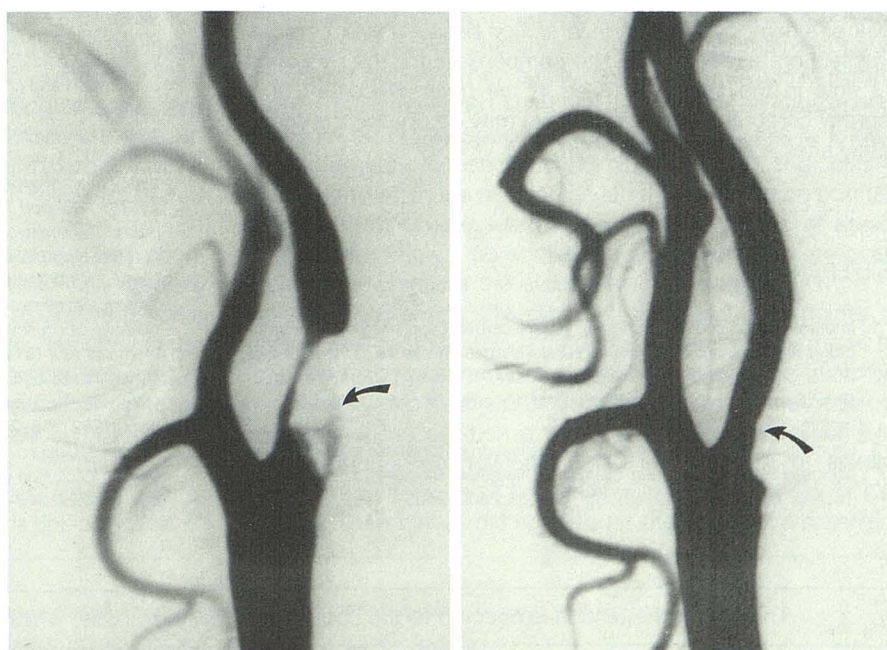


Fig. 5.—Case 1: Preocclusive stenosis of internal carotid artery with ulceration responsible for TIA.

A, Series before angioplasty shows preocclusive stenosis of internal carotid artery. Atherosclerotic plaque appears ulcerated (arrow).

B, Immediate postangioplasty series shows persistent 30% stenosis (not significant at Doppler). There is smoothing of arterial wall (arrow).

A

B

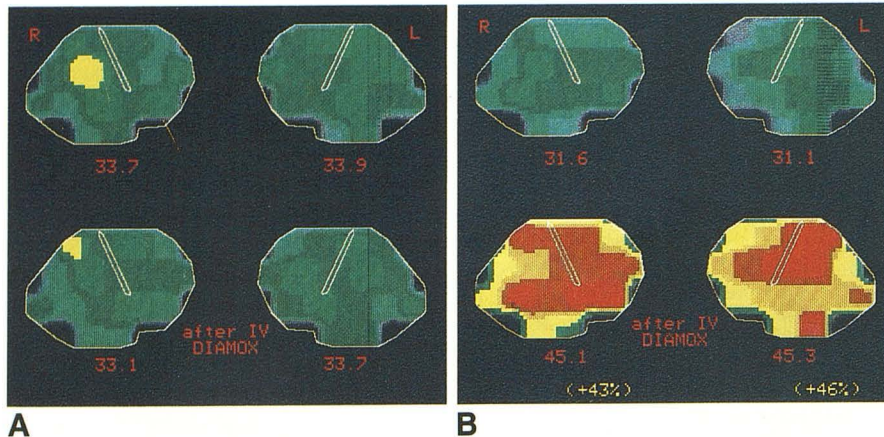


Fig. 6.—Cerebral flow studies with acetazolamide challenge in asymptomatic patient (case 11, Fig. 4) who had angioplasty of left carotid artery.

A, Before angioplasty: bilateral low flow (ISI) (R: 33.7, L: 33.9). After IV Diamox, no augmentation of flow is observed, confirming absence of cerebral flow reserve.

B, After angioplasty: cerebral blood flow remains low on both sides (R: 31.6, L: 31.1). After IV Diamox, there is marked augmentation of flow on both sides (R: +43%, L: +46%), confirming recovery of a normal cerebral flow reserve.

tioned as being the usual source of emboli, and the presence of visible ulcerations has been considered a contraindication to carotid angioplasty [16]. Our technique of "cerebral protection" is now improved by the triple coaxial system and prevents most emboli from reaching the cerebral circulation. Furthermore, angioplasty may promote healing of the ulceration by modification of the turbulent flow that was caused by the stenosis. Remodeling of the media and intima with reendothelialization is known to occur after angioplasty [27, 28] and may prove an adequate treatment for ulcerated plaques. For these reasons, we would not restrict angioplasty to smooth lesions as long as a cerebral protection is used (Fig. 5).

In our opinion, the hemodynamic factor has received too little attention relative to the embolic factor in discussions of the mechanism of neurologic symptoms. When a carotid stenosis is discovered in an asymptomatic patient, we believe there is justification to treat this stenosis by angioplasty or surgery when the cerebral flow studies show no augmentation at the acetazolamide challenge (Fig. 6). In this kind of response, labeled type III by Rogg et al. [20], patients are at risk of a hemodynamic brain infarction because their cerebral vessels are already dilated to compensate for the reduction of flow in the carotid arteries in the neck. Recovery of a normal cerebral blood flow reserve may be dramatic immediately after angioplasty (Fig. 6B).

REFERENCES

1. Imparato AM, Rilez TS, Ecorstein F. The carotid bifurcation plaque; pathologic finding associated with cerebral ischemia. *Stroke* 1979;10:238-245
2. Dotter CT, Judkins MP. Transluminal treatment of arteriosclerotic obstruction: description of a new technique and a preliminary report of its applications. *Circulation* 1964;30:654-670
3. Gruntzig A, Hopff H. Perkutane rekanalisation chronischer arterieller Verschlüsse mit einem neuen dilatations Katheter. Modifikation der Dotter Technik. *Dtsch Med Wochenschr* 1974;99:2502-2505
4. Bockenhimer S, Mathias K. Percutaneous transluminal angioplasty in arteriosclerotic internal carotid artery stenosis. *AJNR* 1983;4:791-792
5. Freitag J, Koch RD, Wagemann W. Percutaneous angioplasty of the carotid artery stenoses. *Neuroradiology* 1986;28:126-127
6. Kachel R, Endert G, Basche S, Grossman, Glaser F. Percutaneous transluminal angioplasty (dilatation) of carotid, vertebral and innominate artery stenoses. *Cardiovasc Intervent Radiol* 1987;10:142-146
7. Mathias K, Schlosser V, Reinke M. Katheterrekanalisation eines Subklavianverschlusses. *ROFO* 1980;132:346-347
8. Mathias K. Perkutane transluminale Katheterbehandlung supraaortaler Arterienobstruktion. *Angiology* 1981;3:47-50
9. Mathias K. Katheterbehandlung der arteriellen Verschlusskrankheit supraaortaler Gefäße. *Radiologie* 1987;27:547-554
10. Mortarjeme A, Keifer JW, Zuska AJ. Percutaneous transluminal angioplasty of the brachiocephalic arteries. *AJR* 1982;138:457-462
11. Theron J, Courtheoux P, Henriot JP, et al. Angioplasty of supra-aortic arteries. *J Neuroradiol* 1984;11:187-200
12. Theron J, Melancon D, Ethier R. Pre-subclavian steal syndromes and their treatment by angioplasty: hemodynamic classification of subclavian artery stenoses. *Neuroradiology* 1985;27:265-270
13. Tsai FY, Matovitch V, Hieshima G, et al. Percutaneous transluminal angioplasty of the carotid artery. *AJNR* 1986;7:349-358
14. Vitek JJ, Raymon BC, Oh SJ. Innominate artery angioplasty. *AJNR* 1984;5:113-114
15. Vitek JJ, Keller FS, Duvall ER, Gupta KL, Chandra-Sekar B. Brachiocephalic artery dilatation by percutaneous transluminal angioplasty. *Radiology* 1986;158:779-785
16. Wiggli V, Gratzl O. Transluminal angioplasty of stenotic carotid arteries: case report and protocol. *AJNR* 1983;4:791-792
17. Zeumer H. Vascular recanalizing techniques in interventional neuroradiology. *J Neurol* 1985;231:287-294
18. Theron J, Raymond J, Casasco A, Courtheoux P. Percutaneous angioplasty of atherosclerotic and postsurgical stenosis of carotid arteries. *AJNR* 1987;8:495-500
19. Hauge A, Nicolayssen G, Thoresen M. Acute effects of acetazolamide on cerebral blood flow in man. *Acta Physiol Scand* 1983;233-239
20. Rogg J, Rutigliano M, Yonas H, Johnson DW, Penhney S, Latchaw RE. The acetazolamide challenge: imaging technique designed to evaluate cerebral blood flow reserve. *AJNR* 1989;10:803-810
21. Waltman AC, Greenfield AJ, Athanasoulis CA. Transluminal angioplasty: general rules and basic considerations. In Athanasoulis CA, Pfister RC, Green RE, Roberson GH, eds. *Interventional radiology*. Philadelphia: Saunders, 1982:253-272
22. Theron J, Cosgrove R, Melanson D, Ethier R. Embolization with temporary balloon occlusion of the internal carotid or vertebral arteries. *Neuroradiology* 1986;28:246-253