



Get Clarity On Generics

Cost-Effective CT & MRI Contrast Agents



FRESENIUS
KABI

WATCH VIDEO

AJNR

Identification of CSF fistulas by radionuclide counting.

Y Yamamoto, K Kunishio, N Sunami, Y Yamamoto, T Satoh, M Suga and S Asari

AJNR Am J Neuroradiol 1990, 11 (4) 823-826

<http://www.ajnr.org/content/11/4/823>

This information is current as
of August 1, 2025.

Identification of CSF Fistulas by Radionuclide Counting

Yoshihiro Yamamoto^{1,2}
 Katsuzo Kunishio³
 Norio Sunami¹
 Yuji Yamamoto¹
 Toru Satoh³
 Masakazu Suga¹
 Shoji Asari³

A radionuclide counting method, performed with the patient prone and the neck flexed, was used successfully to diagnose CSF rhinorrhea in two patients. A normal radionuclide ratio (radionuclide counts in pledget/radionuclide counts in 1-ml blood sample) was obtained in 11 normal control subjects. Significance was determined to be a ratio greater than 0.37.

Use of radionuclide counting method of determining CSF rhinorrhea is recommended when other methods have failed to locate a site of leakage or when posttraumatic meningitis suggests subclinical CSF rhinorrhea.

AJNR 11:823-826, July/August 1990

In 1956 Crow et al. [1] reported the successful use of a radionuclide counting method to detect intrathecally injected radionuclides at the site of CSF rhinorrhea. Since then, this method has been applied frequently [2-4]. However, there has been little confirmation of the reported normal values [3, 5]. Although it is well recognized that radionuclide cisternography for the detection of rhinorrhea should be performed with the patient in a position likely to maximize the amount of CSF leakage [6], no articles have mentioned the importance of patient position in the radionuclide counting method. The purpose of this study was twofold: to determine the normal levels for radioactive nasal secretion and to report two cases of CSF rhinorrhea in which radionuclide counting was positive only after the patients were placed in the prone or neck-flexed position after intrathecal injection of ¹¹¹In-DTPA.

Subjects and Methods

Cotton pledgets, 1 cm square and 2 mm thick, were ligated with silk thread. One hour after intrathecal injection of 1 mCi (37 MBq) of ¹¹¹In-DTPA by lumbar puncture, cotton pledgets, pretreated with a swab containing 2% lidocaine and 0.001% adrenaline, were introduced on both sides into three regions: the sphenoid recess, the olfactory cleft, and the middle meatus of the nasal cavity (Fig. 1) [1-3]. Simultaneously, a pledget was unilaterally inserted into the space between the gingiva and buccal mucosa as a control. The threads of all pledgets were fixed on the cheek with numbered tape. After insertion of the pledgets, the patient was placed in the supine position for 2 hr, then the sitting position for 3 hr (Fig. 2A). The pledgets were then removed, and a 1-ml blood sample was concurrently collected. New pledgets were then introduced at the same sites, and the patient was placed in the prone position for another 30 min (Fig. 2B). The pledgets were again removed, and a 1-ml blood sample was taken. The 60-sec radionuclide counts of the pledgets and blood specimens were determined as the mean value, after counting for 5 min with a well-type gamma counter. The ratio of the radionuclide count of each pledget to that of the blood specimen concurrently obtained was calculated using the formula: radionuclide ratio = radionuclide count of a pledget/radionuclide count of the 1-ml blood specimen.

Received June 13, 1989; revisions requested July 25, 1989 and December 8, 1989; final revision received December 28, 1989; accepted December 29, 1989.

¹ Department of Neurological Surgery, Matsuyama Shimon Hospital, 2-6-5 Ohtemachi, Matsuyama 790, Japan.

² Present address: Department of Neurosurgery, University of Mississippi Medical Center, 2500 N. State St., Jackson, MS 39216. Address reprint requests to Yoshihiro Yamamoto.

³ Department of Neurological Surgery, Okayama University Medical School, Okayama, Japan.

0195-6108/90/1104-0823
 © American Society of Neuroradiology

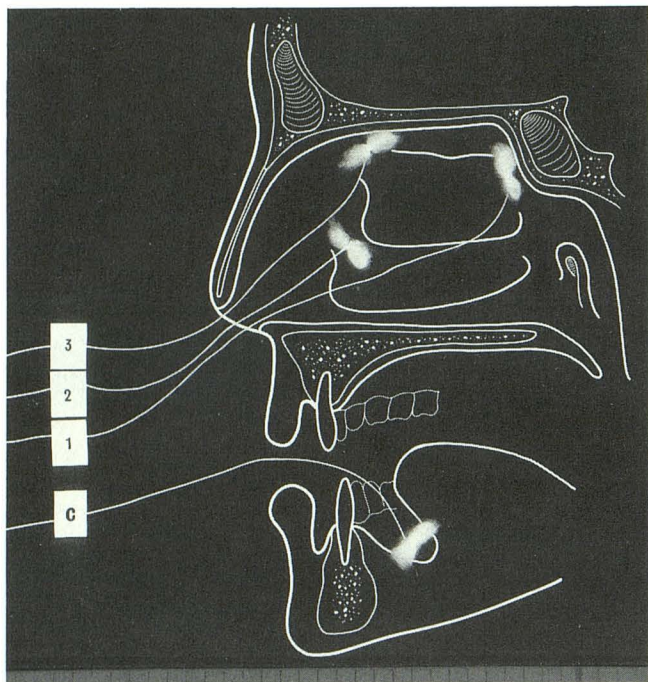


Fig. 1.—Placement sites of cotton pledgets.

1, Sphenoethmoid recess.

2, Middle meatus.

3, Olfactory cleft.

C, Buccogingival fold (control).

Normal Subjects

Our study included 11 patients, six males and five females 6 to 51 years old, who were admitted to Matsuyama Shimin Hospital for radiocisternographic evaluation of possible communicating hydrocephalus. These patients turned out to be normal (i.e., without stasis or ventricular reflux). None of the patients had rhinorrhea or was suspected of having a CSF fistula. The radionuclide ratios obtained in these patients are summarized in Figure 3. The mean was 0.158; the standard deviation was 0.101. None of the ratios exceeded 0.37.

Case Reports

Case 1

A 29-year-old man was injured in a motorcycle accident. About a month later, bilateral rhinorrhea and meningitis developed, but im-

provement was seen in 2 to 3 days. Subsequently, coldlike symptoms and rhinorrhea developed but were left untreated. Thirteen years after the accident, the patient had headache, high fever, and transient loss of consciousness. On admission, he showed clear consciousness with no neurologic abnormality other than a decrease in the sense of smell on the left side; no rhinorrhea was evident. The symptoms of meningitis improved within 2 to 3 days. Plain skull films showed no fracture or cloudiness in the paranasal sinuses. CT revealed a low-density area in the left frontal lobe, suggesting cerebral encephalomalacia. After intrathecal instillation of ^{111}In -DTPA and intranasal insertion of cotton pledgets as described in the radionuclide counting method (Fig. 1), the patient rested 2 hr in the supine position and then 3 hr in the sitting position; no significant differences in the radionuclide ratios were observed with either position (Table 1). However, after 30 min in the prone position, the radionuclide ratios of the left sphenoethmoid recess and middle meatus of the nose increased significantly to 0.548 and 0.563, respectively, suggesting the presence of CSF in these regions. Concurrent radionuclide cisternography, however, revealed no findings of CSF rhinorrhea as hot spots on the radiograph. Nine months later, the patient underwent a left frontal craniotomy. A depressed fracture accompanied by two dural defects leading to the left sphenoidal and frontal sinuses were found. These findings were consistent with the diagnosis by the radionuclide counting method. The CSF fistulas were repaired using femoral fasciae. Rhinorrhea and meningitis did not recur postoperatively. In addition, the postoperative radionuclide ratios returned to normal levels (Table 1).

Case 2

A 5-year-old boy fell off his bicycle, striking the right frontal region. On emergency admission, he seemed clearly conscious. Neurologically, however, his sense of smell on the right side and visual acuity in the right eye were decreased. Plain skull films revealed a fracture of the right upper orbital rim. The disturbance of visual acuity of the right eye gradually improved, but meningitis occurred on the second day of hospitalization, and fever persisted for about 1 week. Rhinorrhea from the right nostril began after 1 month. The amount of discharge was one or two drops at a time, and the glucose level in the discharge was 90 to 135 mg/dl, suggesting CSF rhinorrhea. Cranial tomography and biplane CT, however, failed to visualize any fracture at the base of the frontal skull or in the paranasal sinuses. For screening, the radionuclide counting method was performed with pledgets introduced into the bilateral middle meatus and the space between the gingiva and the buccal mucosa. After the patient assumed three positions (supine for 5 hr, sitting for 3 hr, and prone for 30 min), the radionuclide ratio in each position was determined (Table 2). In the supine or sitting position, no significant difference was

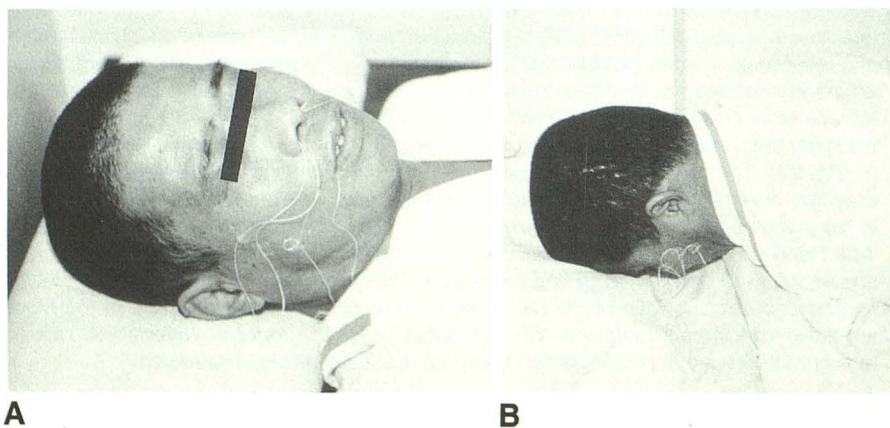


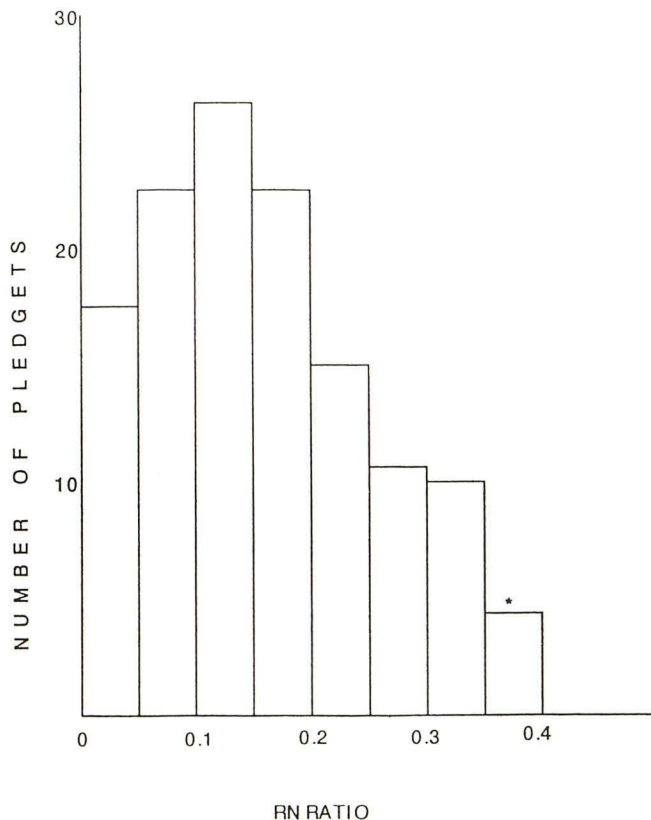
Fig. 2.—A and B, After intrathecal injection of ^{111}In -DTPA and intranasal insertion of cotton pledgets, patient was placed in supine position for 2 hr (A) and in sitting position for 3 hr thereafter. Cotton pledgets were then exchanged, and patient was placed in prone position for 30 min (B).

observed, and only the right middle meatus of the nose showed a significant increase in the radionuclide ratio for the prone position. Two weeks later, cotton pledgets were introduced into the seven standard regions for reexamination. After relatively free positions, varying from sitting to a flexed neck position for 3 hr following 2 hr of resting in the supine position, marked elevations of radionuclide ratios were observed in the right olfactory cleft, the sphenothmoid recess, and the middle meatus (Table 2). These findings suggested the presence of a fistula causing CSF rhinorrhea in the region extending from the right cribriform to the sphenoidal sinus. Concurrent radionuclide cisternography did not demonstrate CSF rhinorrhea. A

right frontal craniotomy was performed 1 year after admission. A small fistula found in the right cribriform plate was filled with bone wax and a muscle fragment; it was repaired with temporal fasciae. The surgical findings were consistent with the results of the radionuclide counting method. It was speculated that the CSF leaked through the cribriform plate into the right olfactory cleft, from which it flowed into the sphenothmoid recess and middle meatus owing to changes in the position of the head. This raised the radionuclide ratios. Postoperatively, rhinorrhea and meningitis did not recur, and the patient did well.

Discussion

Dural fistula due to head trauma is the most common cause of CSF rhinorrhea. The frequency of posttraumatic CSF rhinorrhea is 2% to 9% [7, 8]. In most cases, rhinorrhea appears within 48 hr after injury and disappears spontaneously 1 week to 6 months later. In some patients, the onset may be delayed several months to several years; onset in one case was 34 years after injury [8]. Spontaneous recovery is attributed to closure of the dural fistula as a result of cerebral adhesion or local inflammation. Meningitis may supervene, not only in the acute phase after trauma, but also in delayed CSF rhinorrhea or after spontaneous recovery; its occurrence rate in CSF rhinorrhea is 3% to 50% [7, 8]. Conservative therapy is recommended with the hope of spontaneous recovery; surgical repair should be considered for patients with recurrent



* Every ratio in this column is under 0.37.

Fig. 3.—Radionuclide (RN) counts in normal subjects.

TABLE 2: Radionuclide Ratios of Cotton Pledgets in Case 2

Area	Rhinorrhea Screening			Fistula Location ^a
	Supine	Sitting	Prone	
Middle meatus				
Right	0.201	0.102	25.552 ^b	1.897 ^b
Left	0.063	0.051	0.025	0.337
Sphenothmoid recess				
Right	—	—	—	13.184 ^b
Left	—	—	—	0.249
Olfactory cleft				
Right	—	—	—	72.964 ^b
Left	—	—	—	0.296
Control	0.016	0.015	0.003	0.013

^a Investigation of location of fistula (sitting position or neck flexion for 3 hr).

^b Radionuclide ratio > mean + 2 SD.

TABLE 1: Pre- and Postoperative Radionuclide Ratios of Cotton Pledgets in Case 1

Position/Area	Preoperative Ratio (Count ^a)		Postoperative Ratio	
	Right	Left	Right	Left
Supine for 2 hr + sitting for 3 hr				
Sphenothmoid recess	0.288 (334)	0.272 (316)	0.171	0.147
Middle meatus	0.337 (392)	0.289 (335)	0.134	0.028
Olfactory cleft	0.248 (289)	0.208 (242)	0.147	0.062
Control	0.040 (46)		0.032	
Prone for 30 min				
Sphenothmoid recess	0.143 (179)	0.548 ^b (689)	0.174	0.173
Middle meatus	0.203 (255)	0.563 ^b (708)	0.143	0.101
Olfactory cleft	0.338 (425)	0.223 (281)	0.128	0.108
Control	0.026 (32)		0.035	

^a 1 ml of blood = 1162 cpm (supine + sitting); 1 ml of blood = 1257 cpm (prone).

^b Radionuclide ratio > mean + 2 SD.

meningitis. For this reason, the presence and location of CSF rhinorrhea should be determined accurately.

Various methods of diagnosing CSF rhinorrhea have been proposed. Determination of the glucose level in the nasal discharge is impossible if the amount of discharge is too small, and normal nasal discharge is believed to be falsely positive in 45% to 75% of cases [1, 9]. Dyes and fluorescein usually are not very informative for the localization of the fistula and may even be dangerous [2, 10]. Plain films and detailed tomographic studies are frequently disappointing [1, 6]. Thus, conventional techniques pose problems of reliability, safety, and surgical usefulness.

Several reports [1–4] have emphasized the usefulness of the radionuclide counting method devised by Crow et al. [1] to determine the presence and location of CSF rhinorrhea. While these reports have described the radionuclide used, the procedure for the intrathecal injection of radionuclides, the sites for introduction of cotton pledgets, and the normal range for radionuclide counts, none have discussed the importance of changing the position of the patient, although this has been reported for radionuclide cisternographic imaging [6]. The diagnosis of CSF rhinorrhea was difficult when using the conventional methods in our two cases, but the radionuclide counting method, combined with the prone and neck-flexed positions, enabled us to determine simultaneously the presence of CSF rhinorrhea and the location of the fistula in the cranial base.

Radionuclide count values are subject not only to the amount of CSF rhinorrhea but also to the radionuclide present in the blood, the nasal discharge due to tracer activity, and the size or absorption rate of the pledgets. In normal individuals, the intrathecally injected nuclide may be absorbed and circulate in the blood and body secretions, so that quantitative comparison of nasal secretions with blood is necessary. For these reasons, we calculated the ratio of the radionuclide count in each removed pledget to that in the 1-ml blood sample collected simultaneously. According to Hiratsuka et al. [3], who analyzed 17 normal subjects, the normal radionuclide ratio is less than 0.3. We obtained radionuclide ratios of 128 pledgets from 11 normal subjects. The mean was 0.158; the standard deviation was 0.101. Therefore, we regarded values higher than 0.37 (mean + 2 SD) as significant. It was speculated preoperatively in our two cases that CSF rhinorrhea would be present at sites showing higher values.

McKusick et al. [5] examined 16 patients and concluded that their ratios did not exceed 1.3 in any subject (mean, 0.45; SD, 0.34). Since they did not exclude six patients with hydrocephalus, and because of the differences in the amount of radionuclide injected and the absorptive capacity of the pledgets, it is difficult to compare these results with ours.

We examined the radionuclide counts of 18 randomly selected pledgets exposed in vitro to radioactive blood collected from several patients in our study. The mean radionuclide ratio was 0.135 compared with the radionuclide count of the 1-ml blood sample; the standard deviation was 0.025. These data were not significantly different from those in the normal subjects mentioned above. Consequently, it was unlikely that nasal blood contamination in the pledgets elevated radionuclide ratios significantly (over 0.37), producing false-positive results. The relatively low standard deviation shows the uni-

formity of the pledgets. On the other hand, the mean ratio of 0.135 indicates our pledgets can absorb 0.135 ml of blood or other fluid, and are smaller than the ones used by McKusick et al. It is important to recognize that the absorptive capacity of the pledgets should be standardized in every center. To make the standard deviation smaller, we recommend the pledgets be accurately weighed before and after placement in the nasal cavity to identify the volume of fluid absorbed.

Since the sphenoid recess, olfactory cleft, and middle meatus, into which pledgets were introduced, are anatomically intranasal openings of the sphenoidal, ethmoidal, and frontal sinuses, respectively, it was assumed that the paranasal sinus that opened at the site for the pledget showing the highest radionuclide ratio corresponded to the site of the intracranial fistula [2].

On the basis of our findings, we believe that the radionuclide counting method is indicated in two instances: (1) when macroscopically obvious rhinorrhea is not identified by the conventional techniques, or CSF rhinorrhea cannot be localized, and (2) when there is no definite rhinorrhea but meningitis supervenes in a patient with a history of trauma, suggesting subclinical CSF rhinorrhea.

The therapeutic policy for CSF rhinorrhea, particularly the surgical indications, timing, and selection of procedures, is controversial, and no consensus has been reached [4]. This is because some patients apparently recover spontaneously from CSF rhinorrhea. However, it is possible that such cases include patients in whom meningitis occurs long after injury, as in case 1, and subclinical CSF rhinorrhea is detected by the radionuclide counting method. These cases require surgical treatment.

ACKNOWLEDGMENTS

We thank Yuzuru Masuda, Department of Otolaryngology; Hiro-yoshi Fujioka, for technical assistance; and Kyoko Takasuka, Lucia Griffin, and Julie Hipp for help in manuscript preparation.

REFERENCES

1. Crow HJ, Keogh C, Northfield DWC. The localization of cerebrospinal-fluid fistulae. *Lancet* 1956;271:325–327
2. Barrs DM, Kern EB. Use of intranasal pledgets for localization of cerebrospinal fluid rhinorrhea (notes on technique). *Rhinology* 1979;17:227–230
3. Hiratsuka H, Okada K, Nishimoto K, et al. Diagnostic value of radioisotope cisternography combined with intranasal pledgets in CSF rhinorrhea. *No To Shinkei* 1982;34:867–871
4. Jacobson I, Maran AG. Localization of cerebrospinal fluid rhinorrhea. *Arch Otolaryngol Head Neck Surg* 1971;93:79–80
5. McKusick KA, Malmud LS, Kordela PA, Wagner HN. Radionuclide cisternography: normal values for nasal secretion of intrathecally injected ^{111}In -DTPA. *J Nucl Med* 1973;14:933–934
6. Di Chiro G, Ommaya AK, Ashburn WL, Briner WH. Isotope cisternography in the diagnosis and follow-up of cerebrospinal fluid rhinorrhea. *J Neurosurg* 1968;28:522–529
7. MacGee EE, Cauthen JC, Brackett CE. Meningitis following acute traumatic cerebrospinal fluid fistula. *J Neurosurg* 1970;33:312–316
8. Russell T, Cummins BH. Cerebrospinal fluid rhinorrhea 34 years after trauma: a case report and review of the literature. *Neurosurgery* 1984;15:705–706
9. Ommaya AK. Cerebrospinal fluid fistulae. In: Wilkins RH, Rengachary SS, eds. *Neurosurgery*, vol. 2. New York: McGraw-Hill, 1985:1637–1647
10. Moseley JI, Carton CA, Stern WE. Spectrum of complications in the use of intrathecal fluorescein. *J Neurosurg* 1978;48:765–767