



Get Clarity On Generics

Cost-Effective CT & MRI Contrast Agents

**FRESENIUS
KABI**

[WATCH VIDEO](#)

AJNR

MR imaging of the postoperative lumbar spine: assessment with gadopentetate dimeglumine.

J S Ross, T J Masaryk, M Schrader, A Gentili, H Bohlman and M T Modic

AJNR Am J Neuroradiol 1990, 11 (4) 771-776

<http://www.ajnr.org/content/11/4/771>

This information is current as
of August 1, 2025.

MR Imaging of the Postoperative Lumbar Spine: Assessment with Gadopentetate Dimeglumine

Jeffrey S. Ross^{1,2}
 Thomas J. Masaryk^{1,2}
 Mauricio Schrader¹
 Amilcare Gentili¹
 Henry Bohlman³
 Michael T. Modic^{1,2}

This study defines the accuracy of gadopentetate-dimeglumine-enhanced MR imaging in patients with failed back surgery syndrome by comparing the imaging studies with surgical findings in a large patient population. From June 1988 to March 1989, 193 postoperative patients had MR imaging of the lumbar spine both with and without contrast administration. Of this group, 27 had repeat surgery at 31 levels: these patients comprise the study group. Postcontrast MR diagnoses were as follows: scar only ($n = 4$), disk only ($n = 13$), scar and disk ($n = 9$), and no aberrant epidural tissue ($n = 5$). Surgical diagnoses differed from the MR diagnoses in two patients at two levels. In one patient, disk was diagnosed on MR while osteophyte was present at surgery. In the other patient, scar only was diagnosed by MR but disk and scar were present at surgery. These data, when combined with the authors' previous experience, give pre- and postcontrast MR a 96% accuracy in differentiating scar from disk in 44 patients at 50 reoperated levels.

For patients 6 or more weeks past surgery, sagittal and axial T1-weighted MR imaging before and after administration of gadopentetate dimeglumine is an effective method of evaluating the postoperative lumbar spine.

AJNR 11:771-776, July/August 1990; *AJR* 155: October 1990

Our initial evaluation of the use of gadopentetate dimeglumine (formerly called Gd-DTPA) (Magnevist, Berlex Laboratories, Inc., Cedar Knolls, NJ) in 17 patients with failed back surgery syndrome demonstrated that the use of that contrast material allowed accurate differentiation of epidural scar from recurrent disk herniation [1]. Epidural scar tissue was seen to consistently and intensely enhance while disk material did not enhance on early postinjection T1-weighted images. However, while the results with contrast were excellent, the series was limited by a relatively small study group. It is the purpose of this paper to remedy that shortcoming by updating the series of postoperative patients who have been evaluated with gadopentetate dimeglumine and in whom there is surgical correlation stemming from repeat surgery.

Materials and Methods

From June 1988 to March 1989, 193 patients had MR imaging of the lumbar spine both with and without gadopentetate dimeglumine. Of these postoperative patients, 27 had a second operation, and they comprise the present study group. The group consisted of 16 men and 11 women, 28 to 77 years old (mean, 48). The time from previous surgery varied from 1 month to 17 years (mean, 4 years). Informed consent was obtained in all cases.

Examinations were performed on either a 1.0- or 1.5-T superconducting magnet (Magnetom; Siemens, Iselin, NJ) using a 12-cm diameter planar circular surface coil operating in the receive mode. Patients were examined with the following sequences before and after administration of 0.1 mmol/kg gadopentetate dimeglumine: sagittal T1-weighted spin-echo (SE), 400/17 (TR/TE) images, and axial T1-weighted SE 500-800/17 images. The imaging matrix was 256 × 256, with a 4-mm section thickness, 2-mm gap, and four excitations. An

Received September 23, 1989; revision requested December 8, 1989; revision received January 16, 1990; accepted January 17, 1990.

¹ Department of Radiology, University Hospitals of Cleveland/Case Western Reserve University School of Medicine, Cleveland, OH 44106.

² Present address: Division of Radiology, Cleveland Clinic Foundation, 9500 Euclid Ave., Cleveland, OH 44195. Address reprint requests to J. S. Ross.

³ Department of Orthopaedic Surgery, University Hospitals of Cleveland/Case Western Reserve University School of Medicine, Cleveland, OH 44106.

0195-6108/90/1104-0771

© American Society of Neuroradiology

IV line or heparin lock was placed prior to positioning the patient within the magnet, allowing contrast injection without patient motion. Postcontrast imaging was started immediately upon completion of the contrast injection. Postcontrast imaging was completed within 20 min after injection. Axial images were generally obtained before the sagittal sequences. Delayed T1-weighted images (more than 20 min after injection) and T2-weighted SE images were not obtained.

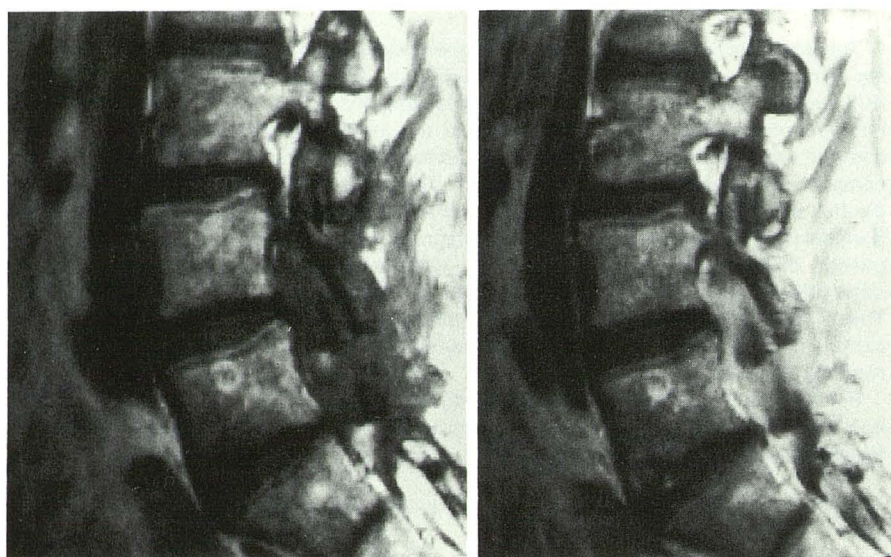
MR images were evaluated for the presence or absence of abnormal epidural soft tissue, which was then characterized by signal intensity, location, mass effect, and contiguity to the intervertebral disk. As in our previous study, the presence or absence of enhancement within abnormal epidural soft tissue on early postinjection images was the major diagnostic criterion used to distinguish scar from disk [1]. Abnormal epidural tissue that did not enhance was classified as disk whereas tissue that did enhance was classified as

scar. Central nonenhancing mass surrounded by enhancement was classified as disk surrounded by scar.

After MR imaging, all 27 patients were reexplored surgically at the site of the abnormality seen by MR. Mean time between MR imaging and repeat surgery was 27 days (range, 1–90). In all cases, the surgeon was aware of the preoperative MR findings. The surgical findings, such as location and nature of abnormal epidural tissues, were correlated with the preoperative MR interpretations.

Results

Postcontrast MR diagnoses for the 27 patients (31 levels) were as follows: scar only ($n = 4$) (Fig. 1), disk only ($n = 13$), scar and disk ($n = 9$) (Figs. 2–4), and no aberrant epidural



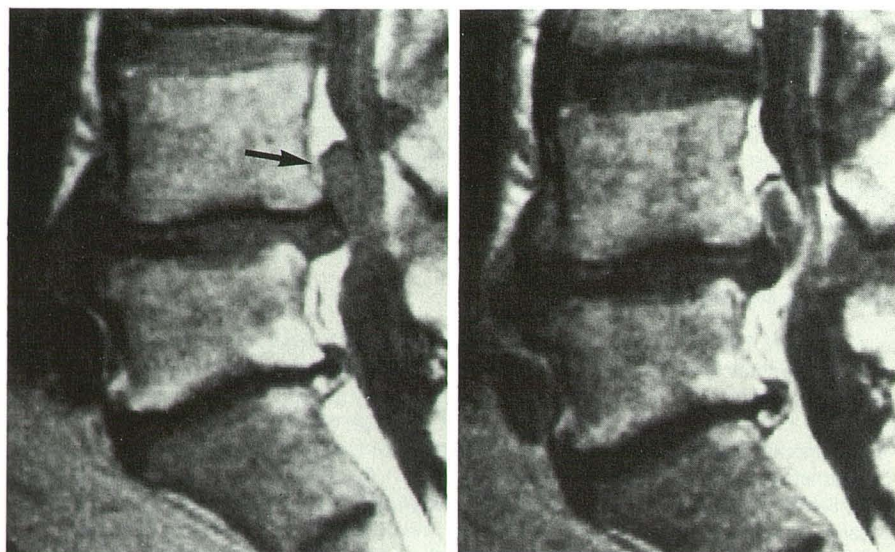
A

B

Fig. 1.—Epidural scar.

A, Sagittal T1-weighted (500/20) precontrast MR image shows a large amount of abnormal tissue within epidural space at L4–L5 through L5–S1.

B, Sagittal T1-weighted postcontrast MR image shows diffuse and intense enhancement throughout epidural tissue, consistent with scar.



A

B

Fig. 2.—A, Sagittal T1-weighted (500/20) precontrast MR image shows a well-defined, polypoid mass extending superiorly from L4–L5 disk space, typical of a free disk fragment (arrow).

B, Sagittal T1-weighted postcontrast MR image shows a faint rim of peripheral enhancement of disk fragment, consistent with a small amount of scar tissue. In this case, little additional diagnostic information is gained with the administration of contrast material.

Fig. 3.—A, Sagittal T1-weighted (500/20) pre-contrast MR image shows a more ill-defined soft-tissue mass anteriorly within epidural space at L5-S1 (arrow).

B, Sagittal T1-weighted postcontrast MR image shows enhancement of peripheral scar tissue, with a central nonenhancing herniation. The diagnosis is greatly aided by the enhancement pattern.

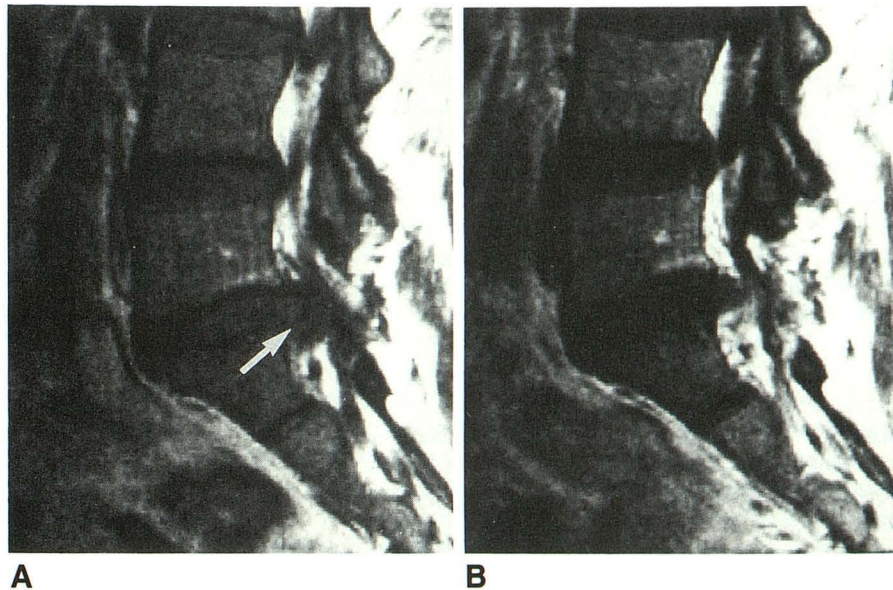


Fig. 4.—A, Sagittal T1-weighted (500/20) pre-contrast MR image shows a very ill defined anterior epidural soft-tissue mass at L4-L5 level (arrow), with slight mass effect upon the anterior thecal sac. Differentiation of scar from disk is not possible.

B, Sagittal T1-weighted postcontrast MR image clearly defines the central nonenhancing herniation, surrounded by enhancing scar tissue.

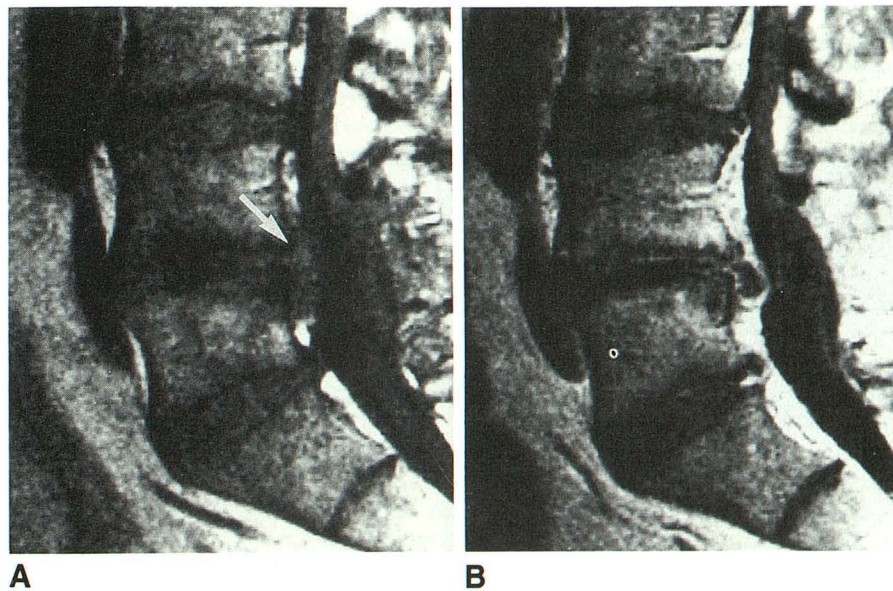
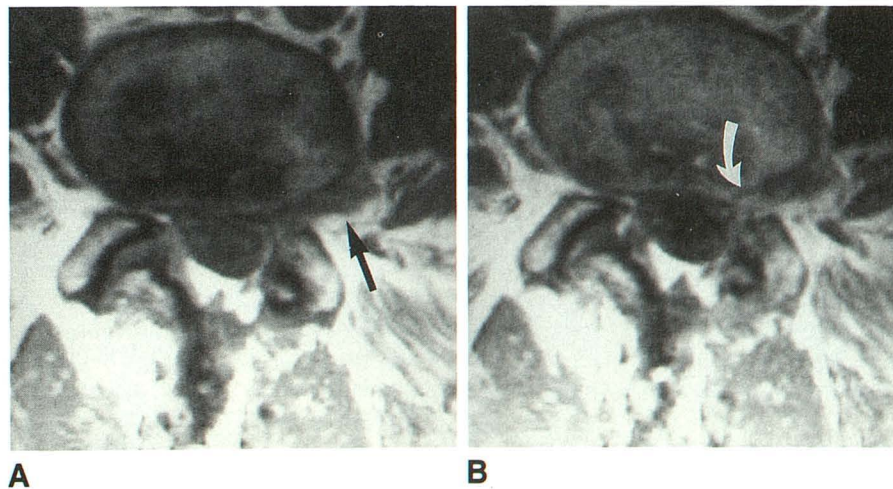


Fig. 5.—A, Axial T1-weighted (500/17) pre-contrast MR image at L4-L5 shows an apparent left lateral disk herniation (arrow).

B, After contrast administration, mass shows faint medial enhancement (arrow). At surgery, an osteophyte was found, but no disk material.



tissue ($n = 5$). Surgical diagnoses differed from the MR diagnoses in two patients at two levels. In one patient, a herniated disk was diagnosed on MR, but an osteophyte was present at surgery (Fig. 5). In the other patient, scar only was diagnosed by MR, but herniated disk and scar were present at surgery (Fig. 6). The patients with scar only or no aberrant epidural tissue had repeat surgery for posterior fusions, foraminal stenosis, or takedown of fusion nonunion. Scar tissue was explored in these cases to exclude disk material.

This series, combined with the 17 patients we reported previously [1], brings to 44 the total number of failed back surgery syndrome patients with surgical confirmation following MR with and without contrast, at 50 reoperated levels. Totals for the postcontrast diagnoses at the 50 levels include scar only ($n = 9$), disk only ($n = 15$), scar and disk ($n = 19$), and no aberrant tissue ($n = 7$). Contrast-enhanced MR was correct in 48 of 50 levels (96%) when correlated with surgical results.

At all nine levels with scar only, scar consistently enhanced early following injection. Scar tissue was contiguous with the disk space in four of the nine levels, and exhibited mass effect in four levels. No mass effect upon the thecal sac was present in the remainder. At none of the 15 levels with herniated disk only did the disk material exhibit early enhancement. Mass

effect from the disk material was seen at all 15 levels. In the patients with disk and scar, scar consistently enhanced in all 19 levels, while the more central disk material did not enhance in 18 of the 19 levels. Mass effect was present in all 19 levels.

Discussion

The differentiation of herniated disk material from epidural fibrosis (scar) is critical in postoperative patients who continue to have pain. Repeat surgery on only epidural scar tissue when no disk material is present leads to a poor surgical result [2, 3].

This study supports our initial conclusion that gadopentate-dimeglumine-enhanced MR imaging is an effective method of distinguishing recurrent disk herniation from epidural scar in 96% of cases [1]. Other investigators have confirmed the intense enhancement of scar with gadopentate dimeglumine [4].

Unenhanced MR imaging has been reported to have an accuracy comparable to enhanced CT [1, 5]. More recently, Sotiropoulos et al. [6] used unenhanced MR to correctly predict scar vs disk in 11 of 14 levels based on signal intensity. Hochhauser et al. [7] suggested that configuration and margination were also important determinants for scar vs disk. In

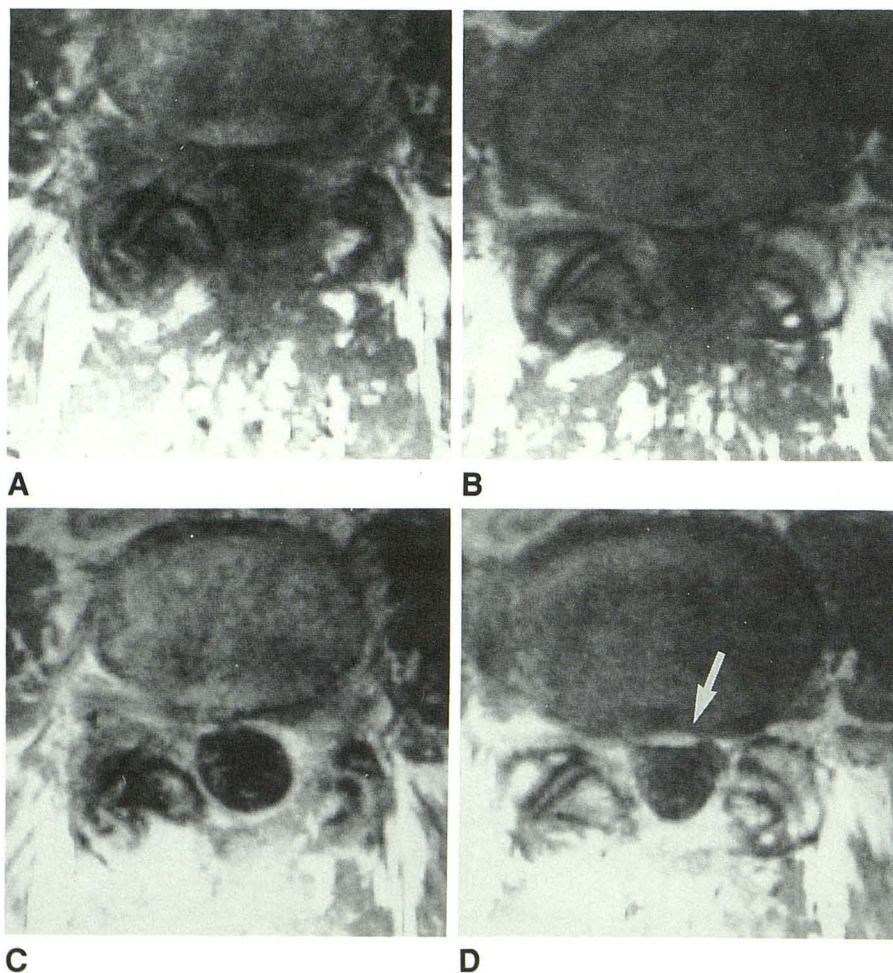


Fig. 6.—A and B, Axial T1-weighted (500/17) precontrast MR images show extensive epidural soft tissue circumferentially around the thecal sac, with a bulging intervertebral disk.

C and D, Images obtained within 20 min after contrast injection show diffuse enhancement of epidural soft tissue consistent with scar. Enhancement of anulus is also present (arrow in D). At surgery, there was extensive scar tissue, but an anterior right-sided herniated disk was also present.

their study, preoperative MR findings agreed with surgical findings in 13 of 17 patients in whom recurrent herniations had a smooth, polypoid configuration and scar had an irregular, unsharp margination. These investigators also noted a hypointense rim outlining the herniations, which is in agreement with our findings on T2-weighted images [1]. This hypointense rim may represent the combination of posterior longitudinal ligament and outer anular fibers surrounding the herniated disk material. However, unenhanced MR suffers from the necessity of having T2-weighted images with poor signal-to-noise and long acquisition times. Additionally, the signal-intensity changes associated with epidural scar may be subtle on T2-weighted images. In contradistinction, scar enhancement with gadopentetate dimeglumine is intense and generally unmistakable.

In our series, the preoperative MR diagnosis was incorrect in two cases. In one case, a low signal intensity extradural lesion was called disk when only osteophyte was found at surgery. The nonspecificity of MR in the distinction of hard or soft disk versus osteophyte has been recognized [8]. In the second case, scar only was diagnosed by MR, but disk and scar were present at surgery. We do not know the cause for the misdiagnosis in this case, but factors to be considered include partial volume averaging of disk material with surrounding enhancing scar and early enhancement of small fragments of disk material surrounded by vascularized scar tissue. Epidural scar has the ability to absorb or "digest" disk material, and this response is most intense in the prolapsed portion of the disk [9]. It has been hypothesized that this disk absorption accounts for the relief of symptoms with time. Ingrowth of vascularized granulation tissue into the herniated disk margin is common, and considered by some pathologists to be a reliable marker that disk prolapse has occurred [10]. This ingrowth of scar tissue into the disk material could cause enhancement of the disk and a false-negative diagnosis.

Within the first 6 weeks following surgery, the use of contrast material in patients, and the use of MR in general, remains questionable. Previous studies have shown dramatic changes in the epidural space immediately after surgery that may mimic the signal intensity changes of the preoperative disk herniation. These changes usually resolve by 6 weeks after surgery, at which time the thecal sac and anterior epidural space have returned to their normal morphology without mass effect upon the thecal sac [11]. We have insufficient numbers in this series to make a firm statement about the use of contrast in this subgroup.

Several points concerning the technique deserve further comment. First, obtaining images in the sagittal and axial planes before and after contrast administration is extremely useful in establishing a diagnosis. Partial volume effects that are present in one plane may not occur in the other. The sagittal view of the foramen after contrast administration allows distinction of postforaminotomy scar from new foraminal herniation/osteophyte. Second, it is important for the patient to maintain the same position before and after contrast administration so that the images may be compared effectively. For this reason, an IV line is placed with a long extension tube (or a heparin lock) to allow injection of contrast while the patient is still within the magnet. Third, scanning

should begin immediately after injection of contrast to avoid late enhancement of disk material. Generally, the axial T1-weighted images are obtained first. However, both imaging planes are useful in the evaluation of the extradural disease. There has been no gross disparity in the appearance of epidural disease on the postcontrast sagittal and axial images, despite the differences in elapsed time since the injection (approximately 10 min). Fourth, while T2-weighted images are up to 89% accurate in distinguishing scar from disk material, contrast-enhanced MR is even more accurate [1]. We do not obtain T2-weighted spin-echo images in the postoperative population unless there is a question of disk space infection or epidural abscess.

In our population, anterior epidural scar consistently enhanced, regardless of the amount of time that had elapsed between imaging and surgery. There are a couple of possibilities why this occurs. It may not mean that scar tissue that enhances in a patient 17 years after discectomy is, in fact, 17 years old. We have observed a mixture of scar tissue ages in these patients, varying from granulation tissue to cicatrized "mature" scar. It may be more likely that the degenerative disease process that caused these individuals to again seek treatment (and subsequent imaging) has incited new scar tissue formation, which enhances. Scar tissue can be intimately associated with disk herniations in the previously unoperated patient, and will enhance in much the same manner as scar tissue in the postoperative patient [12]. Clearly, the scar tissue present in these postoperative patients is not solely due to the operative trauma, but is also in some measure generated as the body's response to the herniated material, if a herniation is present. One other concern regarding epidural scar enhancement is whether anterior epidural scar can be considered equivalent (from an imaging or physiologic standpoint) to other areas of epidural scar formation, such as posterior to the thecal sac. We have shown that a simple lumbar laminectomy in dogs will produce abundant posterior epidural scar tissue, but this scar tissue will not follow the time course of enhancement of anterior epidural scar. Posterior epidural scar tends to show a rapid decline in the amount of enhancement present over a period of 4 months, unlike the consistent enhancement seen in anterior epidural scar [13]. The reason for this difference is unknown, but could relate to the close physical relationship of anterior epidural scar to the intervertebral disk, and to the process of disk degeneration.

Epidural scar, and not just disk material, is capable of showing mass effect upon the thecal sac. The enhancement characteristics, in our experience, are more diagnostically useful than the presence of mass effect from an ill-defined anterior epidural soft tissue in distinguishing scar from disk material. Retraction of the thecal sac toward aberrant epidural soft tissue can be a helpful sign of scar when present. Obviously, no morphologic sign should be ignored. However, the presence or absence of mass effect should be a secondary consideration when compared with presence or absence of enhancement.

In patients 6 or more weeks past surgery, gadopentetate-dimeglumine-enhanced MR is an effective method of evaluating the postoperative lumbar spine. Following an MR study,

unenhanced CT might be an appropriate second study in those cases in which there is a question of disk material versus osteophyte. In this manner, invasive myelography may be eliminated from the workup of this difficult postoperative group.

REFERENCES

1. Hueftle MG, Modic MT, Ross JS, et al. Lumbar spine: postoperative MR imaging with Gd-DTPA. *Radiology* **1988**;167:817-824
2. Finnegan WJ, Fenlin JM, Marvel JP, Nardini RJ, Rothman RH. Results of surgical intervention in the symptomatic multiply-operated back patient. *J Bone Joint Surg [Am]* **1979**;61:1077-1082
3. Law JD, Lehman RAW, Kirsch WM. Reoperation after lumbar intervertebral disk surgery. *J Neurosurg* **1978**;48:259-263
4. Breger RK, Williams AL, Daniels DL, et al. Contrast enhancement in spinal MR imaging. *AJNR* **1989**;10:633-637
5. Bundschuh CV, Modic MT, Ross JS, Masaryk TJ, Bohlman H. Epidural fibrosis and recurrent disk herniation in the lumbar spine: MR imaging assessment. *AJNR* **1988**;9:169-178
6. Sotiropoulos S, Chafetz NI, Lang P, et al. Differentiation between postoperative scar and recurrent disk herniation: prospective comparison of MR, CT, and contrast-enhanced CT. *AJNR* **1989**;10:639-643
7. Hochhauser L, Kieffer SA, Cacayorin ED, Petro GR, Teller WF. Recurrent postdiscectomy low back pain: MR-surgical correlation. *AJNR* **1988**;9:769-774
8. Modic MT, Masaryk TJ, Ross JS, Carter JR. Imaging of degenerative disk disease. *Radiology* **1988**;168:177-186
9. Lindblom K, Hultqvist G. Absorption of protruded disk tissue. *J Bone Joint Surg* **1950**;32:557-560
10. Weidner N, Rice DT. Intervertebral disk material: criteria for determining probable prolapse. *Hum Pathol* **1988**;19:406-410
11. Ross JS, Masaryk TJ, Modic MT, et al. Lumbar spine: postoperative assessment with surface-coil MR imaging. *Radiology* **1987**;164:851-860
12. Ross JS, Modic MT, Masaryk TJ, Carter J, Marcus RE, Bohlman H. Assessment of extradural degenerative disease with Gd-DTPA-enhanced MR imaging: correlation with surgical and pathologic findings. *AJNR* **1989**;10:1243-1249
13. Ross JS, Blaser S, Masaryk TJ, et al. Gd-DTPA enhancement of posterior epidural scar: an experimental model. *AJNR* **1989**;10:1083-1088