



## Discover Generics

Cost-Effective CT & MRI Contrast Agents



FRESENIUS  
KABI

WATCH VIDEO

# AJNR

## **Meningeal fibrosis appearing shortly after ventricular shunting.**

D S Martin, E E Awwad and T Pittman

*AJNR Am J Neuroradiol* 1990, 11 (3) 617-618

<http://www.ajnr.org/content/11/3/617.citation>

This information is current as  
of June 21, 2025.

## Letters

### Meningeal Fibrosis Appearing Shortly After Ventricular Shunting

Destian et al. [1] recently reported the CT and MR findings of meningeal fibrosis as a distinct sequela of chronic ventricular shunting. They stated that they were unable to determine when the fibrosis developed or over what period of time because their patients did not have interval CT or MR studies. We recently encountered a case in which the changes occurred over a span of 6 weeks.

An 11-year-old boy was admitted with signs and symptoms of acute hydrocephalus. MR images were obtained at 0.35 T with T1-weighted (SE 700/30/2), intermediate (SE 2000/30/1), and T2-weighted (SE 2000/75/1) sequences (Fig. 1A). That day, the patient had placement of an intraventricular shunt. Six weeks later, a follow-up study was performed in which IV gadolinium-enhanced T1-

weighted images were obtained in addition to the previous sequences (Figs. 1B–1E).

Although we do not have surgical proof, our images fulfill the criteria described by Destian et al. and suggest that meningeal fibrosis may occur as early as 6 weeks after placement of a shunt.

David S. Martin

Eric E. Awwad

Tom Pittman

St. Louis University Medical Center

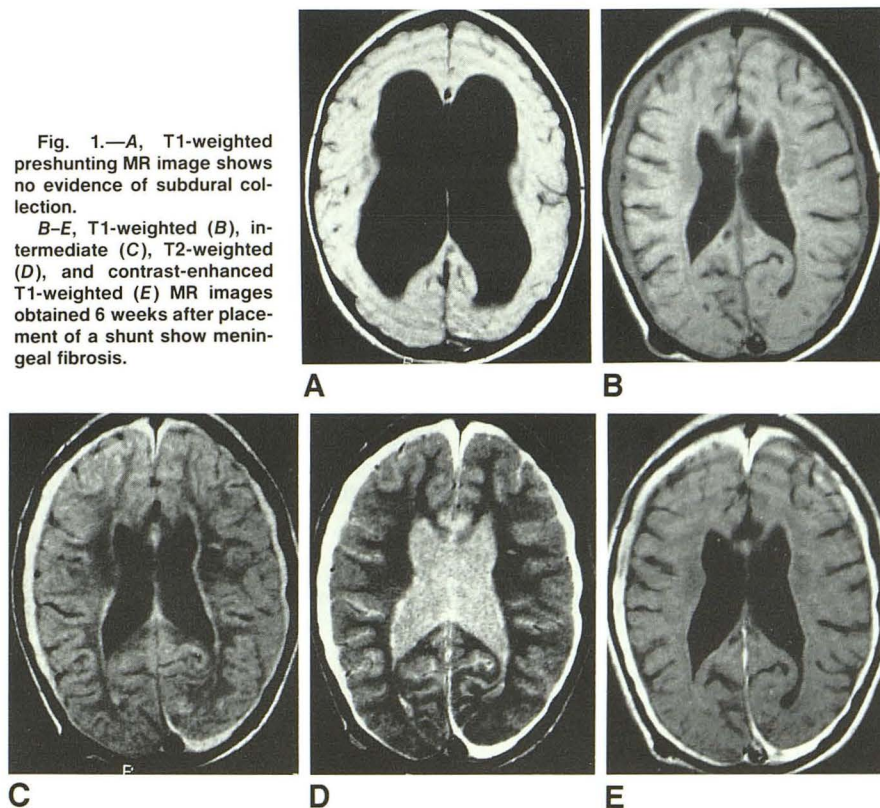
St. Louis, MO 63110-0250

#### REFERENCE

1. Destian S, Heier LA, Zimmerman RD, Morgello S, Deck MDF. Differentiation between meningeal fibrosis and chronic subdural hematoma after ventricular shunting: value of enhanced CT and MR scans. *AJNR* 1989;10:1021–1026

Fig. 1.—A, T1-weighted preshunting MR image shows no evidence of subdural collection.

B–E, T1-weighted (B), intermediate (C), T2-weighted (D), and contrast-enhanced T1-weighted (E) MR images obtained 6 weeks after placement of a shunt show meningeal fibrosis.



*Reply*

In reply to the letter from Drs. Martin, Awwad, and Pittman, we can only agree with their conclusion that meningeal fibrosis may occur as early as 6 weeks after a shunt. Alternatively, this subdural enhancement may be due to the neovascularity found in the formation of a membrane that occurs in a subdural hematoma before the permanent meningeal fibrosis develops. Since our initial observations, we have seen subdural enhancement develop 5 days after shunting, and biopsy of the membrane on day 6 showed "organizing hemorrhage with abundant granulation tissue" [1]. Although we do not yet have long-term follow-up on this particular case, we have seen other cases of postshunt subdural enhancement that have resolved. Presumably, evolution of subdural hematoma is a spectrum of changes, with enhancement initially being reversible and representative of

granulation tissue. A follow-up examination in the case of Martin et al. would be interesting to see if the subdural enhancement has resolved consistent with granulation tissue, or if permanent meningeal fibrosis has developed.

Linda A. Heier  
Robert D. Zimmerman  
Michael D. F. Deck  
*The New York Hospital-Cornell Medical Center*  
New York, NY 10021

## REFERENCE

1. Jahre C, Russell E, Haimes A, Zimmerman RD, Deck MDF. Diffuse paratubular enhancement on MR. Presented at the annual meeting of the Radiological Society of North America, Chicago, November 1989

Letters are published at the discretion of the Editor and are subject to editing.  
Letters to the Editor must not be more than two *double-spaced*, typewritten pages. One or two figures may be included. Abbreviations should not be used.  
Material being submitted or published elsewhere should not be duplicated in letters, and authors of letters must disclose financial associations or other possible conflicts of interest.  
Letters concerning a paper published in the *AJNR* will be sent to the authors of the paper for a reply to be published in the same issue. Opinions expressed in the Letters to the Editor do not necessarily reflect the opinions of the Editor.