



Discover Generics

Cost-Effective CT & MRI Contrast Agents



WATCH VIDEO

AJNR

Posterior spinal tuberculosis: a case report.

R L Ragland, I F Abdelwahab, B Braffman and D S Moss

AJNR Am J Neuroradiol 1990, 11 (3) 612-613

<http://www.ajnr.org/content/11/3/612.citation>

This information is current as
of June 5, 2025.

Posterior Spinal Tuberculosis: A Case Report

Ronald L. Ragland,¹ Ibrahim Fikry Abdelwahab,² Barbara Braffman,² and David S. Moss¹

Posterior spinal tuberculosis (PST) is a form of skeletal tuberculosis that selectively involves the vertebral arch. Since typical tuberculous spondylitis spreads to involve the adjacent disk spaces while PST does not, the radiographic appearance of PST often mimics skeletal neoplasm.

Although PST has been reported in developing countries, particularly India and Pakistan, and among nonwhite immigrants in the United Kingdom, it is rarely found in the United States. As a result, there is limited information about this entity in the American medical literature. This case is significant because the patient was born in the United States and had never traveled abroad.

Case Report

A 23-year-old black native American man was admitted for evaluation of recurrent back pain of 6 months duration and progressive stiffness and numbness of both legs and feet, causing difficulty in rising and in climbing stairs. During this period he lost 15 pounds, and 2 weeks prior to admission he experienced difficulty in urination.

Physical examination revealed muscle wasting, decreased tonicity and weakness of the lower extremities accompanied by diminished vibratory and position sense, saddle anesthesia, and decreased rectal tone. Laboratory studies were remarkable for an erythrocyte sedimentation rate (ESR) of 41 and a positive PPD with a normal chest radiograph. The CSF revealed a high protein of 1041 mg/dl. Plain radiographs, panmyelography, and CT-myelography revealed destruction of the left lamina and spinous process of L1 with an intraspinal soft-tissue component. The soft-tissue component was inseparable from the thecal sac and caused complete myelographic block at L1 (Figs. 1–3). The patient underwent emergent laminectomy of T11, T12, and L1; the soft-tissue mass that encased the dura was successfully debulked. Histopathology revealed caseating granulomata and multinucleated giant cells (Fig. 4). Cultures taken at the time of surgery were positive for *Mycobacterium tuberculosis*. Postoperatively, the patient regained normal neurologic function.

Discussion

Tuberculosis remains a major cause of bone and joint infection in developing countries and among nonwhite immigrants [1]. In the United States, nonwhite men make up the majority of the 22,000 cases reported annually. Vertebral

lesions are the predominant site of skeletal tuberculosis and account for 50% of lesions [1, 2–4].

The radiographic features of typical tuberculous spondylitis include narrowing of the intervertebral disk spaces and destruction of the contiguous vertebral bodies. The exact incidence of neural arch or PST is not known, but is variously reported in the range of 2–10% [5–8]. Ur-Rahman in 1980 [5] reported five cases of PST that he collected over 10 years (1969–1979). He emphasized that in these cases the adjacent vertebral bodies and disk spaces were spared. Further, he stated, "The author is unaware of any previous report of the tuberculous process affecting the neural arch only, with complete sparing of the vertebral bodies and the intervertebral disc" [5]. Later, Babhulkar et al. in 1984 [6] reported 228 cases of spinal tuberculosis: 206 had classical Pott disease and 22 patients had PST. The incidence of PST in this series was 10%. Conversely, Tuli et al. [7], in an earlier series of 240 cases of tuberculosis of the spine, found only one case of PST. Kumar in 1985 [8] reported 21 cases of PST and estimated an incidence of less than 2% in nonendemic areas and between 5 and 10% in endemic areas. We suspect that in the series in which the incidence of PST was high, posterior vertebral body tuberculosis has also been included. As a result, the reported incidence of PST was higher than in the series in which tuberculosis was strictly localized to the neural arch. We believe, as does Kumar, that PST is uncommon and that its incidence is less than 2%.

The reason tuberculosis may selectively affect the neural arch and spare the vertebral body and disk space is unknown. The most common site of involvement of PST is the pedicle. In Kumar's series, the pedicle was involved in 12 cases. The pedicles were the site of involvement in 10 patients reported by Bell and Cockshott [9].

The clinical implications of PST are quite serious. When associated with intraspinal granulomata, the potential for disability is great. As in this case, patients usually present with signs and symptoms of spinal cord and/or cauda equina compression. In Kumar's series most patients showed motor deficits and later a sensory counterpart. In the current case, the patient's symptoms were referable to thoracic myeloradiculopathy.

Received June 20, 1989; revision requested August 7, 1989; revision received August 27, 1989; accepted September 7, 1989.

¹ Department of Radiology, University of Massachusetts Medical Center, 55 Lake Ave. No., Worcester, MA 01655. Address reprint requests to R. L. Ragland.

² The Mount Sinai Medical Center, CUNY, New York, NY 10029.

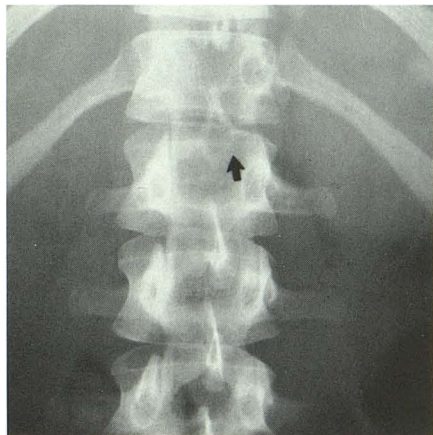
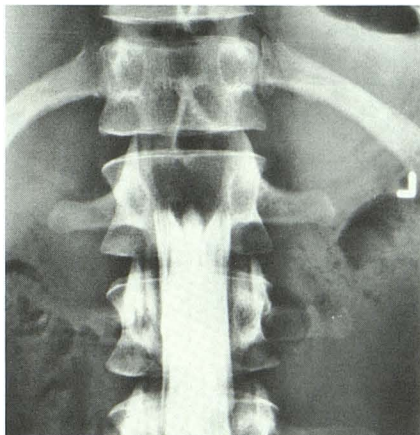
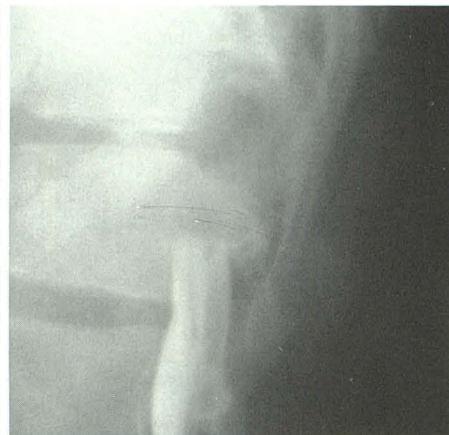

Fig. 1.—Anteroposterior view of the lumbar spine. Note indistinct eroded cortex of spinous process and left lamina of L1 (arrow). The adjacent disk spaces and articular margins of L1 are intact.



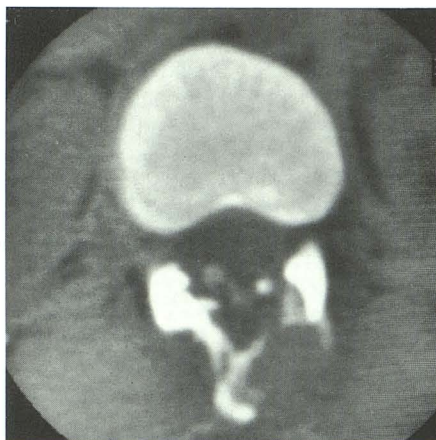A



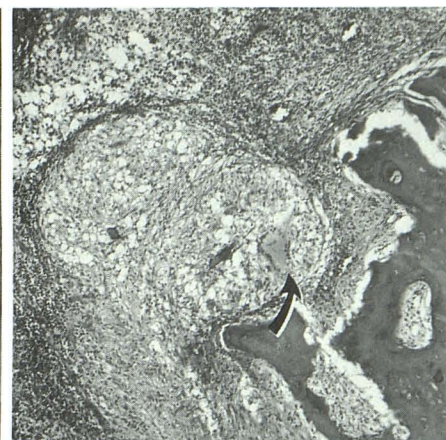
B

Fig. 2.—A, Anteroposterior view of lumbar myelography with patient in Trendelenburg position. B, Lateral view of lumbar myelography. These views demonstrate complete block at the lower margin of L1 with widening of the contrast column in the anteroposterior projection because of the compressive posterior epidural lesion.

Fig. 3.—CT scan of T12 reveals destruction of left lamina and spinous process. The intraspinal soft-tissue component compresses the thecal sac causing complete blockage. A few drop-lets of contrast material are noted in the compressed thecal sac.



3



4

Fig. 4.—Histopathologic section (100x) shows intertrabecular spaces filled by confluent necrotizing caseating granulomata. A prominent Langhans' giant cell is noted (arrow).

We emphasize the importance of considering this unusual and poorly understood form of spinal tuberculosis when evaluating patients with neural arch destructive lesions. Further, we postulate that the increased number of Asian-American immigrants might well result in an increase in the number of cases of PST. The differentiation of such infectious/inflammatory lesions from neoplasm is difficult and, at this point, rests most appropriately with the pathologist.

REFERENCES

1. Chapman M, Murray RO, Stoker DJ. Tuberculosis of the bone and joints. *Semin Roentgenol* 1979;24:266-282
2. Jacobs P. Osteoarticular tuberculosis in colored immigrants. A radiological study. *Clin Radiol* 1964;15:59-69
3. Goldblatt M, Cremin BJ. Osteoarticular tuberculosis, its presentation in colored races. *Clin Radiol* 1978;29:669-688
4. Davidson PT, Horowitz I. Skeletal tuberculosis. A review with patient presentation and discussion. *Am J Med* 1970;78:77-84
5. Naim-Ur-Rahman. Atypical forms of spinal tuberculosis. *J Bone Joint Surg* 1980;62B:162-165
6. Babhulkar SS, Tayade WB, Babhulkar SK. Atypical spinal tuberculosis. *J Bone Joint Surg* 1984;66B:239-242
7. Tuli SM, Srivastava TP, Varma BP, Sinha GP. Tuberculosis of the spine. *Acta Orthop Scand* 1967;38:445-458
8. Kumar K. Clinical study and classification of posterior tuberculosis. *Int Orthop* 1985;9:147-152
9. Bell D, Cockshott WP. Tuberculosis of the vertebral pedicles. *Radiology* 1971;99:43-48