



## Discover Generics

Cost-Effective CT & MRI Contrast Agents



FRESENIUS  
KABI

WATCH VIDEO

# AJNR

## Cervical Spinal Cord Injury After Traumatic Breech Delivery

Mauricio Castillo, Robert M. Quencer and Barth A. Green

*AJNR Am J Neuroradiol* 1989, 10 (5 suppl) S99

[http://www.ajnr.org/content/10/5\\_suppl/S99.citation](http://www.ajnr.org/content/10/5_suppl/S99.citation)

This information is current as  
of June 7, 2025.

## Cervical Spinal Cord Injury After Traumatic Breech Delivery

The pathologic findings of injury to the cervical spinal cord resulting from traumatic breech delivery have been reported [1]. To our knowledge, the imaging of such injuries has not been described. We report the MR findings seen in the cervical spinal cord of two young quadriplegic children each of whom had a difficult breech birth.

### Case Reports

#### Case 1

A 5-year-old girl whose birth had involved a difficult breech delivery presented with a history of complete quadriplegia since birth. There were complete sensory and motor deficits below C7. MR study showed only marked atrophy of the spinal cord from C7 to T3 (Fig. 1). No fractures or dislocations were noted.

#### Case 2

A 5-year-old girl whose birth had involved a traumatic breech delivery presented with complete quadriplegia and recurrent urinary tract infections since birth. There were complete sensory and motor deficits below C8. MR study showed only marked atrophy of the spinal cord at T1 and T2 (Fig. 2); linear areas of isointense signal within the thecal sac, representing scarring and adhesions, were seen.

### Discussion

The pathologic findings after injury to the cervical spinal cord caused by traumatic breech delivery have been recognized for more

than a century [2]. Vascular injury to the cord results from hyperextension of the head and longitudinal stretching of the cord. The level of the cord most susceptible to such trauma is the cervicothoracic junction because of its unique circulation. Superiorly, the anterior spinal artery (ASA) receives blood from the vertebral and radicular arteries and perfuses the cord in a caudad direction [3, 4]. Inferiorly, the ASA is supplied by the thoracic intercostal and lumbar arteries and gives rise to cephalad blood flow [4]. The posterior spinal arteries (PSA) receive blood superiorly from the vertebral arteries and/or the posterior inferior cerebellar arteries [3]. The thoracic and lumbar portions of the PSA are supplied by branches arising from the ASA. Therefore, ventrally and dorsally a watershed area exists at the cervicothoracic spinal cord where perfusion depends on the converging caudad and cephalad blood flow through the cervical and thoracic portions of the ASA and the PSA.

Yates [5] demonstrated that significant narrowing of the vertebral arteries occurs after traumatic breech delivery and suggested that this hemodynamic abnormality could account for the changes seen in the spinal cords of these injured neonates. Transient or permanent decrease in blood flow leading to infarction at the cervicothoracic region may occur when severe traction is applied to the fetal head during breech delivery. Although marked traction of the head is required to cause spinal cord injury [2], less traction may be required if the fetal muscle tone is reduced because of decreased blood flow after prolapse and compensation of the umbilical cord, an event that is not rare during breech deliveries [6]. Pathologic examination of such injured spinal cords shows an atrophic cord almost always in the low cervical or high thoracic regions adhered to the meninges [1]. These findings are in accordance with the MR findings [7] noted in our patients, namely severe cord atrophy in the lower cervical and upper thoracic regions. In addition, Case 2 showed probable scarring of the meninges posterior to the injured cord. Knowledge of these MR findings may be helpful in establishing the etiology of quadriplegia in those patients who have no evidence of spinal fractures or subluxations and in whom a history of traumatic breech delivery is uncertain.

Mauricio Castillo  
Robert M. Quencer  
Barth A. Green  
University of Miami School of Medicine  
Jackson Memorial Medical Center  
Miami, FL 33101

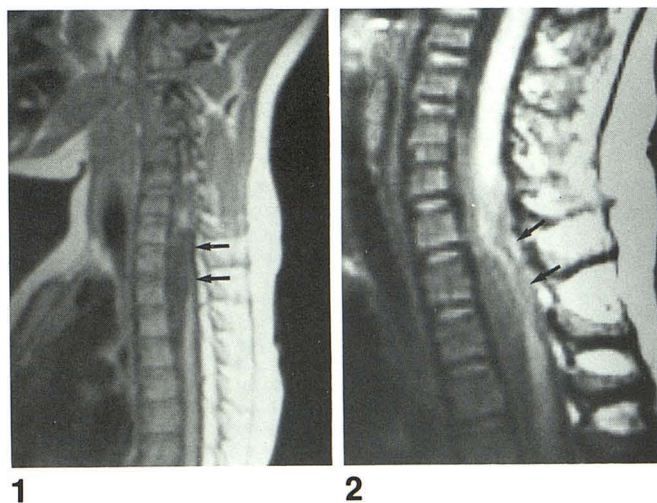


Fig. 1.—Case 1: Sagittal MR image (700/20; 0.5 T) shows marked atrophy of cord (arrows) extending from C7 to T3. Thoracic spinal cord is normal. No fractures or subluxations are present.

Fig. 2.—Case 2: Sagittal magnified MR image (700/20; 1.5 T) shows severe atrophy of cervical spinal cord at T1 and T2. Linear areas of isointense signal intensity in thecal sac (arrows) posterior to region of cord atrophy probably represent scars. No fractures or subluxations are present.

### REFERENCES

1. Byers KK. Spinal cord injuries during birth. *Develop Med Child Neurol* 1975;17:103-110
2. Parrot J. Note sur un cas de rupture de la moelle chez un nouveau-né par suite des manoeuvres pendant l'accouchement. *Bull Mem Soc Med Paris* 1869;6:38-42
3. Bolton B. The blood supply of the human spinal cord. *J Neurol Neurosurg Psychiatry* 1939;2:137-148
4. DiChiro G, Fried LC. Blood flow currents in spinal cord arteries. *Neurology* 1971;21:1088-1096
5. Yates PO. Birth trauma to the vertebral arteries. *Arch Dis Child* 1959;34:436-440
6. DeSouza SW, Davis JA. Spinal cord damage in a newborn infant. *Arch Dis Child* 1974;49:70-72
7. Mathis JM, Wilson JT, Bernard JW, Zelenik ME. MR imaging of spinal cord avulsion. *AJNR* 1988;9:1232-1233