



Providing Choice & Value

Generic CT and MRI Contrast Agents



**FRESENIUS
KABI**

CONTACT REP

AJNR

MR Imaging of Birth-Related Brachial Plexus Avulsion

Mark J. Popovich, Frank C. Taylor and Edward Helmer

AJNR Am J Neuroradiol 1989, 10 (5 suppl) S98

http://www.ajnr.org/content/10/5_suppl/S98.citation

This information is current as
of July 13, 2025.

MR Imaging of Birth-Related Brachial Plexus Avulsion

Imaging of the brachial plexus in infants and young children with birth-related brachial palsy may become more frequent in view of recent renewed interest in the surgical repair of these injuries [1]. The usefulness of MR for imaging the brachial plexus has been described recently [2, 3]. MR may provide an alternative, noninvasive means of studying patients with obstetric palsy. To our knowledge, this is the first case report describing a birth-related brachial plexus injury shown by MR.

Case Report

A full-term female neonate (large for gestational age) was born after a difficult delivery that was complicated by shoulder dystocia. Bruising was noted over the left upper extremity, and flaccid paralysis of the left arm was observed during the first day of life. Radiographs of the left shoulder were normal. A chest radiograph showed an elevated left hemidiaphragm. It was concluded that a stretch injury of the left brachial plexus had occurred.

Some improvement did occur with conservative treatment; nevertheless, significant residual impairment remained at 8 months of age. An electromyographic (EMG) study at that time showed partial destruction of the left brachial plexus. MR images were obtained to assess the possibility of surgical repair.

Axial gradient-echo (narrow flip-angle), sagittal, and coronal spin-echo images were obtained, using a 0.35-T superconductive system (Fig. 1). Surgical repair was not considered possible in view of the MR findings, and conservative treatment was continued.

Discussion

The incidence of birth-related brachial plexus injuries has diminished significantly with improved obstetric technique since the initial description of this disorder by Smellie in 1764 (cited by Leffert [4]); a 1986 study [5] reported an incidence of 0.50 per 1000 live births.

These injuries are the result of supraclavicular traction of the brachial plexus during delivery. Predisposing factors include difficult delivery, breech presentation, and increased birth weight.

Recently, there has been renewed interest in the surgical repair of brachial plexus injuries [1]. Because surgery is generally recommended in the first year of life, early diagnosis is important. Radiology plays a role in confirming the anatomic abnormalities suggested by clinical and EMG findings.

Before MR imaging was introduced, cervical myelography and/or CT after intrathecal contrast injection were the best methods to radiographically evaluate brachial plexus injuries. In 1947, Murphey et al. [6] described traumatic meningoceles shown by cervical myelography as representative of proximal nerve root avulsion. The risks associated with conventional myelography or CT, however, especially in an infant or a young child, are a significant drawback to these techniques.

Two recent articles have demonstrated the usefulness of MR in evaluating the brachial plexus after trauma [2, 3]; one of these [3] reported MR of traumatic meningocele. We believe our case is the first in which MR shows birth-related traumatic meningocele in a young child. In our case and that of Rapoport et al. [3], MR showed a high-intensity extraarachnoid collection of CSF around a lower cervical nerve root. This corresponds to the myelographic sign of proximal nerve root avulsion.

Our report suggests that MR may provide an accurate, noninvasive means of evaluating infants and young children with birth-related brachial palsy. Further investigation will refine our understanding of the MR findings related to brachial plexus injuries and the role of MR in studying those patients in whom surgical repair is contemplated.

Mark J. Popovich

Frank C. Taylor

Edward Helmer

Kaiser Foundation Hospital
Los Angeles, CA 90027

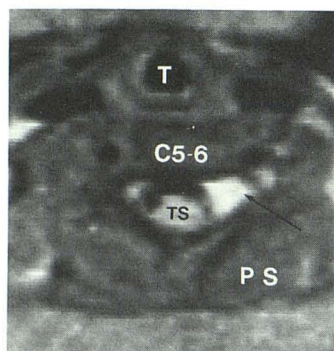


Fig. 1.—Traumatic meningocele. 5-mm-thick axial gradient-echo image (1000/20, flip angle 28°) at C5–C6 level; cervical coil was used. A high-intensity extraarachnoid collection of CSF is seen around left C6 nerve root (arrow). T = trachea, C5–6 = C5–C6 disk space, TS = thecal sac, PS = paraspinal muscles.

REFERENCES

1. Kline DG, Hackett ER, Happel LH. Surgery for lesions of the brachial plexus. *Arch Neurol* 1986;43:170–181
2. Kneeland JB, Kellman GM, Middleton WD, et al. Diagnosis of diseases of the supraclavicular region by use of MR imaging. *AJR* 1987;148:1149–1151
3. Rapoport S, Blair DN, McCarthy SM, Desser TS, Hammers LW, Sostman HD. Brachial plexus: correlation of MR imaging with CT and pathological findings. *Radiology* 1988;167:161–165
4. Leffert RD. *Brachial plexus injuries*. New York: Churchill Livingstone, 1985:80–120
5. McFarland LV, Raskin M, Daling JR, Benedetti TJ. Erb/Duchenne's palsy: a consequence of fetal macrosomia and method of delivery. *Obstet Gynecol* 1986;68:784–788
6. Murphey F, Hartung W, Kirklin JW. Myelographic demonstration of avulsing injuries of the brachial plexus. *AJR* 1947;58:102–105