



Providing Choice & Value

Generic CT and MRI Contrast Agents



**FRESENIUS
KABI**

CONTACT REP

AJNR

MR of Kearns-Sayre Syndrome

Philippe Demange, H. Pham Gia, G. Kalifa and N. Sellier

AJNR Am J Neuroradiol 1989, 10 (5 suppl) S91

http://www.ajnr.org/content/10/5_suppl/S91.citation

This information is current as
of July 21, 2025.

MR of Kearns-Sayre Syndrome

In 1958, Kearns and Sayre [1] reported two cases of the clinical triad of progressive external ophthalmoplegia, retinal pigmentary degeneration, and complete heart block. Kearns-Sayre syndrome is now known to be associated with basal ganglia hypodensities on CT scans [2, 3]. Other lesions reported are calcifications in the same location and hypodensities of cerebellar and cerebral white matter.

Case Report

A 6-year-old boy was first evaluated because of short stature and hypocalcemia. His mother's pregnancy and delivery had been normal. Growth failure became progressively obvious; it was quantified at -3.5 standard deviations when the patient was 6 months old. Within 2 years, his developmental milestones declined, necessitating special education. When he was 5 years old, carpopedal spasm began; the level of serum calcium was $152 \mu\text{mol/dl}$. Ptosis, ophthalmoplegia, and retinal pigmentary degeneration were noted shortly afterward.

On examination at 6 years, cerebellar ataxia, facial weakness, neurosensory hearing loss, and bilateral Babinski signs were noted. No motor deficiency was present. The patient's IQ was 80. The ECG showed an incomplete right bundle branch block. The electroretinogram was normal. CSF protein level was elevated (120 mg/dl). Skull films were normal. On CT scans, marked hypodensities of the thalami and within the left corona radiata were observed (Fig. 1). These findings were suggestive of a metabolic disease. MR revealed precise areas of hypersignal on T2-weighted sequences. Ragged red fibers were found on muscle biopsy, confirming the diagnosis of Kearns-Sayre syndrome.

Discussion

Kearns-Sayre syndrome belongs to the group of mitochondrial cytopathies [4]. The clinical classification of these diseases remains difficult, especially in the frequent situation of incomplete syndromes. Besides the fundamental clinical triad, many additional manifestations have been described in Kearns-Sayre syndrome, such as mental retardation, short stature, cerebellar ataxia, hearing loss, facial and limb weakness, high levels of protein in the CSF, and hypoparathy-

roidism [5]. Muscle biopsy reveals ragged red fibers correlated with mitochondrial abnormalities [1], but this anomaly is not specific for the syndrome.

In our case, a striking correlation was found between the sites of abnormal signal and the location of identified extrapyramidal pathways. These lesions correspond to the autopsy findings in one of the two cases from Kearns and Sayre [1] and to a case reported by Seigel et al. [2]. In our case, the efferent cerebellar and pallidal fibers to the thalamus and part of the thalamocortical connections were within the areas of abnormal signal shown by MR. These tracts are feedback pathways of the pyramidal system.

MR shows more lesions in Kearns-Sayre syndrome than any other technique does, and more precisely. Some correlation was found between the areas of abnormal signal and the clinical symptoms. More complete MR evaluation of mitochondrial disease is needed for a better understanding or, perhaps, classification of these disorders.

In conclusion, our case shows that because of its anatomic delineation and its high sensitivity, MR should be recommended as the first imaging examination when a metabolic disorder is suspected.

Philippe Demange

H. Pham Gia

G. Kalifa

N. Sellier

Hôpital St. Vincent de Paul
75674 Paris, Cedex 14, France

REFERENCES

1. Kearns TP, Sayre GP. Retinitis pigmentosa, external ophthalmoplegia, and complete heart block: unusual syndrome with histologic study in one of two cases. *Arch Ophthalmol* 1958;60:280-289
2. Seigel RS, Seeger JF, Gabrielsen TO, Allen RJ. Computed tomography in oculocraniosomatic disease (Kearns-Sayre syndrome). *Radiology* 1979;130:159-164
3. Robain O, Richardet JM, LeBalle JC, Arsenio-Nunes ML, Brissaud HE. Syndrome de Kearns-Sayre avec hypoparathyroïdisme et diabète. *Ann Pédiatr (Paris)* 1980;27:305-310
4. Dimauro S, Bonilla E, Zeviani M, Nakagawa M, Divivo DC. Mitochondrial myopathies. *Ann Neurol* 1985;17:521-538
5. Drachman DA. Ophthalmoplegia plus. *Arch Neurol* 1968;18:654-675

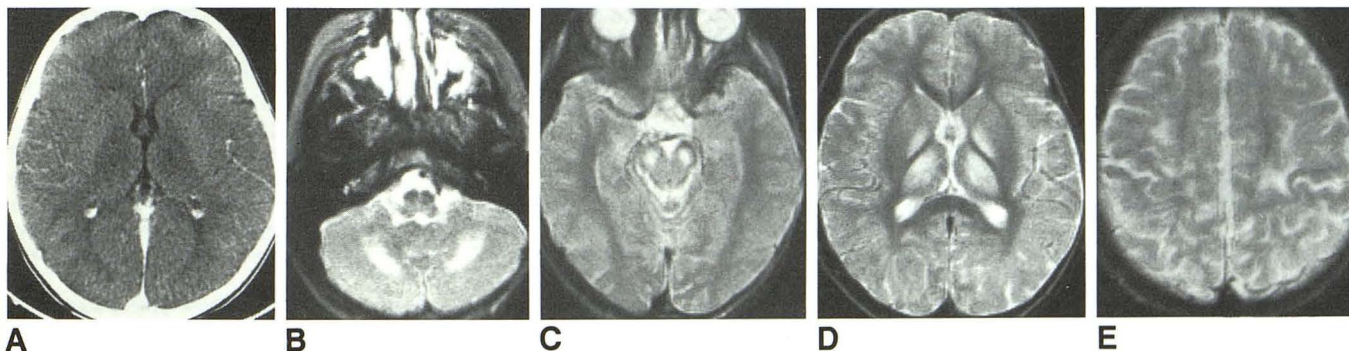


Fig. 1.—Kearns-Sayre syndrome.

A, Contrast-enhanced CT scan shows hypodensity of thalami and globus pallidus.

B-E, Spin-echo MR images, 2000/120, show areas of hypersignal in regions of nucleus dentatus of cerebellum (B), superior cerebellar peduncles and substantia nigra (C), thalamus (nucleus ventralis lateralis) and pars medialis of globus pallidus (D), and white matter around central sulcus (E).