



Providing Choice & Value

Generic CT and MRI Contrast Agents



CONTACT REP

AJNR

**Improvement of Cervicocranial IV Digital
Subtraction Angiography with Pixel Remasking
and Cardiac Gating**

J. H. W. Pexman, C. H. R. Wriedt, T. C. Richard and A. C.
MacDonald

This information is current as
of July 16, 2025.

AJNR Am J Neuroradiol 1989, 10 (5 suppl) S86-S87
http://www.ajnr.org/content/10/5_suppl/S86.citation

Improvement of Cervicocranial IV Digital Subtraction Angiography with Pixel Remasking and Cardiac Gating

Initial reports of IV digital subtraction angiography in the assessment of extracranial carotid disease were favorable [1-4], but this initial enthusiasm waned [5-7]. We show that alterations in apparatus and criteria can lead to different appraisals of this technique.

Materials and Methods

A Philips DVI 2 apparatus* was used, and the technique has been described [8]. A total of 264 carotid bifurcations were studied retrospectively, 130 with and 134 without cardiac gating and postprocessing with pixel shift (Fig. 1). Only patients without renal failure or major cardiac disease were included. The ideal study of an area of interest consisted of two or more views with no movement of the patient or superimposition of vessels (Fig. 2). "See through" superimposition was accepted.

The relevant carotid siphon was assessed in 31 patients whom the reviewer thought had a lesion of the common carotid bifurcation that was suitable for endarterectomy.

Results

With cardiac gating and pixel-shift postprocessing, the percentage of examinations that were diagnostic increased from 32% (42/130) to 80% (107/134) for all carotid bifurcations and from 50% (43/86) to 86% (60/70) on the relevant side.

The relevant siphon was well visualized on two views in 36% (5/14) when a potential surgical lesion was seen at the common carotid bifurcation in the initial group and in 59% (10/17) after pixel remasking and cardiac gating were used.

Carotid endarterectomy was performed on the basis of the results of IV digital subtraction angiography alone in half of the patients showing an appropriate lesion.

We were able to reduce the quantity of contrast material used from an average of 150 ml to 110 ml per patient after the apparatus was updated.

Discussion

Pelz et al. [9] reviewed the literature on IV digital subtraction angiography of carotid artery disease of the neck in 1985. They found that the percentage of images that were diagnostic varied from 60% to 93%; the percentage of studies that had excellent images ranged from 46% to 62%.

McCreary et al. [10] think that clear depiction of both carotid bifurcations is essential. We think that it is not always necessary to see both bifurcations well, as the true value of an imaging technique is its accuracy in answering a specific question with minimal side effects. Our examinations are tailored to the clinical question, and the first injection is made with the patient in the appropriate position to give the best view of the suspected lesion. Routinely, we now use the 10-in. (25.4 cm) field of view so that in suspected carotid disease we can see both the siphons and the bifurcations on each imaging series (Fig. 2).

Our investigation did three important things. First, we chose the strictest criteria giving the lowest successful results. Using criteria similar to ours and without pixel remasking, Hoffman et al. [5] visualized both carotid bifurcations in only 27% (34/126) of patients imaged and the clinically relevant bifurcation in 50%. These correspond to our initial results. Second, we updated our apparatus, and third, we repeated our research using the same criteria and the same reviewers, thus eliminating subjectivity. The additions to our apparatus improved the diagnostic visualization of both carotid bifurcations from 32% to 80% and visualization of the relevant bifurcation from 50% to 86%. Cardiac gating helps eliminate carotid movement, but we suspect that the major effect has been the ability to move the

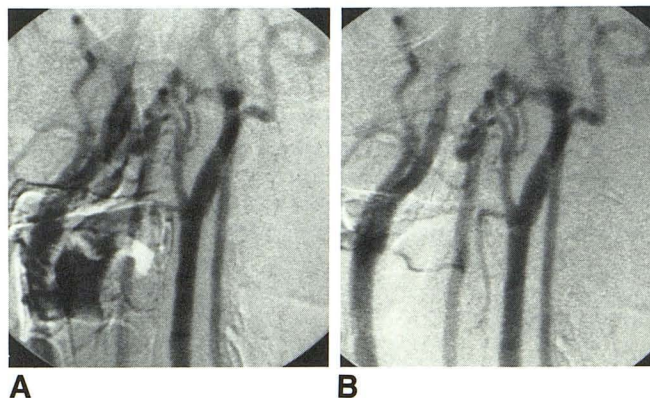


Fig. 1.—IV digital subtraction angiograms of carotid artery bifurcations. A, On initial recording, right carotid artery bifurcation cannot be assessed.

B, After pixel remasking, right bifurcation is seen despite some "see through" overlap. See through often is better appreciated by using brightness and contrast controls on television monitor.

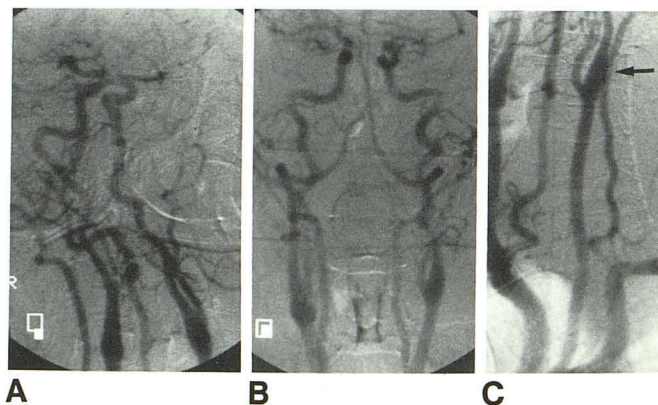


Fig. 2.—A and B, Left oblique (A) and corresponding posteroanterior (B) IV digital subtraction angiograms show both carotid siphons and bifurcations.

C, With patient's head turned to right, great vessel origins, carotid bifurcation, and "see through" overlap of left internal carotid artery and left vertebral artery (arrow) are seen.

* Philips Medical Systems, Shelton, CT

mask retrospectively. This has enabled us to turn adequate studies into excellent ones and some unacceptable examinations into adequate ones. In properly selected patients, we think that IV digital subtraction angiography still has an important role to play.

J. H. W. Pexman

C. H. R. Wriedt

T. C. Richard

A. C. MacDonald

University of Western Ontario

Victoria Hospital

London, Ontario, N6A 4G5, Canada

REFERENCES

1. Christenson PC, Ovitt TW, Fisher HD III, Frost MM, Nudelman S, Roehrig H. Intravenous angiography using digital video subtraction: intravenous cervicocerebral vascular angiography. *AJNR* **1980**;135:1145-1152
2. Crummy AB, Strother CM, Sachett JF et al. Computed fluoroscopy: digital subtraction for intravenous angiocardiology and arteriography. *AJR* **1980**;135:1131-1141
3. Seeger JF, Weinstein PR, Carmody RF, Ovitt TW, Fisher HD, Capo MP. Digital video subtraction angiography of the cervical and cerebral vasculature. *J Neurosurg* **1982**;56:173-179
4. Wood GW, Lukin RR, Tomsick TA, Chambers AA. Digital subtraction angiography with intravenous injection: assessment of 1,000 carotid bifurcations. *AJNR* **1983**;4:125-129, *AJR* **1983**;140:855-859
5. Hoffman MG, Gomes AS, Pais SO. Limitations in the interpretation of intravenous carotid digital subtraction angiography. *AJNR* **1983**;4:1167-1170, *AJR* **1984**;142:261-264
6. Turski PA, Zweibel JF, Strother CM, Crummy AB, Gastone GC, Sackett JF. Limitations of intravenous digital subtraction angiography. *AJNR* **1983**;4:271-273
7. Foley WD, Smith DF, Milde MW, Lawson TL, Towne JB, Bardyk DF. Intravenous DSA examination of patients with suspected cerebral ischemia. *Radiology* **1984**;151:651-659
8. Pexman JHW, Wriedt CHR, Richard TC. The significance of internal carotid artery occlusion shown by IV digital subtraction angiography. *AJNR* **1986**;8:485-488
9. Pelz DM, Fox AJ, Vinuela F. Digital subtraction angiography: current clinical applications. *Stroke* **1985**;3:528-535
10. McCreary JA, Schellhas KP, Brant-Zawadzki M, Norman D, Newton TH. Outpatient DSA in cerebrovascular disease using transbrachial arch injections. *AJNR* **1985**;6:795-801