



Discover Generics

Cost-Effective CT & MRI Contrast Agents



FRESENIUS
KABI

WATCH VIDEO

AJNR

Thalamic Hyperdensity: A Previously Unreported Sign of Sandhoff Disease

H. Philip Stalker and B. Kim Han

AJNR Am J Neuroradiol 1989, 10 (5 suppl) S82

http://www.ajnr.org/content/10/5_suppl/S82.citation

This information is current as
of June 6, 2025.

Thalamic Hyperdensity: A Previously Unreported Sign of Sandhoff Disease

Sandhoff disease is one of the three variants of GM₂ gangliosidosis, of which Tay-Sachs disease is the best known [1, 2]. Reports of CT findings in Sandhoff disease are sparse. White-matter hypodensity has been reported [3]. We describe a 1-year-old infant with biochemically proved disease who had increased density in the thalami on unenhanced CT scans.

Case Report

The patient was born at term after an uncomplicated pregnancy, labor, and delivery. The neonatal course was complicated only by mild hyperbilirubinemia, which was treated with phototherapy. When the baby was 6 months old, the mother sought medical attention because the infant was unable to sit unassisted. A CT scan performed at that time was normal. A second evaluation when the baby was 1 year old revealed an infant at the 50th percentile for weight and the 75th percentile for head circumference who did not track visual objects. Cherry-red macular spots and optic pallor were present. Muscle tone and mass were diminished, with brisk deep-tendon reflexes. The infant did not exhibit responsive behavior or verbalize. Enzyme studies showed a lack of hexosaminidase A and B activities consistent with Sandhoff disease. A second CT scan (Fig. 1) showed poor differentiation between gray and white matter; diffuse hypoattenuation of the brain parenchyma; and symmetric, nonenhancing, increased density in the thalami. The infant suffered progressive deterioration and died 1 year later. No autopsy was performed.

Discussion

The gangliosidoses are a subgroup of lysosomal storage diseases in which the absence of enzymatic activity causes the accumulation of biochemical intermediates and resultant cell death. The gangliosido-

ses are subdivided into GM₁ and GM₂ types. The three clinical variants of the GM₂ type are (1) deficient activity of hexosaminidase A only (Tay-Sachs disease), (2) deficient activity of both hexosaminidase A and hexosaminidase B (Sandhoff disease), and (3) absence of an associated activator protein. Clinically, the three variants are similar. Onset of a neurodegenerative process begins in infancy, with spasticity progressing to hypotonia. Infants are typically megalencephalic and often have cherry-red spots in the macula related to abnormal storage of ganglioside. The primary process involves the central cortical neurons. Subsequent loss of axons and myelin due to Wallerian degeneration results in diffuse white-matter edema progressing to gliosis [4].

CT findings in Tay-Sachs disease are white-matter hypoattenuation, atrophy, or no abnormality [3, 5]. To our knowledge, only one publication [3], an abstract with no images, describes CT findings in Sandhoff disease. That patient had diffuse white-matter hypoattenuation. No mention was made of thalamic hyperdensity. A review of the literature reveals that thalamic hyperdensity has been reported in only one other childhood neurodegenerative disorder, Krabbe disease [6], a leukodystrophy related to abnormal accumulation of betagalactocerebroside. On our patient's CT scan, the density of the thalami was 40 H compared with an average of 30 H in 10 children of a similar age who had normal CT scans. Unlike the findings in the reported case of Krabbe disease, the density did not change after administration of IV contrast material.

The cause of this thalamic hyperdensity is unknown. Pathologically, in advanced cases of Sandhoff disease, secondary lipofuscinosis results in deposits of pigmented degradation products in the thalami. This may be the source of the increased density seen in our patient, although this was not proved pathologically.

H. Philip Stalker

B. Kim Han

University of Cincinnati, College of Medicine

Children's Hospital Medical Center

Cincinnati, OH 45229-2899

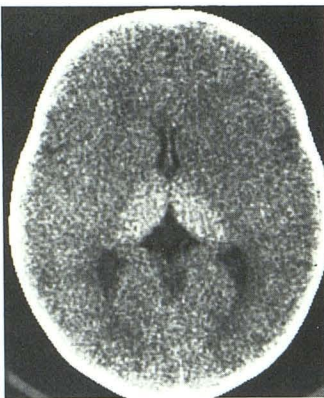


Fig. 1.—Unenhanced CT scan shows poor definition of differentiation between gray matter and white matter and thalamic hyperdensity. No increase in thalamic attenuation occurred after administration of IV contrast material.

REFERENCES

1. Glew RH, Alakananda B, Prenc EM, Remaley AT. Biology of disease: lysosomal storage diseases. *Lab Invest* 1985;53:252-253
2. Sandhoff K, Conzelmann E. The biochemical basis of gangliosidoses. *Neuropediatrics* 1984;15(suppl):85-92
3. Kazimiroff PB, Mehringer CM, Itabashi HH. Computerized tomography in GM₂ gangliosidosis. *Child Neurol Soc Prog* 1981;140:857
4. Goebel HH. Morphology of the gangliosidoses. *Neuropediatrics* 1984;15(suppl):97-106
5. Kendall BE, Kingsley D. The value of computerized axial tomography (CAT) in cranio-cerebral malformations. *Br J Radiol* 1978;51:171-190
6. Ferriero D, Koch TK. Computed tomography in white matter diseases. *Ann Neurol* 1985;17:314-315