

Generic Contrast Agents

Our portfolio is growing to serve you better. Now you have a *choice*.



FRESENIUS
KABI

[VIEW CATALOG](#)

AJNR

Reversal of White Matter Edema in Hypertensive Encephalopathy

Wendell A. Gibby, Mark M. Stecker, Herbert I. Goldberg, David B. Hackney, Larissa T. Bilaniuk, Robert I. Grossman and Robert A. Zimmerman

This information is current as
of May 30, 2025.

AJNR Am J Neuroradiol 1989, 10 (5 suppl) S78
http://www.ajnr.org/content/10/5_suppl/S78.citation

Reversal of White Matter Edema in Hypertensive Encephalopathy

We report a case of hypertensive encephalopathy in which MR imaging contributed to the early diagnosis in a patient with unusual clinical symptoms and CT findings. Serial MR provided pathophysiologic information regarding this condition.

Case Report

A 42-year-old man was admitted to the hospital because of increasing difficulty with gait and recent loss of vision. Examination revealed a blood pressure of 250/150 mm Hg, normal mental status, and severe hypertensive retinopathy bilaterally. There was no papilledema, and the fundi were pale. Cranial nerve, motor, and sensory examinations were normal. Plantar reflexes were extensor bilaterally. Gait was wide-based and unstable. There was no dysmetria on finger-to-nose testing. Electrolytes were remarkable for a potassium of 2.6, a blood urea nitrogen of 75, and a creatinine of 3.8. CT showed obliteration of the fourth ventricle and marked narrowing of the prepontine cistern; patchy periventricular hypodensity was present supratentorially. A subsequent MR study (Figs. 1A and 1C) suggested diffuse white matter edema, particularly in the posterior fossa.

The patient's gait improved dramatically, and his plantar responses became flexor after vigorous treatment of his hypertension. Repeat CT scan at 1 week showed resolution of mass effect in the posterior fossa. Four days later, a follow-up MR study also showed improvement (Figs. 1B and 1D).

Discussion

Various etiologies have been suggested for the pathophysiologic changes occurring in hypertensive encephalopathy (e.g., cerebral edema [1], vascular spasm [2], breakdown of autoregulation of cerebral blood flow [3], and intravascular coagulation [4]). Pathologic reports have documented brain swelling with focal and diffuse edema, fibrinoid necrosis of the small vessels, and microinfarction with petechial hemorrhage [5].

MR has high sensitivity for the detection of increased intracellular and extracellular water content in the brain [6, 7]. The MR studies presented here give convincing *in vivo* evidence of cerebral edema in the setting of hypertensive encephalopathy. The marked swelling of the cerebellum and brainstem and the abnormal high signal in the white matter reversed rapidly with treatment. Although MR cannot distinguish between hypertensive cerebral edema caused by autoregulation failure with breakdown of blood/brain barrier mechanisms [3] (vasogenic edema) from the edema caused by vascular spasm with ischemia [2] (cytotoxic edema), the rapid reversal of edema with treatment suggests edema caused by autoregulation failure. A vasogenic etiology is supported further by the confinement of the signal abnormality to the white matter. Follow-up MR is useful in evaluating

not only the reversible but also the chronic parenchymal abnormalities. The follow-up MR in this patient showed incomplete clearing of the high-signal abnormality in the supratentorial white matter. We think that this residuum represents gliosis from microinfarctions due to long-standing hypertension.

CT reports of hypertensive encephalopathy have indicated extensive low attenuation in cerebral white matter compatible with edema and compression of the ventricles, cisterns, and peripheral sulci [8–10]. These reports also have indicated the reversal of white matter edema with treatment, which was most evident in the supratentorial space. We do not have an explanation for the prominence of the edema in the posterior circulation in this patient. However, in this case, CT failed to clarify the nature of the mass effect in the posterior fossa, and the mass effect was clearly elucidated by MR.

Wendell A. Gibby

Mark M. Stecker

Herbert I. Goldberg

David B. Hackney

Larissa T. Bilaniuk

Robert I. Grossman

Robert A. Zimmerman

Hospital of the University of Pennsylvania

Philadelphia, PA 19104

REFERENCES

1. Nag S, Robertson DM, Dinsdale HB. Cerebral cortical changes in acute experimental hypertension: an ultrastructural study. *Lab Invest* 1977;36(2):150–161
2. Chester EM, Agamanolis DP, Banker BQ, Victor M. Hypertensive encephalopathy: a clinicopathologic study of 20 cases. *Neurology* 1978;28:928–939
3. Skinhøj S, Strandgaard S. Pathogenesis of hypertensive encephalopathy. *Lancet* 1973;1:461–462
4. Linton AL, Gavras H, Gleadle RI, et al. Microangiopathic haemolytic anaemia and the pathogenesis of malignant hypertension. *Lancet* 1969;1:1277–1278
5. Goldblatt H. Studies on experimental hypertension. VII. The production of the malignant phase of hypertension. *J Exp Med* 1938;67:809–826
6. Bydder GM, Steiner RE, Young IR, et al. Clinical NMR imaging of the brain: 140 cases. *AJNR* 1982;3(5):459–480, *AJR* 1982;139:215–236
7. Brant-Zawadzki M, Davis PL, Crooks LE, et al. NMR demonstration of cerebral abnormalities: comparison with CT. *AJNR* 1983;4(2):117–124, *AJR* 1983;140:847–854
8. Rail DL, Perkin GD. Computerized tomographic appearance of hypertensive encephalopathy. *Arch Neurol* 1980;37:310–311
9. Weingarten KL, Zimmerman RD, Pinto RS, Whelan MA. Computed tomographic changes of hypertensive encephalopathy. *AJNR* 1985;6:395–398
10. Kwong YL, Yu YL, Lam KSL, Woo E, Ma JTC, Huang CY. CT appearance in hypertensive encephalopathy. *Neuroradiology* 1987;29:215

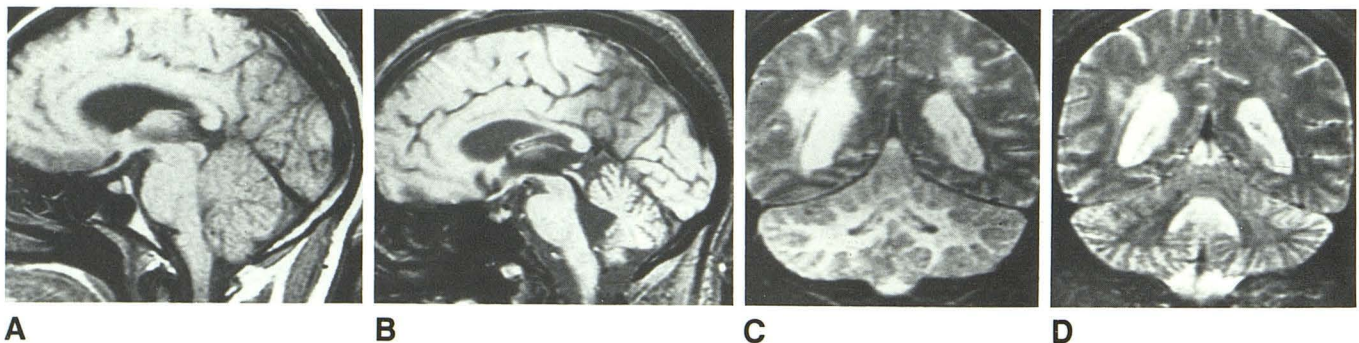


Fig. 1.—A and B, T1-weighted (600/20) sagittal MR scans through the midline of the brain. A, Before treatment, enlargement of pons, effacement of the fourth ventricle, and slight tonsillar herniation are present. B, 11 days later, pons is normal in size, and fourth ventricle is slightly enlarged. Tonsillar herniation has resolved and there is now prominence to the cerebellar sulci.

C and D, T2-weighted coronal (3000/80) images. C, Before treatment, diffuse, high-signal abnormality is present in cerebellar white matter, and patchy high signal is seen in periventricular region. D, 11 days later, there is reversal of high signal within cerebellar white matter and considerable improvement in periventricular high signal.