



Discover Generics

Cost-Effective CT & MRI Contrast Agents



FRESENIUS
KABI

WATCH VIDEO

AJNR

Cerebral Embolism After Gunshot Wounds

Elizabeth Hayes, Robert Ashenburg and David Phillips

AJNR Am J Neuroradiol 1989, 10 (5 suppl) S77

http://www.ajnr.org/content/10/5_suppl/S77.citation

This information is current as
of June 7, 2025.

Cerebral Embolism After Gunshot Wounds

Case Report

A 22-year-old man presented with a self-inflicted gunshot wound to the left neck. The rifle used was a .22 caliber filled with multiple small bird-shot pellets. Medical history was noncontributory.

Physical examination showed an 8-mm diameter entrance wound in the left posterior oral cavity without active bleeding. Powder burns were present. No exit wound was identified. Except for mild left neck swelling, the physical examination was unremarkable. The carotid artery pulses were 2+ and symmetric.

No bruits were audible. No focal motor or sensory deficits were discovered on physical examination. Cervical spine films showed scattered pellets throughout the left upper neck, and skull films revealed one intracranial pellet without skull fracture. A selective left internal carotid angiogram was performed and showed a minimally narrowed internal carotid artery without evidence of contrast extravasation (Fig. 1A). Head views showed one pellet within a left middle cerebral artery branch (Figs. 1B and 1C). Three days later, a noncontrast CT scan of the head confirmed an intracranial location of the fragment with an intact calvaria (Fig. 1D). No evidence of infarct, hemorrhage, or mass effect was seen. On CT, an additional small second fragment not seen on plain films or angiograms was identified.

Discussion

Embolization of material from a penetrating injury is unusual, and gunshot emboli are a relatively rare phenomenon. Most reported cases are caused by penetration of the aorta or left heart [1-5]. Gunshot embolism to the cerebral circulation also is rare and generally is associated with neurologic deficits [6-9]. In nine previously reported cases of carotid embolism from a gunshot wound, only two patients were neurologically intact. In both cases, the embolic site was the common carotid bifurcation rather than the intracranial carotid circulation [2, 5]. Collateral flow via the circle of Willis apparently maintained cerebral perfusion despite vascular compromise, thus accounting for the lack of neurologic deficits. In the seven remaining cases, hemiplegia was invariably present. Of these cases, the site of injury was the ipsilateral neck in five and the chest in two. The two cases with chest injuries both had bullet emboli to the right carotid circulation, the result of the straighter origin of the innominate from the arch and of the right common carotid from the innominate. The embolic site in all cases was the middle cerebral artery origin

from the internal carotid artery or the first major division of the middle cerebral artery into its branches. No intracranial emboli to the anterior cerebral circulation were identified in any case, a testament to the importance of geometry in determining the embolic site.

In our particular case, the very small size of the fragments allowed them to migrate far peripherally. Bird shot used in a .22-gauge rifle is number-11 size, which corresponds to an average pellet diameter of 2 mm. Some of the pellets in this case were irregular in shape, either because of manufacture or because of fragmentation at impact. This irregularity probably caused the fragment identified at angiography to rest in the middle carotid artery branch without totally occluding it. The lack of neurologic deficit most likely can be attributed to persistent flow to the embolic region (as shown by angiography). The second fragment was very small also and probably produced little significant vascular effect. These pellets are made of lead, and thus should pose no future contraindication to an MR procedure, should one be necessary.

Elizabeth Hayes

Robert Ashenburg

David Phillips

University of Massachusetts Medical Center
Worcester, MA 01655

REFERENCES

1. Barrett NR. Foreign bodies in the cardiovascular system. *Br J Surg* 19XX;37:416-445
2. Trimble C. Arterial bullet embolism following thoracic gunshot wounds. *Ann Surg* 1968;168:911-916
3. Taylor MT, Schlegel DM, Habegger ED. Bullet embolism. *Am J Surg* 1968;114:457-560
4. Ward PA, Suzuki A. Gunshot wound of the heart with peripheral embolization. *J Thorac Cardiovasc Surg* 1974;68:440-446
5. Kinmouth JB, Burton JD, Longmore DB. Gunshot wounds of the heart with embolism. *Br Med J* 1961;2:1666-1668
6. Duerr S, Cocco T. Gunshot wound of the abdomen with cerebral embolization. *J Trauma* 1977;17(2):155-157
7. Kapp JP, Gielchinsky I, Jelsma R. Metallic fragment embolization to the cerebral circulation. *J Trauma* 1961;13:256-261
8. Van Gilder JC, Coxe WS. Shotgun pellet embolus of the middle cerebral artery. *J Neurosurg* 1970;32:711-714
9. Piazza G, Gaist B. Occlusion of middle cerebral artery by foreign body embolus. *J Neurosurg* 1960;17:172-176

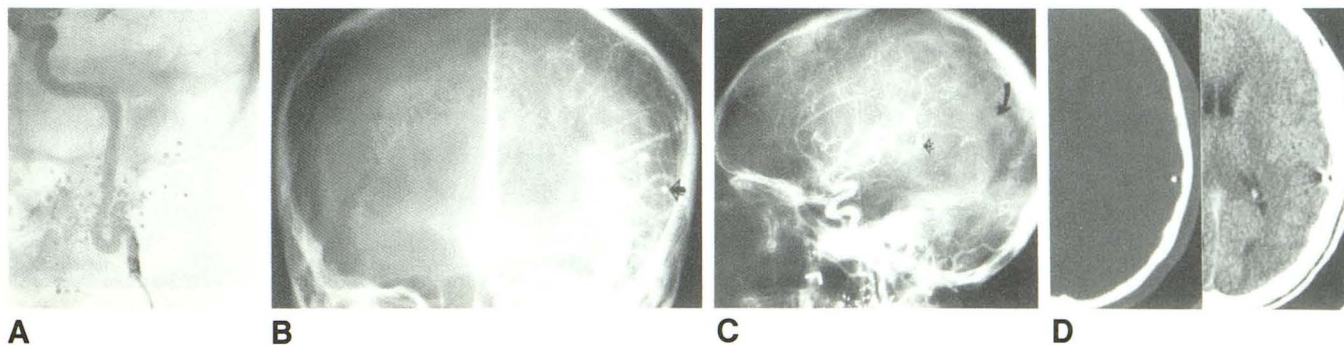


Fig. 1.—A, Subtraction anteroposterior view of left internal carotid angiogram shows minimal luminal narrowing (without other arterial abnormality) and multiple irregular pellets.

B and C, Anteroposterior (B) and lateral (C) head views from left internal carotid angiogram show a pellet lodged in a middle cerebral artery branch with distal flow intact (straight arrow). Curved arrow shows probable location of second small parietal lobe fragment detected on CT.

D, Noncontrast CT scans show peripheral location of fragment with intact skull. No evidence of infarct, mass effect, or hemorrhage is seen.