



**Providing Choice & Value**  
Generic CT and MRI Contrast Agents

**FRESENIUS  
KABI**

**CONTACT REP**

**AJNR**

## **Saccular Aneurysm of the Azygos Anterior Cerebral Artery**

Robert M. Schick and Calvin L. Rumbaugh

*AJNR Am J Neuroradiol* 1989, 10 (5 suppl) S73

[http://www.ajnr.org/content/10/5\\_suppl/S73.citation](http://www.ajnr.org/content/10/5_suppl/S73.citation)

This information is current as  
of July 14, 2025.

## Saccular Aneurysm of the Azygos Anterior Cerebral Artery

The true azygos anterior cerebral artery is an unusual variation in the circle of Willis in which a single vessel ramifies to supply the medial aspects of both anterior cerebral hemispheres. We suggest that this unusual variation may be associated with an increased incidence of aneurysm formation at its site of branching.

### Case Report

A 42-year-old man developed severe headache and meningismus. CT of the brain showed a left frontal lobe hematoma and intraventricular hemorrhage. Left internal carotid angiography showed an azygos anterior cerebral artery with an elongated, lobular aneurysm arising at its ramification (Fig. 1). The findings were confirmed at the time of surgical clipping.

### Discussion

The azygos anterior cerebral artery is a rare variation in the vascular supply to the cerebral hemispheres. In a study of 381 human brains, Baptista [1] found only one case of a solitary, unpaired vessel supplying the anterior cerebral artery territory bilaterally and arising as a single trunk from the confluence of the horizontal segments (A1) of the right and left anterior cerebral artery stems. This true azygos cerebral artery (Baptista type 1) is to be distinguished from the more common so-called azygos anterior cerebral arteries: Baptista type 2 (in which separate right and left anterior cerebral vessels are present, but one of these vessels sends a variable number of branches to the contralateral hemisphere and the opposite A1 is hypoplastic) and Baptista type 3 (in which a midline vessel arising from the anterior communicating vessel is present in addition to well-developed right and left anterior cerebral vessels).

In a review of 107 cerebral angiograms, LeMay and Gooding [2] found four azygos-type anterior cerebral arteries but suggested it was "probable that upon anatomic dissection one or more of the

cases classified as an azygos vessel would be shown by Baptista's classification to represent a bihemispheric artery."

Aneurysms of the distal anterior cerebral artery are rare, representing 3%–5% of intracranial aneurysms [3–7]. These aneurysms characteristically occur at the level of the genu of the corpus callosum where the pericallosal artery sharply arches posteriorly. Of patients with distal anterior cerebral artery aneurysms, approximately 5% are shown to have multiple aneurysms with a predilection for mirror aneurysm in the contralateral anterior cerebral artery. No azygos anterior cerebral arteries were reported in large series of distal anterior cerebral artery aneurysms [3, 5, 7].

To our knowledge, only two cases of true azygos anterior cerebral artery with aneurysm formation have been previously reported [8, 9]. In each of these cases, the location of the aneurysm was at the ramification of the large azygos vessel, as seen in our patient. Two cases reported by Hayashi et al. [10] as giant aneurysm of an azygos anterior cerebral artery occurred in a Baptista type 2 vessel; the A1 vessel on the contralateral side was hypoplastic in each case.

Although the possible relation between variations in the circle of Willis and aneurysm formation are discussed in the Cooperative Study and in neuroangiography textbooks, none of these sources cite the azygos anterior cerebral artery in this regard. Perhaps stress applied to the vessel wall at the site of flow division may contribute to the observed localization of aneurysm in these cases [6].

Although the number of reported cases is small, we suggest that the true azygos anterior cerebral artery, a rare variation in the circle of Willis, may be associated with an increased incidence of aneurysm formation at its site of branching.

Robert M. Schick  
Calvin L. Rumbaugh  
Harvard Medical School  
Brigham and Women's Hospital  
Boston, MA 02115

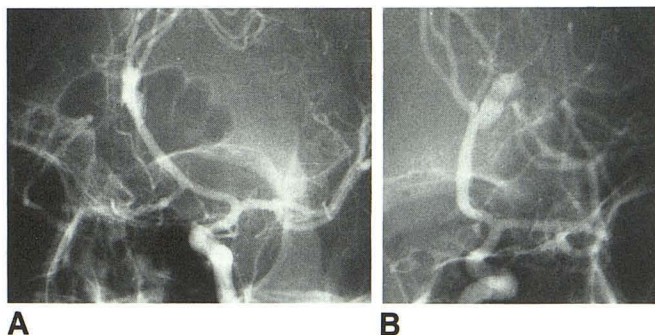


Fig. 1.—Selective left internal carotid angiography (A) with cross-compression of right common carotid and (B) without cross-compression. Horizontal segments (A1) of right and left anterior cerebral arteries join in midline to form a single large vessel. This azygos anterior cerebral artery ascends in interhemispheric fissure to level of rostrum of corpus callosum and then ramifies to supply medial aspects of right and left cerebral hemispheres. A lobulated, elongated aneurysm arises at this point of branching.

### REFERENCES

1. Baptista AG. Studies on arteries of the brain. II. Some anatomic features and their clinical implications. *Neurology* 1963;13:825–835
2. LeMay M, Gooding CA. The clinical significance of the azygos anterior cerebral artery. *AJR* 1967;98(3):602–610
3. Laitinen L, Snellman A. Aneurysms of the pericallosal artery: a study of 14 cases. *J Neurosurg* 1960;17:447–458
4. Wilson CB, Christiansen FK, Subrahmanian MV. Intracranial aneurysms of the pericallosal artery bifurcation. *Am Surg* 1965;31:386–393
5. Yasargil MG, Cartor LP. Saccular aneurysms of the DACA. *J Neurosurg* 1974;40:218–223
6. Sahs AL. Observations on the pathology of saccular aneurysms. In Sahs AL, Perret GE, Locksley HB, et al., eds. *Intracranial aneurysms and subarachnoid hemorrhage: a cooperative study*. Philadelphia: Lippincott, 1969
7. Wishoff JH, Flamm ES. Aneurysms of the distal anterior cerebral artery and associated vascular abnormalities. *Neurosurgery* 1979;20(5):735–741
8. Kondo A, Koyama T, Ishikawa J, et al. Ruptured aneurysm of an azygos anterior cerebral artery. *Neuroradiology* 1979;17:227–229
9. Katz RS, Horoupian DS, Zingesser L. Aneurysm of the azygos anterior cerebral artery. *J Neurosurg* 1982;48:804–808
10. Hayashi M, Kobayashi H, Kawano H, et al. Giant aneurysm of an azygos anterior cerebral artery: report of two cases and a review of the literature.