



Providing Choice & Value
Generic CT and MRI Contrast Agents

**FRESENIUS
KABI**

CONTACT REP

AJNR

**Anderson-Fabry Disease: A Case Report with
MR, CT, and Cerebral Angiography**

Robert Moumdjian, Donatella Tampieri, Denis Melanson and
Romeo Ethier

AJNR Am J Neuroradiol 1989, 10 (5 suppl) S69-S70
http://www.ajnr.org/content/10/5_suppl/S69.citation

This information is current as
of July 14, 2025.

Anderson-Fabry Disease: A Case Report with MR, CT, and Cerebral Angiography

We report here the MR, CT, and cerebral angiographic picture of a patient with Fabry disease recently admitted to our institution. Although the clinical literature is quite rich [1-6], the neuroradiologic literature [7] seems deficient; to our knowledge, no case studied by MR has been reported previously.

Case Report

A 22-year-old, nondiabetic man presented with a history of an acute onset of diplopia, nausea, vomiting, and dizziness 12 hr before admission. At the age of 12 years, he had undergone surgery for a blocked right femoral artery. At age 21, he had experienced a dysphasic episode associated with gait disturbance and falling to the right; this episode resolved within 5 days. Three months before the present episode, he was admitted to hospital for right-sided weakness. During this admission, he was found to have chronic renal failure; a kidney biopsy revealed findings compatible with Fabry disease. He was an alcohol abuser and smoked 1 pack of cigarettes per day. On admission, his physical examination revealed a drowsy but easily arousable young adult; his blood pressure was 140/90, and there was a questionable angiokeratoma on the right buttock. The neurologic examination revealed right medial rectus paralysis, right internuclear ophthalmoplegia, upbeat nystagmus on upward gaze, and left horizontal beat nystagmus; tone was increased on the right, and he showed a right pronator drift, with decreased rapid alternating movements over right upper extremity and difficult tandem walking. Reflexes were brisk all over with bilateral Babinski sign and clonic ankle jerks. Electromyograph showed mild peripheral neuropathy of the axonal type; ECG showed increased QRS voltage. Laboratory analysis showed decreased creatinine clearance and proteinuria (3.5 g/day), leukocyte α -galactosidase was 6.2% of the normal. The urine analysis showed cylindroids and amorphous urates. Acid-fast bacillus was negative.

A kidney biopsy revealed prominent small clear vacuoles in cytoplasm with marked enlargement of glomerular and epithelial cells in vascular loops and abundant mononuclear infiltrates in interstitium. Electron microscopy showed typical zebra bodies. The patient under-

went skull radiographs, CT, MR, and angiography. The skull radiographs were unremarkable. We used 5-mm-thick slices for CT of the posterior fossa and 10-mm-thick slices for CT of the supratentorial region (Figs. 1A and 1B). The MR images are shown in Figures 1C and 1D. Finally, the patient underwent a bilateral carotid and left vertebral angiographic examination: the angiographic results were normal.

Discussion

Anderson-Fabry disease (angiokeratoma corporis diffusum) is a form of sphingolipidosis inherited as an X-linked recessive trait. Female carriers, however, show an incomplete form. The primary deficit resides in the enzyme α -galactosidase, which results in the accumulation of trihexoside ceramide in endothelial, perithelial, and smooth-muscle cells of blood vessels as well as in renal tubular and glomerular cells, the heart, skin, mucosa, liver, and nerve cells. In the CNS, it is found in the hypothalamus, the amygdaloid nuclei, substantia nigra, reticular nuclei, anterior and intermediolateral horns of the spinal cord, and sympathetic and dorsal root ganglia.

Garcin et al. [8] have reviewed the neurologic and neuropathologic findings of this disease. It becomes manifested in childhood and adolescence with lancinating pains and dysesthesias of the extremities. Later on, a diffuse vascular involvement leads to hypertension, renal damage, cardiomegaly, myocardial ischemia, and thrombotic infarcts of the brain. Fatigue and changes in temperature may induce pains. The glycolipid accumulates in peripheral nerves and spinal ganglia, perineurally or intraneurally. Degenerative changes in the afferent fibers are thought to be the most likely cause of the painful sensory experiences. The renal, cerebral, and myocardial involvement occurs later in the illness, accompanied by the eruption of maculopapular lesions over groins, scrotum, thigh, and trunk. Patients usually die at about 40 years of age from renal failure and hypertension. Renal transplantation seems to provide reasonable hope for these patients.

In summary, Anderson-Fabry disease is a rare, systemic, X-linked, lipid-storage disease. Neuroradiologically, it presents with multiple

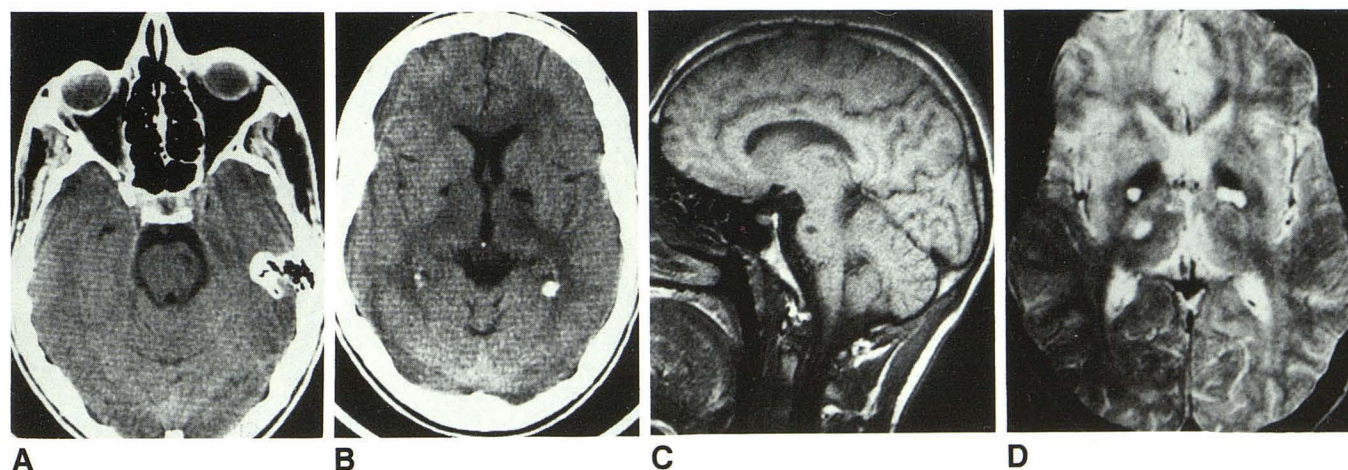


Fig. 1.—A and B, CT scans show lacunar infarcts in left pons (A) and in both pallidal nuclei and adjacent left internal capsule (B). C, T1-weighted sagittal MR image (350/30) shows lacunar infarcts in pons and corpus callosum. D, T2-weighted MR image (2100/100) shows multiple lacunes in both basal ganglia, left thalamus, and posterior limb of right internal capsule.

bilateral lacunar infarcts on CT and MR. No previous MR description of Anderson-Fabry disease is present in the literature. MR, more sensitive than CT, allows the complete assessment of the disease by detection of all lacunar infarcts. Anderson-Fabry disease should be considered when young adults present with ischemic lesions associated with chronic renal failure, cardiac ischemia, angiokeratoma of the integument, and peripheral neuropathy.

ACKNOWLEDGMENTS

Special thanks to Antoine Hakim for allowing us access to the records of his patient and to Victor Epp for manuscript preparation.

Robert Moundjian
Donatella Tampieri
Denis Melanson
Romeo Ethier
Montreal Neurological Institute and Hospital
McGill University
Montreal, Quebec H3A 284
Canada

REFERENCES

1. Desnick RJ, Sweeley CC. Fabry's disease: α -galactosidase-A deficiency. In: Stanbury JB, Wyngaarden JB, Frederickson DS, Goldstein JL, Brown MS (eds). *The metabolic basis of inherited disease*, 5th ed. New York: McGraw-Hill 1983:906-944
2. Faraggiana T, Chung J, Strauss L, et al. Light and electron microscope histochemistry of Fabry's disease. *Am J Pathol* 1981;103:247
3. Farge D, Nadler S, Wolfe LS, Barré P, Jothy S. Diagnostic value of kidney biopsy in heterozygous Fabry's disease. *Arch Pathol Lab Med* 1985; 109:85-88
4. Wallace HJ. Anderson-Fabry disease. *Br J Dermatol* 1973;88:1-23
5. Bird TD, Laganoff D. Neurological manifestations of Fabry's disease in female carriers. *Ann Neurol* 1978;4:537
6. Calhoun DH, Bishop DF, Bernstein HS, Quinn H, Hantzopoulos P, Desnick RJ. Fabry disease: isolation of a cDNA clone encoding human α -galactosidase A. *Proc Natl Acad Sci USA* 1981;82:7364-7368
7. Rabey JM, Uardi J, Fletcher S. Unusual causes of stroke in young patients. *Harefuah* 1978;95(12):420-422
8. Garcin R, Hewitt J, Godlewski S, Laudat P. Des aspect neurologiques de l'angiokeratose de Fabry: à propos de deux cas. *Presse Med* 1967; 75:435