



Providing Choice & Value

Generic CT and MRI Contrast Agents



**FRESENIUS
KABI**

CONTACT REP

AJNR

MR of Childhood Calcified Herniated Cervical Disk with Spontaneous Resorption

James W. Lester, Jr., William A. Miller, Michael P. Carter and J. Michael Hemphill

AJNR Am J Neuroradiol 1989, 10 (5 suppl) S48-S50

http://www.ajnr.org/content/10/5_suppl/S48.citation

This information is current as
of July 20, 2025.

MR of Childhood Calcified Herniated Cervical Disk with Spontaneous Resorption

James W. Lester, Jr.,¹ William A. Miller,¹ Michael P. Carter,¹ and J. Michael Hemphill²

Calcification of cervical intervertebral disks in childhood is a well-known entity [1–7], although the etiology remains unknown. Rarely, disk herniation also may be present and produce symptoms of cord compression. The disk herniation and calcification usually resolve with conservative therapy over a period of a few weeks to several months. We present an interesting case in which the diagnosis was established by MR; CT provided complementary information.

Case Report

An 11-year-old boy presented to the emergency room with neck stiffness and bilateral shoulder pain in December 1987. Cervical spine films showed C4–C5 intervertebral disk calcification (Fig. 1A). There was a history of undocumented fever and recent upper respiratory infection, but no history of trauma. No laboratory data were obtained. The patient experienced several episodes of transient right arm numbness during the next month and was admitted for further evaluation in early February 1988. The patient had a temperature of 101.6°F (38.7°C) on admission, but he was otherwise asymptomatic. Detailed neurologic examination was within normal limits.

MR showed a large extradural mass extending cephalad from the C4–C5 interspace to the level of the C2–C3 interspace (Fig. 1B). The more superior component of the mass corresponded in signal intensity to that of the intact cervical disks on all pulse sequences and was presumed to represent extruded nucleus pulposus from the C4–C5 interspace (arrow, Fig. 1C). Inferiorly, continuity of the extradural mass with the C4–C5 disk space was confirmed (arrowheads, Fig. 1C). A rim of signal void on MR (Fig. 1D) was confirmed by CT to represent calcification (Fig. 1E).

On conservative treatment with analgesics and a soft collar, the patient became asymptomatic in 5 days and has remained well. MR 5 weeks later showed decrease in size of the herniated nucleus pulposus. Follow-up MR and CT examinations in June 1988 showed essentially complete resorption of the herniated disk and extradural calcification. Residual calcification was present in the C4–C5 disk space (Figs. 1F and 1G).

Discussion

Childhood intervertebral disk calcification has been well documented, but the etiology remains obscure [1–7]. Clinical signs and symptoms are frequently associated with cervical disk calcification, and they include fever, pain, leukocytosis, and an elevated erythrocyte sedimentation rate. The average

age of occurrence is between 5 and 10 years [1], although it has been seen in one neonate [2]. Some authors report equal sex distribution in children with intervertebral disk calcification [2, 3], but others report a male predominance of 2:1 or more [1, 4, 5].

The clinical syndrome suggests an inflammatory cause; additionally, as in our case, an antecedent illness such as an upper respiratory infection is not rare. However, no direct association between the antecedent infection and disk calcification has been established. Likewise, trauma and metabolic derangements have not been consistent etiologic factors. It has been suggested that this disease may be analogous to calcific tendonitis, in view of the similarity of the nucleus pulposus to the fibrous connective tissue of tendons [4]. In the few reported cases with surgical intervention, pathologic analysis has revealed an amorphous calcification within the nucleus pulposus without any inflammatory reaction [1].

Herniation of the nucleus pulposus in children with intervertebral disk calcification is a rare complication that may produce symptoms of nerve root compression. Posterior [2] and anterior [2, 6] herniations have been reported. In our patient, a significant portion of the nucleus pulposus actually appeared to have been extruded, with cephalad migration to the interspace above the disk of origin.

In our case and in most reported cases [2, 4], surgical intervention has not been necessary because of prompt resolution of neurologic symptoms with conservative management. As seen in this case, the calcified extruded nucleus pulposus is resorbed, although the resorption mechanism is unclear. One of the most attractive explanations for this phenomenon is the excellent blood supply of the intervertebral disk in childhood, which may facilitate resorption. MR was essential in our conservative patient management, allowing us to monitor the degree of nucleus pulposus extrusion and its subsequent resorption.

Our patient also had slight loss of height of the C4 and C5 vertebral bodies. This finding has been described previously [5, 6] and may represent a permanent structural change [6].

With the exception of rare case reports [7, 8], previous reports have been limited to plain film and myelographic findings. Although the disk space calcification was readily

Received August 12, 1988; revision requested September 27, 1988; revision received January 5, 1989; accepted January 5, 1989.

¹ Department of Radiology, Memorial Medical Center, Savannah, GA 31403. Address reprint requests to W. A. Miller.

² Savannah Neurological Assoc., P.C., 5105 Paulsen St., Savannah, GA 31405.

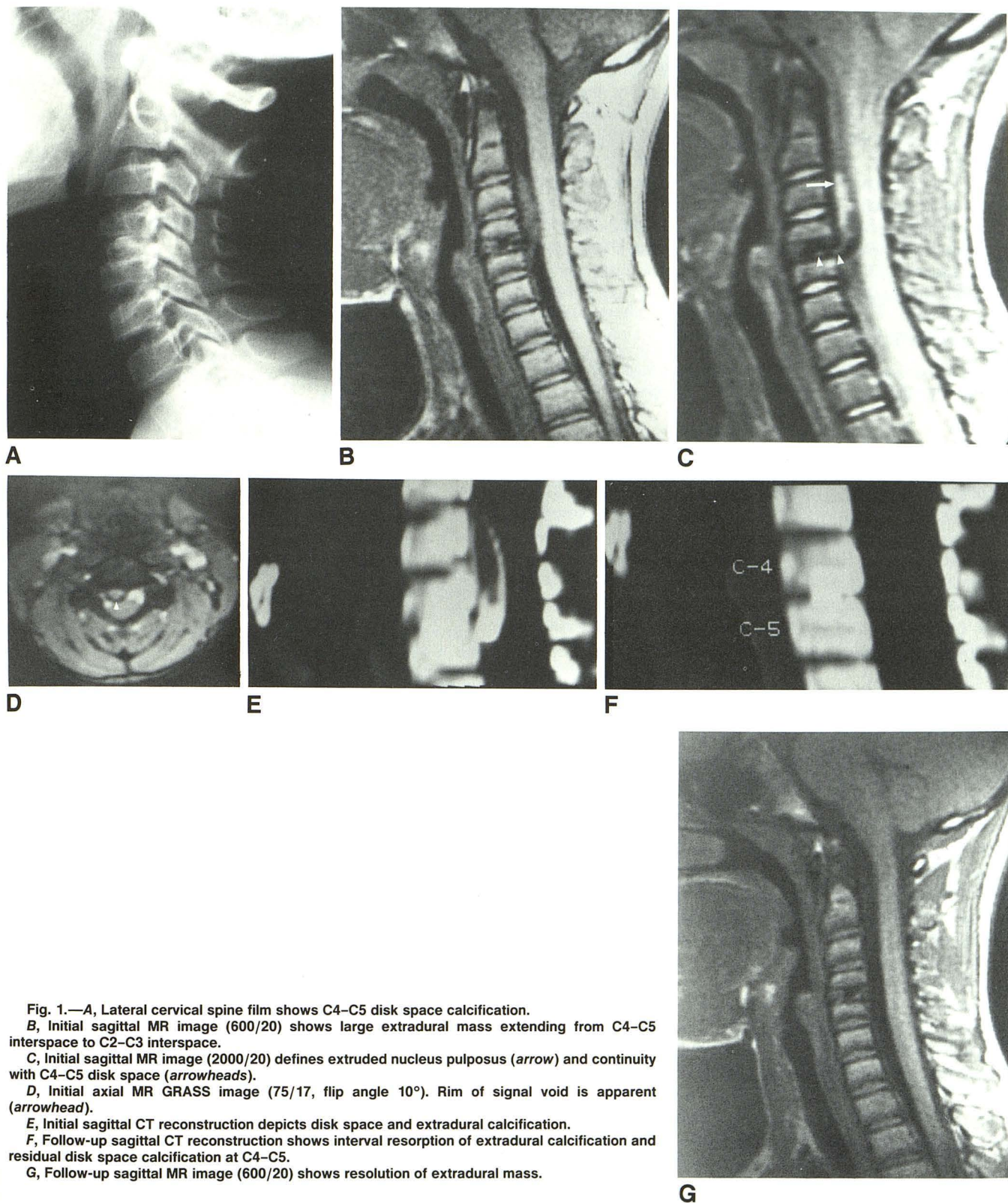


Fig. 1.—A, Lateral cervical spine film shows C4–C5 disk space calcification.
 B, Initial sagittal MR image (600/20) shows large extradural mass extending from C4–C5 interspace to C2–C3 interspace.
 C, Initial sagittal MR image (2000/20) defines extruded nucleus pulposus (arrow) and continuity with C4–C5 disk space (arrowheads).
 D, Initial axial MR GRASS image (75/17, flip angle 10°). Rim of signal void is apparent (arrowhead).
 E, Initial sagittal CT reconstruction depicts disk space and extradural calcification.
 F, Follow-up sagittal CT reconstruction shows interval resorption of extradural calcification and residual disk space calcification at C4–C5.
 G, Follow-up sagittal MR image (600/20) shows resolution of extradural mass.

apparent on plain films in our case, MR provided an excellent noninvasive method to diagnose the complicating disk herniation and to evaluate its relationship to the spinal cord. CT was complementary and confirmed that the rim of signal void was calcification and not hemosiderin caused by hemorrhage.

In conclusion, idiopathic intervertebral disk calcification in childhood rarely may present with symptoms of cord compression caused by associated disk herniation. Surgical intervention usually is not necessary because symptoms resolve with conservative therapy. MR should be the diagnostic procedure of choice in evaluating symptomatic children with intervertebral disk calcification; CT may provide complementary information.

ACKNOWLEDGMENTS

The authors are grateful to Gwyn Hall for the illustrations and to Sharon Durden for assistance in manuscript preparation.

REFERENCES

1. Swick HM. Calcification of intervertebral discs in childhood. *J Pediatr* **1975**;86:364-369
2. Mainzer F. Herniation of the nucleus pulposus. A rare complication of intervertebral-disk calcification in children. *Radiology* **1973**;107:167-170
3. Melnick JC, Silverman FN. Intervertebral disk calcification in childhood. *Radiology* **1963**;80:399-407
4. Newton TH. Cervical intervertebral-disc calcification in children. *J Bone Joint Surg [Am]* **1958**;40-A:107-113
5. Morris J, Niebauer J. Calcification of the cervical intervertebral disc. *Am J Dis Child* **1963**;106:295-300
6. Furukawa K, Hoshino R, Hasue M, Kuramochi E. Cervical intervertebral-disc calcification in a child. Case report with seven-year follow-up. *J Bone Joint Surg [Am]* **1977**;59-A:692-693
7. McGregor JC, Butler P. Disc calcification in childhood: computed tomographic and magnetic resonance imaging appearances. *Br J Radiol* **1986**;59:180-182
8. Wells RG, Sty JR. Comparative imaging disk calcification in childhood. *Clin Nucl Med* **1985**;10:821-822