

# Generic Contrast Agents

Our portfolio is growing to serve you better. Now you have a *choice*.



FRESENIUS  
KABI

[VIEW CATALOG](#)

# AJNR

## Moyamoya Disease in Down Syndrome

Eric K. Outwater, Robert C. Platenberg and Samuel M. Wolpert

*AJNR Am J Neuroradiol* 1989, 10 (5 suppl) S23-S24

[http://www.ajnr.org/content/10/5\\_suppl/S23.citation](http://www.ajnr.org/content/10/5_suppl/S23.citation)

This information is current as  
of May 29, 2025.

# Moyamoya Disease in Down Syndrome

Eric K. Outwater,<sup>1</sup> Robert C. Platenberg,<sup>2</sup> and Samuel M. Wolpert<sup>2</sup>

Children with right-to-left shunts or valvular malformations from congenital heart disease are at risk for embolic stroke. Primary cerebrovascular disease is rare in children. We describe a child with Down syndrome and complex congenital heart disease presenting with multiple nonembolic infarctions over a 7-year period, during which subtle internal carotid artery stenosis progressed to an advanced moyamoya angiographic pattern.

## Case Report

A moderately retarded girl with trisomy-21 was well (except for frequent episodes of upper respiratory tract infections and otitis media) until the age of 9, when she developed acute right hemiparesis. Cranial CT showed an infarct of the left putamen. A systolic murmur was discovered. Cardiac catheterization revealed a persistent common atrioventricular canal (partial type), with a left-to-right atrial-level shunt. Echocardiography failed to find a source of systemic emboli. Bilateral cerebral angiography showed only a stenosis of the proximal left middle cerebral artery (Fig. 1A), without evidence of distal arterial occlusions. Nevertheless, the clinical impression was that a probable cerebral embolus had occurred. Daily aspirin was prescribed because anticoagulants were believed to pose an unacceptable risk in this patient.

The septal defect and associated mitral valve cleft were repaired 18 months later. Her hemiparesis had resolved by the time of surgery. She remained asymptomatic until age 11, when she experienced a probable seizure. CT showed a right frontal lobe infarct as well as the infarcted left putamen. Echocardiography revealed no valvular vegetations, thrombi, or shunts.

When the patient was 14 years old, she was admitted to the hospital because of chronic abdominal pain, anemia, and episodes of vomiting followed by syncope. No focal deficits were found on neurologic examination. Laboratory data included an erythrocyte sedimentation rate of 132 mm/hr, normal leukocyte count, and normal CSF. Celiac disease was diagnosed by duodenal biopsy. An electroencephalogram recorded a focal epileptiform abnormality in the right anterior temporal lobe. Cranial CT (Figs. 1B and 1C) revealed clinically unsuspected infarcts that were not present on CT scans 3 years earlier. Left cerebral arteriography revealed marked progression of the arterial stenoses, with the development of prominent moyamoya collateral vessels (Figs. 1D and 1E) since the angiogram 5 years

earlier. Selective right internal carotid and left vertebral artery injections revealed a supraclinoid internal carotid occlusion, prominent leptomeningeal collaterals from the posterior cerebral arteries as well as from the prominent lenticulostriate arteries. No specific therapy for her neurologic disease other than anticonvulsants has been started yet.

## Discussion

The incidence of moyamoya disease may be increased in children with Down syndrome. In summarizing the world's literature on the occurrence of the two together, Fukushima et al. [1] found five cases and added a case of their own. On the basis of estimated incidences of the two diseases, they concluded that Down syndrome children in Japan are at heightened risk for moyamoya disease. Although moyamoya disease is not strictly a genetic disorder, it has been associated with certain HLA haplotypes [2], and familial clusters of cases are known [3]. Additionally, it has been described in a patient with glycogen storage disease [4]. It seems reasonable to conclude that certain genetic factors may directly or indirectly predispose some children to moyamoya disease.

The globus pallidus calcifications seen in this case occur commonly in Down patients. Ieshima et al. [5], in a review of cranial CT scans of 56 patients with Down syndrome (one of the 56 was excluded because he had moyamoya disease), found a 10.7% prevalence of globus pallidus calcifications. They speculated that these perivascular calcifications are a manifestation or consequence of the Alzheimer type dementia so common in older patients with Down syndrome. Cranial MR imaging has been reported as typically normal in these patients [6].

Speech disturbances, seizures, and progressive cognitive deficits are common symptoms of moyamoya disease [3]; they may be particularly difficult to evaluate in children with Down syndrome. A higher suspicion of the disease leading to an accurate early diagnosis is important to avoid inappropriate therapy for neurologic symptoms that may be attributed to other causes. Because this patient was at risk for emboli of

Received November 17, 1988; revision requested December 28, 1988; revision received January 19, 1989; accepted February 14, 1989.

<sup>1</sup> Department of Radiology, New England Medical Center, 750 Washington St., Boston, MA 02111.

<sup>2</sup> Section of Neuroradiology, Department of Radiology, New England Medical Center, 750 Washington St., Boston MA 02111. Address reprint requests to S. M. Wolpert.



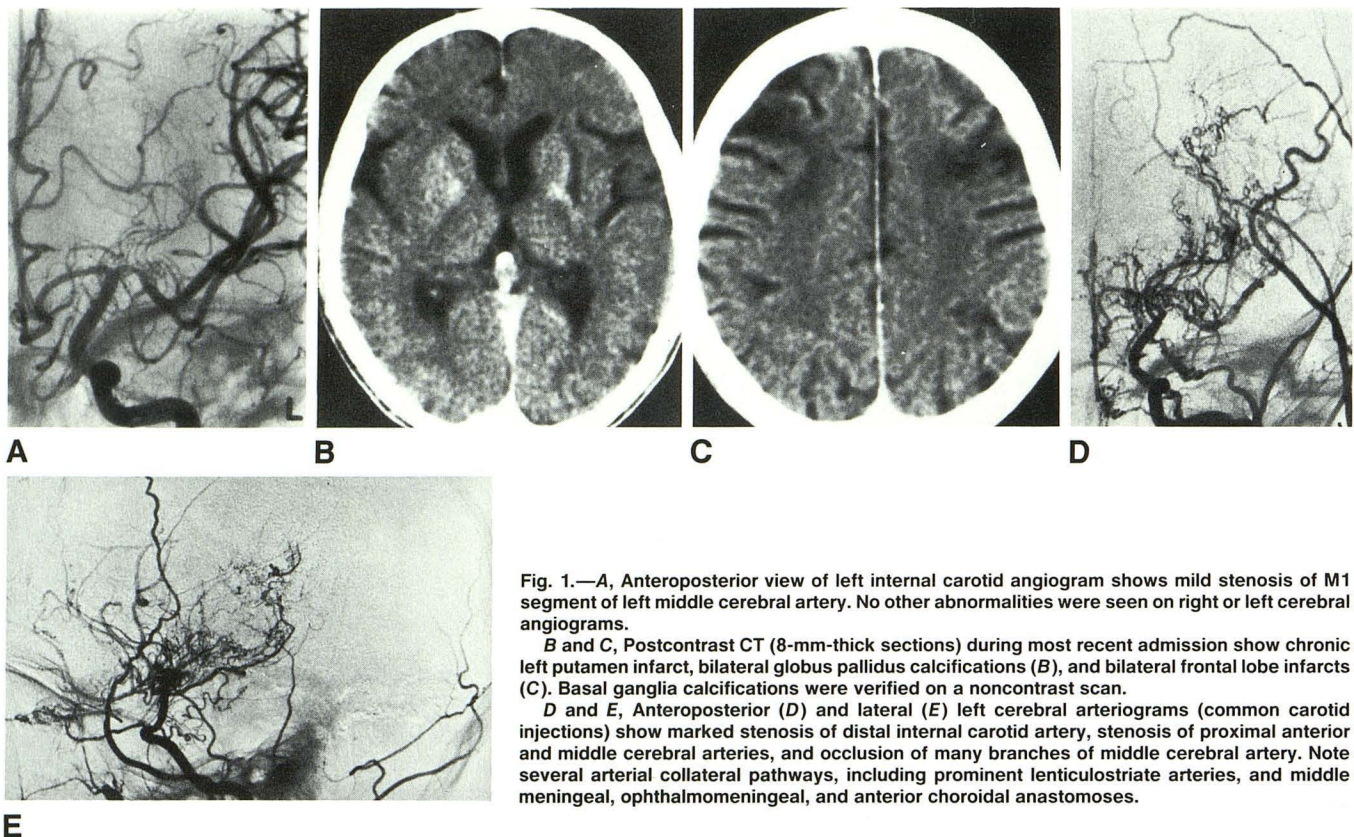


Fig. 1.—A, Anteroposterior view of left internal carotid angiogram shows mild stenosis of M1 segment of left middle cerebral artery. No other abnormalities were seen on right or left cerebral angiograms.

B and C, Postcontrast CT (8-mm-thick sections) during most recent admission show chronic left putamen infarct, bilateral globus pallidus calcifications (B), and bilateral frontal lobe infarcts (C). Basal ganglia calcifications were verified on a noncontrast scan.

D and E, Anteroposterior (D) and lateral (E) left cerebral arteriograms (common carotid injections) show marked stenosis of distal internal carotid artery, stenosis of proximal anterior and middle cerebral arteries, and occlusion of many branches of middle cerebral artery. Note several arterial collateral pathways, including prominent lenticulostriate arteries, and middle meningeal, ophthalmomeningeal, and anterior choroidal anastomoses.

cardiac origin, angiography was essential to exclude this as a cause of the bilateral cerebral infarcts. Subtle narrowing of one vessel was the only early manifestation of moyamoya; a pattern of advanced disease was obvious on the angiogram 7 years later. The progressive nature of the occlusive disease has been previously recognized [7]. These patterns correspond to stages I and IV, respectively, described by Suzuki and Kodama [3]. Unfortunately, no therapy has been of proved benefit to children with moyamoya, although both cervical ganglionectomy [3] and superficial temporal artery-middle cerebral artery anastomosis [8] have been reported to be of some benefit.

We conclude that the diagnosis of moyamoya disease should be entertained as a cause of strokes in children with Down syndrome, even in the presence of congenital heart disease.

#### REFERENCES

1. Fukushima Y, Kondo Y, Kuroki Y, et al. Are Down syndrome patients predisposed to moyamoya disease? *Eur J Pediatr* 1986;144:517-518
2. Kithara T, Okumura K, Semba A, Yamaura A, Makino H. Genetic and immunologic analysis on moyamoya. *J Neurol Neurosurg Psychiatry* 1982;45:1048-1052
3. Suzuki J, Kodama N. Moyamoya disease: a review. *Stroke* 1983;14:104-109
4. Sunder TR. Moyamoya disease in a patient with type I glycogenosis. *Arch Neurol* 1981;38:251-253
5. Ieshima A, Kisa T, Yoshino K, Takashima S, Takeshita K. A morphometric CT study of Down's syndrome showing small posterior fossa and calcifications of basal ganglia. *Neuroradiology* 1984;26:493-498
6. Pelz DM, Karlik SJ, Fox AJ, Vinuela F. Magnetic resonance imaging in Down's syndrome. *Can J Neurol Sci* 1986;13:566-569
7. Taveras JM. Multiple progressive intracranial arterial occlusions: a syndrome of children and young adults. *AJR* 1969;106:235-268
8. Amine ARC, Moody RA, Meeks W. Bilateral temporal middle cerebral artery anastomosis for moyamoya syndrome. *Surg Neurol* 1977;8:3-6