



**Providing Choice & Value**

Generic CT and MRI Contrast Agents



FRESENIUS  
KABI

CONTACT REP

**AJNR**

## **MR of Adrenoleukodystrophy: Histopathologic Correlations**

M. S. van der Knaap and J. Valk

*AJNR Am J Neuroradiol* 1989, 10 (5 suppl) S12-S14

[http://www.ajnr.org/content/10/5\\_suppl/S12.citation](http://www.ajnr.org/content/10/5_suppl/S12.citation)

This information is current as  
of July 13, 2025.

## MR of Adrenoleukodystrophy: Histopathologic Correlations

M. S. van der Knaap<sup>1</sup> and J. Valk<sup>2</sup>

Adrenoleukodystrophy (ALD) is a hereditary disorder that involves the adrenal cortex and the white matter of the CNS. The most common variant of the disease has an X-linked recessive mode of inheritance and occurs in childhood [1]. Clinical symptoms involve behavioral disturbances, mental deterioration, motor dysfunction (caused by a spastic syndrome and to a lesser extent by cerebellar ataxia), dysarthria, dysphagia, decreased hearing, decreased vision, and epileptic seizures. The disease leads to death, usually within several years after the initial manifestations. Features of adrenal insufficiency may precede, concur, or follow the neurologic symptoms. The diagnosis of ALD can be facilitated by showing adrenocortical dysfunction and an increase of very-long-chain fatty acids in serum and cultured skin fibroblasts [2, 3]. CT [4, 5] showing involvement of the cerebral white matter is helpful in making the diagnosis, but is often inconclusive. MR has been shown to be more sensitive and specific

in this respect [5–7]. In this case report, the ability of MR to reflect the histopathologic abnormalities is illustrated in two ALD patients.

### Case Reports

#### Case 1

In a 6-year-old boy, failure to make progress with learning and increasing behavioral problems were noted during the past year. There were signs of poor coordination and impaired vision. A week before the MR, he was admitted to the hospital after a number of seizures. Physical examination showed an ill-looking, skinny boy with a mild generalized increased pigmentation of the skin. The patient was confused and had a slight depression of consciousness. The vision was decreased. Plantar reflexes were extensor on both sides. No other abnormalities were noted. CT scan of the brain showed bilateral abnormalities in the occipital region (Fig. 1A). Brain tumor

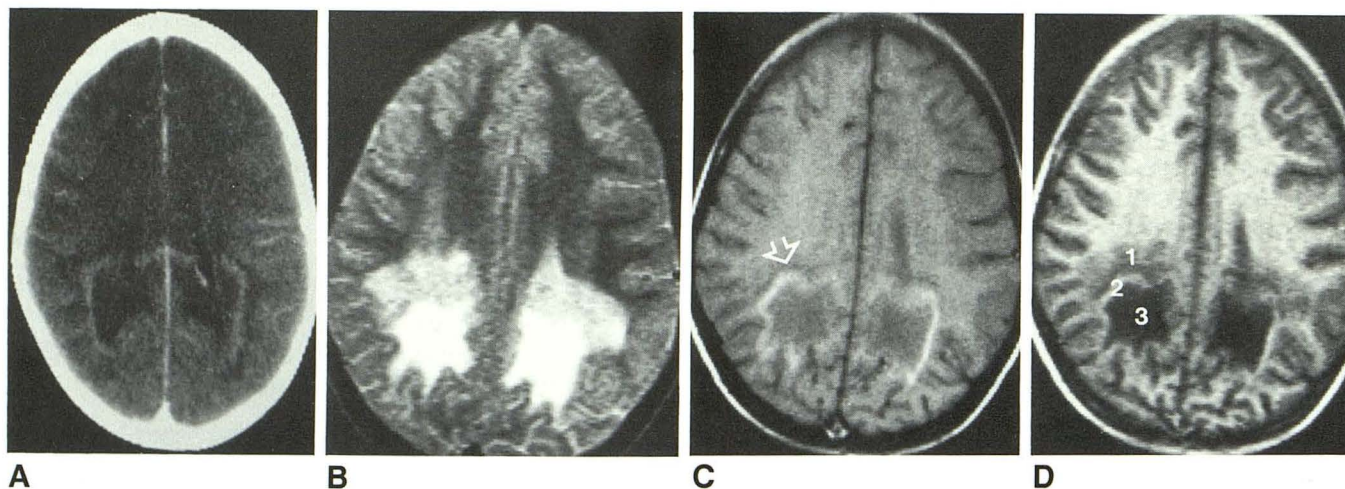


Fig. 1.—A, CT scan shows bilateral occipital hypodense areas with rim enhancement after contrast administration. B, MR image, spin-echo 3000/128/2, shows bilateral white matter lesion in occipital region. In lesion, two areas are distinguished: a posterior very hyperintense area and an anterior less hyperintense area. C, MR image, spin-echo 405/32/6, is obtained after injection of Gd-DTPA. Arrow points to rim of enhancement within border of lesion. D, In Gd-DTPA enhanced image, inversion-recovery 2400/640/32/2, three zones are discernible: a slightly hypointense outer zone (1), a zone showing enhancement (2), and a very hypointense inner area (3).

Received November 18, 1987; revision requested January 29, 1988; final revision received April 5, 1988; accepted April 13, 1988.

<sup>1</sup> Department of Child Neurology, University Hospital Utrecht, Catharijnesingel 101, 3511 GV Utrecht, the Netherlands.

<sup>2</sup> Department of Diagnostic Radiology and Neuroradiology, Free University Hospital Amsterdam, P.O. Box 7057, 1007 MB Amsterdam, the Netherlands. Address reprint requests to J. Valk.



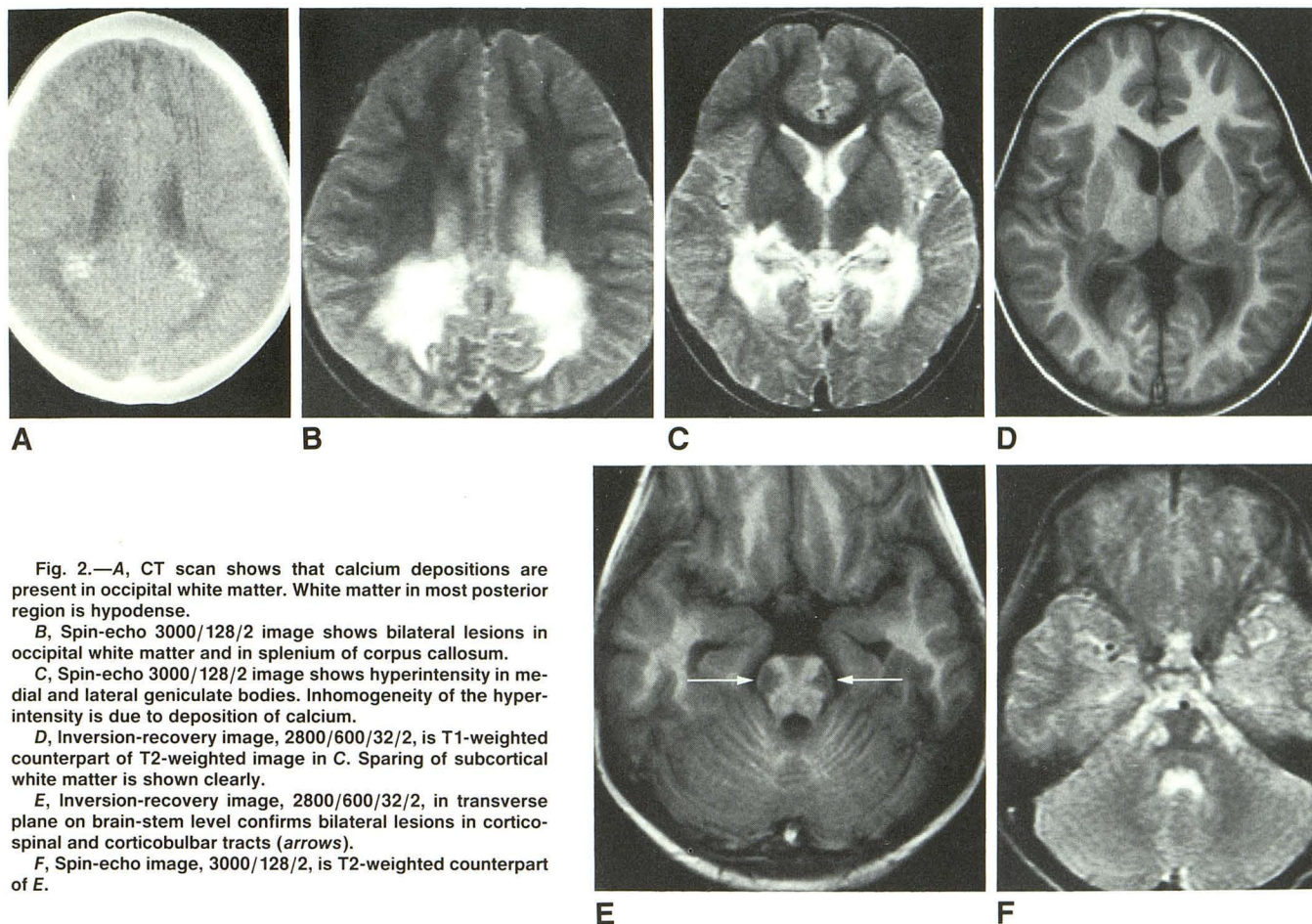


Fig. 2.—A, CT scan shows that calcium depositions are present in occipital white matter. White matter in most posterior region is hypodense.

B, Spin-echo 3000/128/2 image shows bilateral lesions in occipital white matter and in splenium of corpus callosum.

C, Spin-echo 3000/128/2 image shows hyperintensity in medial and lateral geniculate bodies. Inhomogeneity of the hyperintensity is due to deposition of calcium.

D, Inversion-recovery image, 2800/600/32/2, is T1-weighted counterpart of T2-weighted image in C. Sparing of subcortical white matter is shown clearly.

E, Inversion-recovery image, 2800/600/32/2, in transverse plane on brain-stem level confirms bilateral lesions in corticospinal and corticobulbar tracts (arrows).

F, Spin-echo image, 3000/128/2, is T2-weighted counterpart of E.

was suspected, and treatment with corticosteroids and antiepileptic drugs was started with remarkable success. The boy regained clear consciousness and the generalized illness improved.

MR was performed on a 0.6-T imaging system.\* T2-weighted spin-echo (SE) images were obtained in the transverse plane (Fig. 1B). After injection of gadolinium-DTPA (Gd-DTPA), T1-weighted SE and inversion-recovery (IR) images were made (Figs. 1C and 1D).

On the T2-weighted images (Fig. 1B), a hyperintense lesion was seen bilaterally in the occipital white matter. The subcortical U-fibers seem to be relatively, but not completely, spared. Within the lesion, two zones were distinguished. In the brain stem, small lesions were seen bilaterally, corresponding to the location of the corticospinal tracts. A small lesion was also seen on the left side in the cerebellum.

After injection of Gd-DTPA, the IR images (Fig. 1D) clearly showed three zones in the lesion, but on closer examination these zones can be seen also in Figure 1C.

#### Case 2

In a 6-year-old boy, changes in behavior and signs of impaired hearing were noted over the past 6 months. A left-sided hemiparesis caused increased clumsiness and difficulty in walking. Mental deterioration was suspected. On admission, physical examination showed no abnormalities, with the exception of decreased vision and a spastic hemiparesis with hyperreflexia and an extensor plantar reflex on the left side. A CT scan showed depositions of calcium bilaterally in the

occipital white matter (Fig. 2A). MR was requested because a degenerative neurologic disorder was assumed.

T2-weighted images (Figs. 2B, 2C, and 2F) and T1-weighted images (Figs. 2D and 2E) were obtained. Gd-DTPA was not used. On the T2-weighted images (Figs. 2B and 2C), inhomogeneous hyperintense white matter lesions were seen bilaterally in the occipital regions, corpus callosum, and the medial and lateral geniculate bodies. The lesions also were present in the corticospinal tracts in the brain stem (Figs. 2E and 2F).

#### Discussion

The basic metabolic defect in ALD is an impaired capacity to degrade very-long-chain fatty acids, which is caused by a peroxisomal defect in beta-oxidation [8–10]. The increasing accumulation of fatty acids with a very long chain probably decreases the stability of the myelin membrane, finally leading to demyelination. Histologically [1], ALD is characterized by a widespread demyelination of the white matter. The demyelination is not focal but starts bilaterally in the occipital region extending across the splenium of the corpus callosum. Gradually the demyelinating process spreads outward and forward as a confluent lesion, affecting also the parietal, temporal, and finally the frontal white matter. The subcortical U-fibers are relatively spared. The cerebellar white matter and the cerebellar pedunculi are usually involved. Demyelination in the

\* Teslacon II, Technicare, Solon, OH.



brain stem and spinal cord is confined to the corticospinal and corticobulbar tracts.

In the white matter lesions, the big central area consists of a dense mesh of glial fibrils and scattered astrocytes. Oligodendroglia, axons, and myelin are absent. There is no evidence of an active process. Sometimes cavitated areas and small deposits of calcium are seen. Next to the central area is a zone of active inflammation characterized by numerous perivascular inflammatory cells. In this zone, many myelin sheaths are lost with preservation of the axons. The outer zone of the white matter lesion shows evidence of active destruction of myelin, but there are no perivascular inflammatory cells. In this zone, more myelin is present than in the inner two zones. The cytoarchitecture of the cerebral cortex is normal, except in more advanced cases in which neuronal loss and gliosis may be seen (especially in the occipital region, where the demyelinating lesion may not spare the subcortical U-fibers and may be contiguous with the deep layers of the cortex). Electron microscopy [1, 11] show that many macrophages contain distinctive lamellar cytoplasmic inclusions. These are characteristic for ALD. In biochemical analysis, these inclusions appear to consist of cholesterol esters with very-long-chain fatty acids [12].

In our two patients, the pathologic abnormalities of ALD are reflected in the pattern of abnormalities shown by MR. The localization of the pathologic process is shown in the occipital white matter with relative sparing of the U-fibers, in the splenium of the corpus callosum, medial and lateral geniculate bodies, cerebellar white matter, and the corticospinal tracts in the brain stem. The clinical symptomatology in ALD corresponds to the location of these lesions. Decreased vision is caused by the lesion in the optic radiations and the lateral geniculate bodies; involvement of the medial geniculate bodies and temporal white matter is associated with decreased hearing; and the spastic paresis results from involvement of the pyramidal tracts.

Histologic data correlate well with MR images. In case 1, the outer zone (1 in Fig. 1D) corresponds to the zone of active demyelination with partial loss of myelin and without

inflammation. The middle zone enhances with Gd-DTPA (2 in Fig. 1D) because of blood-brain barrier breakdown and corresponds to the area of inflammation. In the big central area (3 in Fig. 1D) of the lesion, the destructive process is burnt out and a mass of fibrillary gliosis is left. Also, calcium deposition, which may be present in ALD, can be shown (Fig. 2C). The MR examination in these cases is highly suggestive of ALD, and a definite diagnosis can be made without further studies. Administration of Gd-DTPA is helpful in providing information about the histology of the lesion, but it is not necessary for making the diagnosis.

## REFERENCES

1. Schaumburg HH, Powers JM, Raine CS, Suzuki K, Richardson EP. Adrenoleukodystrophy. *Arch Neurol* **1975**;32:577-591
2. Moser HW, Moser AB, Frayer KK, et al. Adrenoleukodystrophy: increased plasma content of saturated very-long-chain fatty acids. *Neurology* **1981**;31:1241-1249
3. Moser HW, Moser AB, Kawamura N, et al. Adrenoleukodystrophy: elevated C26 fatty acids in cultured skin fibroblasts. *Ann Neurol* **1980**;7:542-549
4. O'Neill BP, Forbes GS. Computerized tomography and adrenoleukomyeloneuropathy. Differential appearance in disease subtypes. *Arch Neurol* **1981**;38:293-296
5. Volkow ND, Patchell L, Kulkarni MV, Reed K, Simmons M. Adrenoleukodystrophy: imaging with CT, MRI and PET. *J Nucl Med* **1987**;28:524-527
6. Bewermeyer H, Bamborschke S, Ebhardt G, Hünemann B, Heiss WD. MR imaging in adrenoleukomyeloneuropathy. *J Comput Assist Tomogr* **1985**;9:793-796
7. Kumar AJ, Rosenbaum AE, Naidu S, et al. Adrenoleukodystrophy: correlating MR imaging with CT. *Radiology* **1987**;165:497-504
8. Brown FR, Chen WW, Kirschner DA, et al. Myelin membrane from adrenoleukodystrophy brain white matter—biochemical properties. *J Neurochem* **1983**;41:341-348
9. Moser HW. Peroxisomal disorders. *J Pediatr* **1986**;108:89-91
10. Goldfischer S, Collins J, Rapin I, et al. Peroxisomal defects in neonatal-onset and X-linked adrenoleukodystrophies. *Science* **1985**;227:67-70
11. Powell H, Tindall R, Schultz P, Paa D, O'Brien J, Lampert P. Adrenoleukodystrophy, electron microscopic findings. *Arch Neurol* **1975**;32:250-260
12. Igarashi M, Schaumburg HH, Powers J, Kishimoto Y, Kolodny E, Suzuki K. Fatty acid abnormality in adrenoleukodystrophy. *J Neurochem* **1976**;26:851-860