



Discover Generics

Cost-Effective CT & MRI Contrast Agents



FRESENIUS
KABI

WATCH VIDEO

AJNR

Air CT cisternography in the diagnosis of vascular loop causing vestibular nerve dysfunction.

F Esfahani and K D Dolan

AJNR Am J Neuroradiol 1989, 10 (5) 1045-1049

<http://www.ajnr.org/content/10/5/1045>

This information is current as
of June 19, 2025.

Air CT Cisternography in the Diagnosis of Vascular Loop Causing Vestibular Nerve Dysfunction

Fraydoon Esfahani^{1,2}
Kenneth D. Dolan¹

Considerable interest has developed in otology concerning the relationship between the vascular loop and compression of the eighth nerve, producing vertigo. Several authors have described the radiographic findings relative to the anatomy of these vascular loops. Few previous articles have dealt with cases that have had surgical confirmation or repair of the defect. Our presentation concerns 27 patients who were studied by air CT cisternography of the cerebellopontine angle cistern and internal auditory canal followed by surgical repair. We postulate dampened pulsation as the reason for being able to visualize the vessels on the air study. The diversity of vessel-eighth nerve defects is illustrated.

Compression of the vestibular nerve by a vascular loop should be considered one of the causes of intractable vertigo and motion intolerance and is a differential diagnosis in Meniere disease. Air CT cisternography is useful in diagnosing this condition in patients who do not respond to medical treatment.

AJNR 10:1045-1049, September/October 1989

Mechanical cross-compression of cranial nerves is a well-known entity causing functional disturbances. Clinical manifestations depend on the specific nerve being compressed. Compression of the fifth cranial nerve in the posterior fossa causes trigeminal neuralgia (tic douloureux) [1-3], compression of the seventh causes facial hemispasm [4, 5], and compression of the ninth may result in glossopharyngeal neuralgia [6]. Recently, a similar phenomenon has been described for the eighth nerve. This condition gives rise predominantly to vertigo [7-11]. We report a series of patients with intractable vertigo due to compression of the vestibular nerve, in whom air CT cisternography was used as a diagnostic procedure before surgical microvascular decompression.

Materials and Methods

Twenty-seven patients who had air CT cisternography and subsequently underwent surgery comprise the patient population. They were selected for air CT cisternography by the otologist because other causes of severe vertigo had been excluded or other treatment methods had failed. Surgical confirmation of the vascular loop found on air CT cisternography was also available.

The 10 men and 17 women were 22-62 years old (average age, 45 years). All patients were evaluated thoroughly by history, physical examination by a neurologist, audiometry, electronystagmography, and finally air CT cisternography. The patient data are summarized in Table 1. The patients' symptomatology was related to vestibular nerve dysfunction consisting of spells of vertigo ranging from a few months to several years in duration, and was primarily in the form of motion intolerance. The symptoms, usually precipitated by abrupt turning of the head or body, especially by moving the head while walking, were dizziness, disequilibrium, nausea, and, at times, vomiting. Some patients reported aural fullness and vague symptoms on the involved side. Four patients also had a unilateral decrease in hearing and three had tinnitus in the course of the disease. Many of these patients were diagnosed

Received August 22, 1988; revision requested October 17, 1988; final revision received January 17, 1989; accepted January 24, 1989.

¹ Department of Radiology, The University of Iowa College of Medicine, Iowa City, IA 52242. Address reprint requests to K. D. Dolan.

² Present address: Department of Radiology, Shiraz University School of Medicine, Shiraz, Iran.

0195-6108/89/1005-1045

© American Society of Neuroradiology

TABLE 1: Air CT Cisternography in the Diagnosis of Eighth Nerve Dysfunction

Case No.	Age	Gender	Symptoms/Duration	Air CT Cisternography	Surgical Findings	Follow-up
1	22	F	Vertigo, nausea & vomiting/6 mo	R: loop crossing NVB at CPA; L: neg	Loop compressing eighth nerve at root entry zone	Symptom-free at 11 mo
2	24	F	Vertigo/3 mo	R: compression of NVB at CPA; L: not done	Artery pulsating against eighth nerve in CPA & IAC	Improvement to 13 mo; symptoms returned after motor vehicle accident
3	29	M	Vertigo, disequilibrium/6 mo	R: neg; L: filling defect in IAC simulating acoustic neuroma	Arachnoid adhesion & vessel hitting against vestibular nerve in IAC	Symptom-free at 1 yr
4	30	F	Vertigo, disequilibrium/8 mo	R: small loop, no contact; L: large loop at porus	L: loops pressing eighth nerve at porus	Symptom-free at 7 mo
5	31	M	Vertigo, disequilibrium, nausea & vomiting/6 yr	R: loop superimposed on NVB at CPA; L: not done	Vein compressing eighth nerve at root entry zone	Symptom-free at 1 yr
6	33	F	Vertigo, nausea & vomiting/2 yr	Bilateral: loop crossing NVB at CPA	L: artery pressing against eighth nerve in CPA	50% improvement at 4 mo
7	33	F	Vertigo, disequilibrium, nausea/10 yr	R: loop superimposed on NVB at porus; L: neg	R: two loops—one large at porus, one small at root entry zone	Symptom-free at 14 mo
8	34	F	Disequilibrium, nausea & vomiting/8 yr	R: pos; L: not done	Compression of loop at CPA	Recurrence at 1 yr
				R: neg; L: loop at CPA	Eighth nerve section, cautery of loop pressing on eighth nerve in IAC	Symptom-free at 1 mo
9	35	F	Vertigo & disequilibrium/10 yr	R: neg; L: loop crossing NVB at CPA	Loop compressing eighth nerve at CPA	Improvement at 6 mo
10	40	M	Vertigo, disequilibrium, nausea & vomiting, decreased hearing in R ear/3 yr	R: loop at CPA crossing NVB; L: neg	Compression of eighth nerve at root entry zone	Marked improvement at 7 mo
11	40	F	Vertigo/9 mo	R: vessel twisting around NVB in CPA; L: neg	Loop between seventh & eighth nerves at CPA	Symptom-free at 2 mo
12	41	F	Disequilibrium/1 yr	R: suboptimal; L: loop crossing NVB at CPA	L: loop between seventh & eighth nerves	Symptom-free at 5 mo
13	42	M	Vertigo & vomiting/5 mo	R: loop crossing NVB at CPA; L: neg	Loop pressing eighth nerve at root entry zone	50% improvement at 10 mo
14	42	F	Vertigo/3 mo	R: neg; L: loop at porus	L: eighth nerve compressed at root entry zone	Symptom-free at 6 mo
15	42	F	Pulsatile tinnitus in L ear/3 yr	R: neg; L: loop at porus	Loop between seventh & eighth nerves, cautery of vessel, & eighth nerve section	Improvement at 1 mo; occasional tinnitus
16	42	M	Vertigo, nausea & disequilibrium/5 yr	R: neg; L: loop crossing NVB at porus	Compression of eighth nerve at root entry zone	Symptom-free at 4 mo
17	44	M	Vertigo/1.5 yr	R: neg; L: loop superimposed on NVB at CPA	Eighth nerve section, loop at porus	Marked improvement at 11 mo
18	45	F	Disequilibrium & tinnitus in L ear/5 mo	R: neg; L: loop crossing NVB at porus	Eighth nerve compressed at CPA	Symptom-free at 1 yr
19	49	F	Vertigo & disequilibrium/3 mo	R: loop curving around NVB; L: loop at porus, no contact with NVB	Loop compressing eighth nerve at CPA	Improvement at 14 mo
20	54	F	Vertigo, nausea & vomiting/10 yr	Bilateral at CPA	Loop compressing L eighth nerve at IAC	Improvement at 15 mo
21	56	F	Vertigo & disequilibrium/4 yr	R: loop crossing NVB at porus; L: neg	Loop compressing eighth nerve at CPA	50% improvement at 1 yr
22	56	M	Vertigo, nausea & vomiting/1.5 yr	R: loop crossing NVB at CPA; L: neg	Loop compressing eighth nerve at root entry zone	Symptom-free at 3 mo
23	57	F	Vertigo, disequilibrium, decreased hearing in L ear/2 yr	R: not done; L: loop crossing NVB at porus	Compression of arterial loop and a venous branch at root entry zone	Symptom-free at 6 mo
24	57	M	Disequilibrium, tinnitus/7 mo	R: loop curving around NVB at CPA; L: not done	Compression of loop at root entry zone	Symptom-free at 1 yr

Table 1 continues

TABLE 1—Continued

Case No.	Age	Gender	Symptoms/Duration	Air CT Cisternography	Surgical Findings	Follow-up
25	59	F	Vertigo, nausea, hearing loss in L ear/4 yr	R: not done; L: compression at CPA	Compression of loop at porus	90% improvement at 3 yr
26	62	M	Vertigo, nausea, vomiting, tinnitus, decreased hearing in L ear/2 yr	R: not done; L: compression of NVB at porus	Loop compressing eighth nerve at porus	Improvement at 2 mo
27	62	M	Vertigo/3 mo	R: loop superimposed on eighth nerve at CPA; L: neg	Compression of loop at CPA	Marked improvement at 25 mo

Note.—mo = month(s); yr = year(s); R = right; L = left; NVB = neurovascular bundle; CPA = cerebellopontine angle; neg = negative; pos = positive; IAC = internal auditory canal; MVA =

early in their disease as having vestibular Meniere disease; however, they did not respond to the usual medical management for this condition. In four cases, endolymphatic shunt surgery was performed without benefit. Audiometric studies demonstrated normal or symmetric hearing except in four cases. (In most of the cases, electronystagmography showed canal paresis.)

Air CT cisternography was performed as the final step in the diagnostic evaluation. After the introduction of 5 ml of air via a lumbar puncture, adjacent 1-mm-thick axial images of each cerebellopontine angle were obtained with a Siemens DRH CT scanner while the patient was in the lateral decubitus position. These views included the neurovascular bundle in the internal auditory canals. Twenty milliliters of iohexol (300 mg/ml) were injected IV to enhance the vascular structures during the study of each side. After delineation of the offending vascular loop, the patient underwent microvascular decompression, which consisted of mobilizing the vessel from the eighth cranial nerve with dissection, using either the middle cranial fossa or retrosigmoid approach, and placing Teflon felt pads between the vascular loop and the nerve. The patients were followed for variable periods of time, ranging from 2 to 25 months.

Results

We reviewed 100 other previous air CT cisternographic studies to exclude an acoustic neuroma. These patients had

sensorineural hearing loss, but episodic vertigo was not a symptomatic complaint. An abnormal vascular loop was found in only one of these studies and is included in this presentation (case 3). This patient had both sensorineural hearing loss and severe vertigo.

Twenty-seven patients had air CT cisternography and subsequently underwent surgery; 21 of these had bilateral air CT cisternographic studies in which a vascular loop was detected contacting the eighth cranial nerve only on the affected side at the cerebellopontine angle, porus acusticus, or inside the internal auditory canal. The radiographic findings showed cross-compression of the neurovascular bundle at one or more points (Fig. 1), with the vascular loop twisting or coiling around the eighth nerve or, at times, superimposition of nerve on vessel or vice versa (Fig. 2). The loop also was seen as a filling defect at the porus acusticus (Fig. 3). In four of these cases, bilateral vascular loops were detected. However, surgery was performed on only one side on the basis of: (1) the patient's signs and symptoms, (2) the proximity of the loop to the neurovascular bundle as seen on air CT cisternography, and (3) the size of the loop detected on air CT cisternography (Fig. 4). Large loops tend to suggest ectasia and seem more frequently to compress the neurovascular bundle. Specific

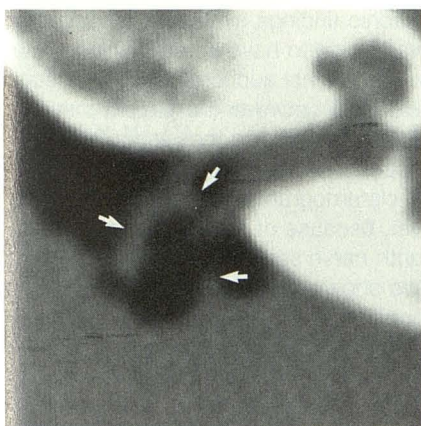


Fig. 1.—Case 12: Left air CT cisternogram shows vascular loop (arrows) crossing neurovascular bundle as it emerges from internal auditory canal.

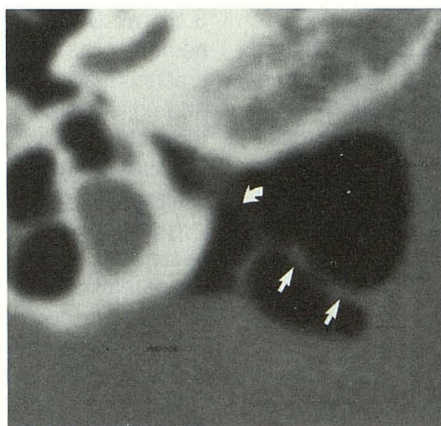


Fig. 2.—Case 13: Right air CT cisternogram shows vascular loop with its proximal limb superimposed on neurovascular bundle in cerebellopontine angle (straight arrows). Part of neurovascular bundle is also visible in inferior portion of internal auditory canal (curved arrow).

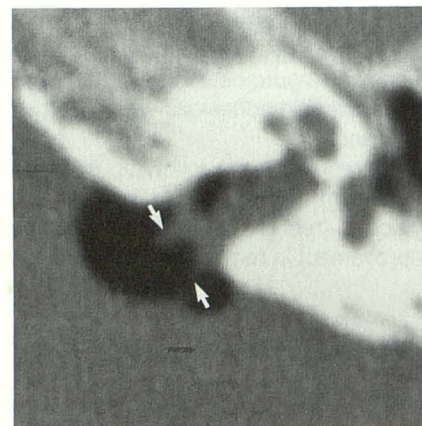


Fig. 3.—Case 26: Left air CT cisternogram shows vascular loop at porus acusticus protruding into internal auditory canal (arrows) and contacting neurovascular bundle.

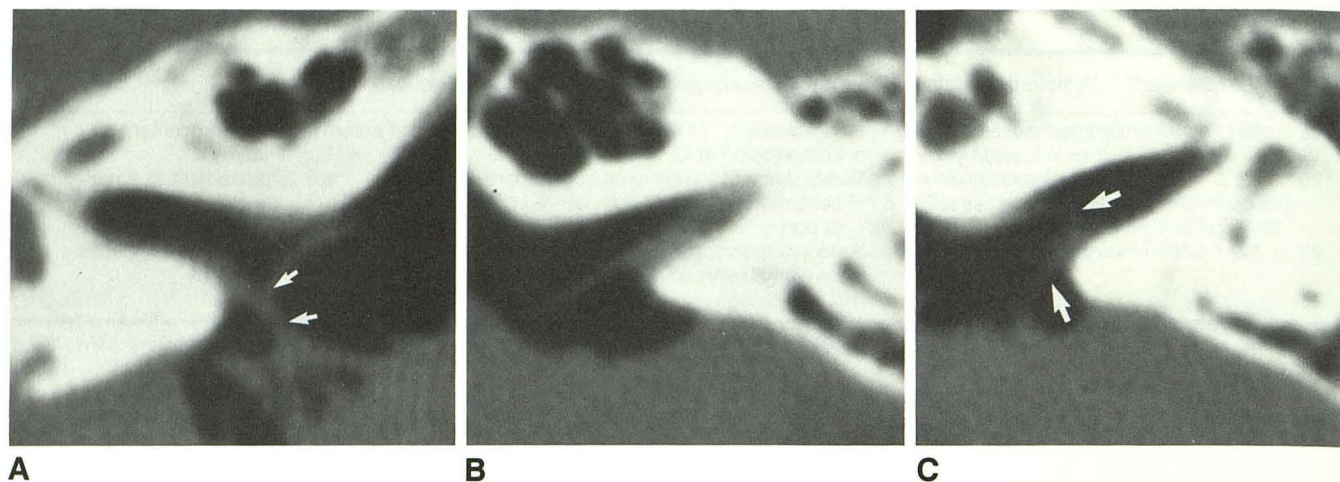


Fig. 4.—Case 19: Bilateral air CT cisternography.

A, Right air CT cisternogram shows loop contacting neurovascular bundle at cerebellopontine angle cistern (arrows).

B and C, Left air CT cisternogram shows loop and neurovascular bundles at different levels (B is higher). Loop, which is not in contact with neurovascular bundle, is seen at porus acusticus (arrows).

dolichoectasia of the inferior cerebellar artery may also produce compression of the neurovascular bundle. Clinically, canal paresis (decreased response to cold water caloric testing) and/or "aural fullness" (a sensation of middle ear pressure) also were used to determine the side on which the operation would be done.

Unilateral air CT cisternography was performed in six cases on the side suspected of pathologic changes. These six studies also showed vascular loops contacting the nerve, which were confirmed intraoperatively.

In case 8, the air CT cisternogram showed a right-sided vascular loop. Surgery was performed, but the patient's symptoms persisted and she was reevaluated 1 year later by air CT cisternography on the left side, which revealed a contralateral vascular loop. Subsequently surgery on the left side confirmed the abnormal vascular loop. The loop was cauterized and the eighth nerve was sectioned, as the patient had been deaf since childhood.

In case 3, the interpretation of the air CT cisternogram was of acoustic neuroma, whereas at surgery a large arterial loop with arachnoid adhesions was noted inside the internal auditory canal.

The results of the follow-up evaluations in these patients are shown in Table 1. As can be seen, 14 patients were symptom-free for up to 12 months and 13 had significant improvement in terms of resuming their daily activities.

Discussion

The concept of vascular cross-compression of cranial nerves in the posterior fossa is well accepted in regard to trigeminal, facial, and glossopharyngeal nerves. A similar mechanism has been proposed for vestibulocochlear dysfunction [7–14]. Microvascular decompression has been performed, aimed at separating the arterial loop from the vestib-

ular nerve [7, 8, 10–12]. Physicians have been slow to recognize cross-compression of the vestibular nerve by the arterial loop, because of the lack of a specific diagnostic method of identifying the diseased vessel [7–15] and a lack of a constant pattern on audiometric and vestibular function studies [16]. More recently, Rettinger et al. [17], using air CT cisternography, identified 20 patients with vestibulocochlear dysfunction related to compression by the vascular loop in the cerebellopontine angle; 19 of these patients improved after vascular decompression.

In our current series, there was a fairly good correlation between the symptomatology and the finding of abnormal vessels contacting the eighth cranial nerve, air CT cisternography, and surgical exploration. In cases 7 and 23, additional vessels were detected surgically that had not been demonstrated by air CT cisternography. The surgical procedure generally relieved the patient's symptoms. Although in case 3 the air CT cisternographic findings simulated an acoustic neuroma, the patient was found to have an arterial loop with arachnoid adhesions in the internal auditory canal, thus supporting the causal relationship between the patient's symptoms and the vascular loop compressing the vestibular nerve. In cases 8 and 17, preoperative diagnoses of vascular loop were made on air CT cisternograms and were confirmed intraoperatively; however, because of severe hearing loss or absence of hearing, eighth-nerve sectioning was performed.

Anatomic studies have shown that an arterial loop is constant in the cerebellopontine angle, referred to by Mazzoni [18] as the cerebellar loop. The source of this loop in 80% of patients is said to be the anterior inferior cerebellar artery, in 17% an accessory anterior inferior cerebellar artery, and in 3% a branch of the posterior inferior cerebellar artery [18]. In 40–67% of specimens, the convexity of the loop may enter the internal auditory canal [18–20].

The pathogenesis of vascular compression of cranial nerves at the cerebellopontine angle is thought to be related to aging

and arterial elongation due to arteriosclerosis, although one-third of our patients were less than 40 years old [21]. Jannetta et al. [7] also mention sagging of the hindbrain with aging, in addition to arterial elongation resulting in abnormal contact with the vestibular nerve, which explains the symptomatology. The transitional zone between central and peripheral myelin may be variable and may be located in the cerebellopontine angle, at the porus acusticus, or inside the internal auditory canal [22]. The vestibular nerve is known to have a long course [23], a considerable portion of which is covered by a central area of myelin. Distally the nerve might be deficient in myelin, making it vulnerable to injury by pulsation of a contacting vessel.

Experimental phantom studies by Rettinger et al. [17] simulating the vascular anatomy of the cerebellopontine angle indicate that a freely pulsating vessel cannot be seen on air CT cisternography, whereas contacting or fixed vessels are visualized and are the ones that may be diseased. Because of this complex interplay of causal factors, it is not surprising that there is no constant relationship between a patient's symptomatology and the exact anatomicopathologic configuration of the vascular loop found on postmortem examinations.

In summary, compression of the vestibular nerve by a vascular loop should be considered as one of the causes of intractable vertigo and motion intolerance as a differential diagnosis to the classic symptom complex of Meniere disease. Our study indicates that air CT cisternography is a useful and definitive method for diagnosing this condition in patients who do not respond to medical treatment. After such a diagnosis, appropriate surgical treatment results in complete or significant alleviation of the symptoms in a great majority of patients.

ACKNOWLEDGMENT

The cases in this report are from the Otology Service of Brian F. McCabe, who also initially reviewed the article.

REFERENCES

1. Dandy WE. Concerning the cause of trigeminal neuralgia. *Am J Surg* 1934;24:447-455
2. Gardner WJ. The mechanism of tic douloureux. *Trans Am Neurol Assoc* 1953;78:168-173
3. Gardner WJ, Miklos MV. Response of trigeminal neuralgia to "decompression" of sensory route. Discussion of cause of trigeminal neuralgia. *JAMA* 1959;170:1773-1776
4. Ehni G, Woltman MW. Hemifacial spasm. Review of one hundred and six cases. *Arch Neurol Psychiatry* 1945;53:205-211
5. Jannetta PJ. The cause of hemifacial spasm—definitive microsurgical treatment at the brain stem in 31 patients. *Trans Am Acad Ophthalmol Otolaryngol* 1975;80:319-322
6. Laha RK, Jannetta PJ. Glossopharyngeal neuralgia. *J Neurosurg* 1977;47:316-320
7. Jannetta PJ, Moller MB, Moller AR. Disabling positional vertigo. *N Engl J Med* 1984;310:1700-1705
8. Bertrand RA, Molina P, Hardy J. Vestibular syndrome and vascular anomaly in the cerebello-pontine angle. *Acta Otolaryngol (Stockh)* 1977;83:187-194
9. McCabe BF, Harker LA. Vascular loop as a cause of vertigo. *Ann Otol Rhinol Laryngol* 1983;92:542-543
10. Jannetta PJ. Neurovascular cross-compression in patients with hyperactive dysfunction symptoms of the eighth cranial nerve. *Surg Forum* 1975;26:467-469
11. Leclercq TA, Hill CL, Grisoli F. Retromastoid microsurgical approach to vascular compression of the eighth cranial nerve. *Laryngoscope* 1980;90:1011-1017
12. Jannetta PJ. Neurovascular compression in cranial nerve and systemic disease. *Ann Surg* 1980;192:518-524
13. Kanzaki J, Koyama E. Vascular loops in internal auditory canal as possible cause of Meniere's disease. *Auris Nasus Larynx (Tokyo)* 1986;13[suppl 11]:S105-S111
14. Brookler KH, Hoffman RA. Acoustic neuroma or vascular loop? *Am J Otolaryngol* 1979;1:32-36
15. Nadol JB Jr. Disabling positional vertigo. *N Engl J Med* 1984;311:1053-1054
16. Applebaum EL, Valvasorri G. Internal auditory canal vascular loops: audiometric and vestibular system findings. *Am J Otol* 1985;6[suppl]:110-113
17. Rettinger G, Wigand ME, Kalender W. Imaging of nerves and vessels of the cerebellopontine angle: a comparison between computertomographic and surgical findings. *Electromed* 1983;51:60-65
18. Mazzoni A. Internal auditory canal. Arterial relations at the porus acusticus. *Ann Otol* 1969;78:797-814
19. Sunderland S. The arterial relations of the internal auditory meatus. *Brain* 1945;68:23-27
20. Grant JL, Martin R, Rhoton AL Jr. Anatomical relationship of anterior inferior cerebellar artery and VIIth and VIIIth cranial nerves. *Surg Forum* 1979;30:429-431
21. Sunderland S. Neurovascular relations and anomalies at the base of the brain. *J Neurol Neurosurg Psychiatry* 1948;11:243-257
22. Lang J. Anatomy of the brainstem and the lower cranial nerves, vessels, and surrounding structures. *Am J Otol* 1985;6[suppl]:1-19
23. Lang J. Facial and vestibulocochlear nerve, topographic anatomy and variations. In: Samii M, Jannetta PJ, eds. *The cranial nerves. Anatomy, pathology, pathophysiology, diagnosis, treatment*. New York: Springer-Verlag, 1981:363-377