



Discover Generics

Cost-Effective CT & MRI Contrast Agents



WATCH VIDEO

AJNR

Subdural and Epidural Empyemas: MR Imaging

Karen Weingarten, Robert D. Zimmerman, Richard D. Becker,
Linda A. Heier, Alison B. Haines and Michael D. F. Deck

AJNR Am J Neuroradiol 1989, 10 (1) 81-87
<http://www.ajnr.org/content/10/1/81>

This information is current as
of June 18, 2025.

Subdural and Epidural Empyemas: MR Imaging

Karen Weingarten¹
 Robert D. Zimmerman¹
 Richard D. Becker^{1,2}
 Linda A. Heier¹
 Alison B. Haimes¹
 Michael D. F. Deck¹

The MR images of six patients with extraaxial empyemas (five subdural and four epidural) were reviewed and compared with CT scans. MR demonstrated convexity and interhemispheric collections, which were mildly hyperintense relative to CSF and hypointense relative to white matter on short TR pulse sequences and hyperintense relative to CSF and white matter on long TR pulse sequences, allowing distinction from sterile effusions and most chronic hematomas. A hypointense rim, representing displaced dura, was depicted at the interface between the lesion and brain in epidural empyemas, a feature absent in subdural empyemas. Inflammation-induced parenchymal abnormalities, including edema, mass effect, and reversible cortical hyperintensity, were well depicted on MR imaging. MR was superior to CT in demonstrating the presence, nature, and extent of these lesions in all cases.

Because early and accurate diagnosis will significantly improve the prognosis of these serious infections, MR is preferred to CT for patients in whom an acute intracranial infection is suspected.

Subdural and epidural empyemas are uncommon extraaxial lesions, accounting for approximately 20–33% of all intracranial infections [1, 2]. The majority occur in the setting of sinusitis, have a fulminant clinical course, and require prompt diagnosis and emergent neurosurgical intervention [3–6]. Less often, they occur secondary to infection of a posttraumatic extraaxial hematoma or postcraniotomy cavity and have a prolonged, indolent course, but nonetheless require surgical drainage for proper management [7, 8]. Several authors have reported the failure of CT to reliably corroborate or exclude an acute extraaxial empyema [7, 9–11]; others have stressed that, while the empyema can be small and difficult, but not impossible, to visualize, the diagnosis should be suspected when, in the proper clinical setting, unexplained holohemispheric edema and mass effect are visualized on CT [12–15]. We present the MR features of six patients with extracerebral empyemas and evaluate the efficacy of MR imaging in comparison with that of CT for the initial diagnosis and follow-up of these lesions. The role of MR imaging in patients suspected of harboring an extraaxial empyema is discussed.

Materials and Methods

The CT and MR studies of six patients with surgically proved extraaxial empyemas were reviewed retrospectively. Two patients had subdural empyemas exclusively, one patient had an epidural empyema, and three patients had empyemas in both compartments. The study included four male and two female patients 9–32 years old (average age, 22 years).

Within 24 hr of presentation, all patients had both a CT and MR scan. In five patients, a contrast-enhanced CT scan was obtained. In one patient, only a nonenhanced CT scan was obtained. During the course of illness, all patients had at least one noncontrast CT scan, one contrast-enhanced CT scan, and one MR scan. In three patients, both serial CT and serial MR scans were obtained.

This article appears in the January/February 1989 issue of *AJNR* and the March 1989 issue of *AJR*.

Received December 28, 1987; accepted after revision May 3, 1988.

Presented at the annual meeting of the American Society of Neuroradiology, New York City, May 1987.

¹ Department of Radiology, Division of Neuroradiology, The New York Hospital–Cornell Medical Center, 525 E. 68th St., New York, NY 10021. Address reprint requests to K. Weingarten.

² Present address: Department of Radiology, Temple Medical Center, 40–60 Temple St., New Haven, CT 06510.

AJNR 10:81–87, January/February 1989

0195–6108/89/1001–0081

© American Society of Neuroradiology

CT examinations were performed on a GE 8800 scanner, with the exception of one patient who was studied initially with a Technicare 2020 scanner. Routine CT scans included contiguous 10-mm-thick sections of the brain from base to vertex.

MR images were acquired with a 0.5- or 0.6-T superconducting imager.* Spin-echo images were obtained in at least two imaging

* Teslacon, Technicare, Solon, OH.

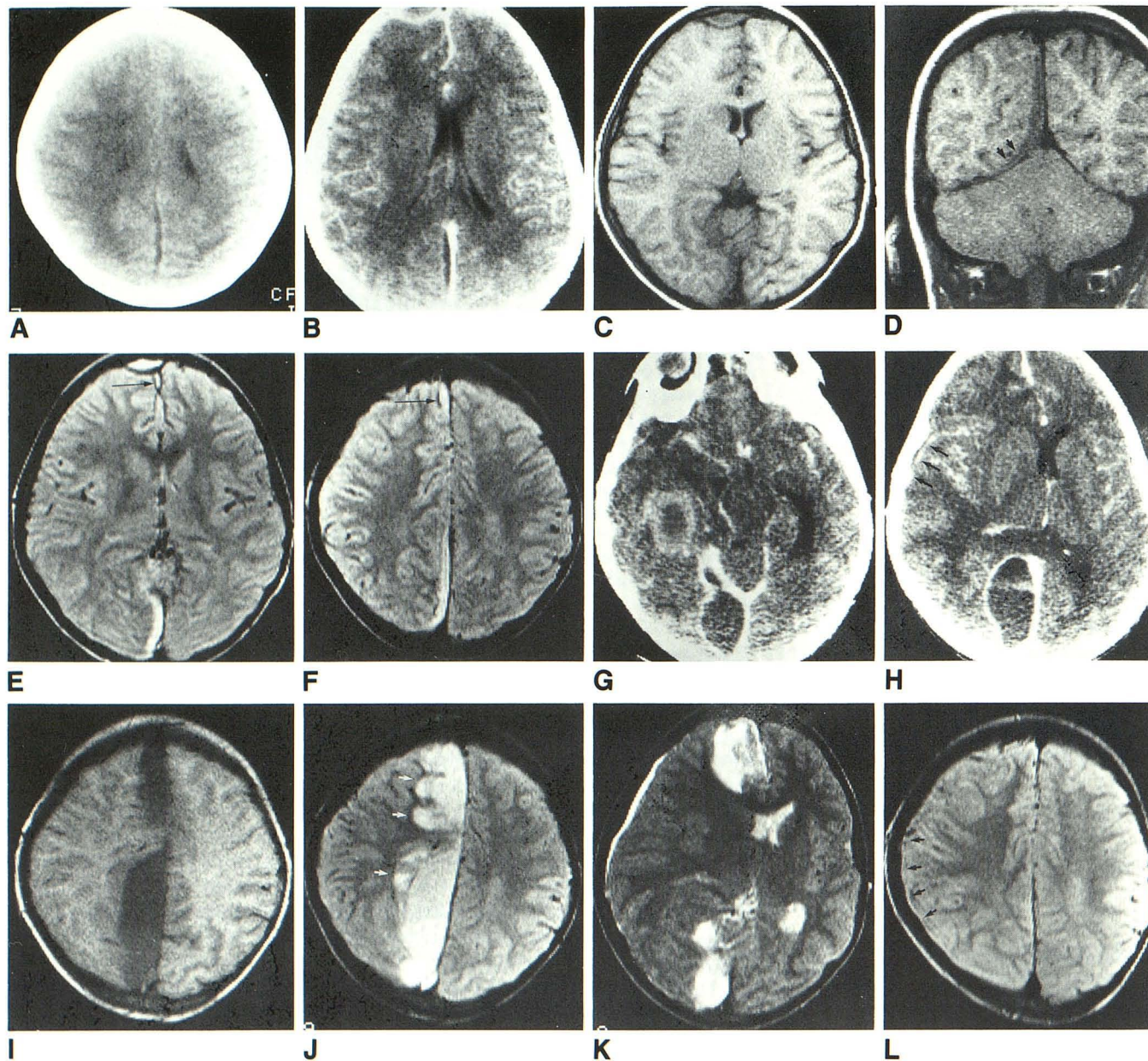


Fig. 1.—Case 1: 9-year-old boy with postsinusitis subdural and epidural empyemas.

A, Nonenhanced CT scan (originally interpreted as normal) shows interhemispheric extraaxial collection.

B, Contrast-enhanced CT scan 12 hr later shows extraaxial collections in posterior interhemispheric fissure and anterior to right frontal lobe. Note thickening of falx and marginal enhancement of right frontal collection.

C–F, MR images the same day. Axial and coronal 500/30 (C and D) and axial 2150/60 (E and F) scans show collections seen on CT and, in addition, extension of posterior interhemispheric collection into subtemporal subdural space (*short arrows*). Note superior delineation of anterior interhemispheric collection (*long arrows*), hyperintensity of collections relative to CSF, and presence of hypointense rim between right frontal collection and underlying cortex.

G and H, Contrast-enhanced CT scans 2 weeks after craniotomy. Loculated interhemispheric and subtemporal subdural empyemas and underlying parenchymal abnormalities are present. Note similarity between subtemporal empyema and parenchymal abscess; subtle, hypodense right convexity collection is appreciated retrospectively on CT (*arrows*).

I–K, MR images the same day. Axial 500/30 (I), 2150/60 (J), and 2150/120 (K) images show collections seen on CT. In particular, note excellent visualization of right convexity collection, cortical hyperintensity in right parasagittal gray matter on TR = 2150 sequence (*arrows*), and absence of hypointense rim surrounding all subdural loculations.

L, Follow-up axial MR image, 2150/60, 3 weeks later shows small residual convexity collection (*arrows*) and resolution of parenchymal abnormalities.

planes in all patients. The routine short TR/short TE pulse sequence was 500–750/30 (TR range/TE). Long TR, multiecho pulse sequences, 2150/30–120 (TR/TE range), were done in five patients, and a long TR, single-echo sequence, 1500/90, was performed in one patient. The slice thickness was 7.5 mm and the interslice gap was 2.5 mm.

The extraaxial empyemas were analyzed with specific attention to the ability of MR, as compared with CT, to (1) detect the lesions and define their extraaxial location and extent, (2) distinguish extraaxial empyemas from sterile effusions and chronic hematomas, (3) distinguish subdural from epidural empyemas, and (4) detect parenchymal changes.

Representative Case Reports

Case 1

A 9-year-old boy had 2 days of fever, lethargy, and dull headache, which progressed to left hemiparesis, drowsiness, severe headache, and meningism. A nonenhanced CT study at another institution was interpreted as normal (Fig. 1A). However, on review, a hypodense interhemispheric subdural collection and sinusitis were seen. Contrast-enhanced CT and MR, performed on admission 12 hr later, demonstrated sinusitis, an interhemispheric subdural empyema, and a right frontal epidural empyema (Figs. 1B–1F). The underlying brain parenchyma was normal. The patient underwent a limited surgical procedure, consisting of an anterior right frontal craniotomy with evacuation of 50 ml of purulent material from the epidural and anterior portion of the subdural collections. Cultures grew *Hemophilus influenzae* and anaerobic *Streptococcus*. The patient worsened after surgery; a right posterior frontal craniotomy 2 days later revealed

cheesy purulence and meningovascularitis of the underlying brain. The patient improved initially, but deteriorated 2 weeks after the second craniotomy. Contrast-enhanced CT delineated large loculated subdural empyemas and right hemispheric cortical enhancement (Figs. 1G and 1H). MR the same day demonstrated enlargement of the interhemispheric collection (Figs. 1I and 1J), a right frontal convexity collection, retrospectively seen on CT (Fig. 1K), and hyperintensity on the long TR pulse sequences in the right parasagittal cortex, an area in which no parenchymal abnormalities were identified on CT. The patient underwent extensive right frontal and right subtemporal craniotomies with evacuation of large amounts of pus. Postoperative nonenhanced CT demonstrated no subdural collections or parenchymal abnormalities; MR demonstrated a small residual convexity collection and resolution of mass effect and cortical abnormalities (Fig. 1L). The patient was treated with IV antibiotics and recovered uneventfully.

Case 2

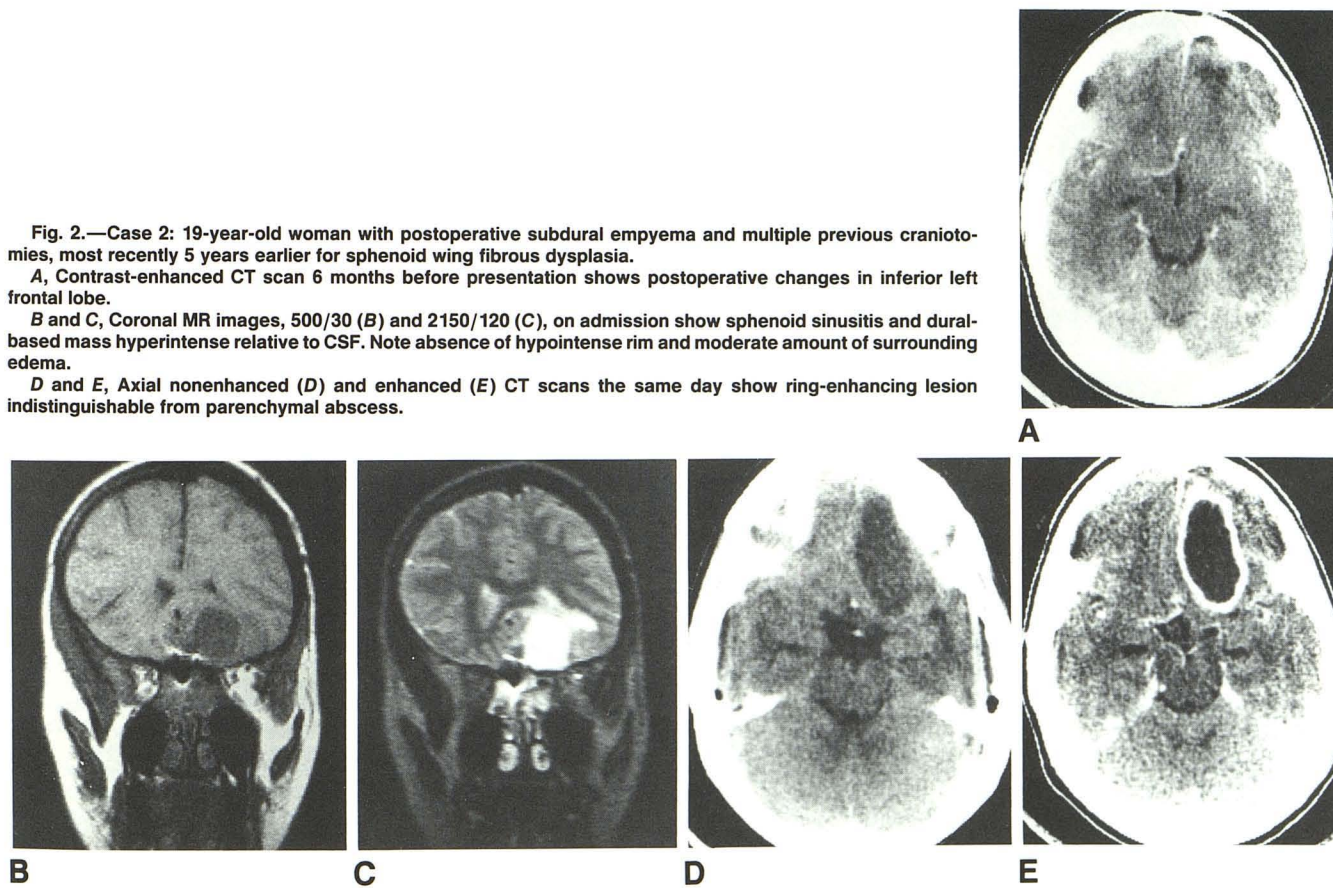
A 19-year-old woman, who had had several craniotomies 5 years earlier for sphenoid wing fibrous dysplasia, was seen with otitis media and meningitis. MR and contrast-enhanced CT demonstrated a dural-based mass contiguous with an eroded roof of the sphenoid sinus (Figs. 2B–2E). The ring-enhancing nature of the lesion on CT mimicked the appearance of a parenchymal abscess. On MR, the intensity of the lesion was typical of that seen in inflammatory fluid collections. A hypointense rim was absent. Craniotomy revealed a purulent subdural collection embedded in the inferior right frontal lobe with adjacent sphenoid sinusitis. Cultures grew *Hemophilus influenzae*. Follow-up MR demonstrated complete resolution of the lesion with minimal residual gliosis.

Fig. 2.—Case 2: 19-year-old woman with postoperative subdural empyema and multiple previous craniotomies, most recently 5 years earlier for sphenoid wing fibrous dysplasia.

A, Contrast-enhanced CT scan 6 months before presentation shows postoperative changes in inferior left frontal lobe.

B and C, Coronal MR images, 500/30 (B) and 2150/120 (C), on admission show sphenoid sinusitis and dural-based mass hyperintense relative to CSF. Note absence of hypointense rim and moderate amount of surrounding edema.

D and E, Axial nonenhanced (D) and enhanced (E) CT scans the same day show ring-enhancing lesion indistinguishable from parenchymal abscess.



Results

A total of nine extraaxial empyemas were reviewed in six patients; five were subdural and four epidural. The cause of the empyema was determined in all cases: two were from otorhinologic infection, two were from infection of a preexisting posttraumatic extraaxial hematoma, and two were from infection of a postcraniotomy cavity.

Within 24 hr of presentation, at least one hypodense (density equal to or slightly greater than that of CSF) collection was prospectively identified by CT in five of the six patients; in one patient, the lesion, though identified, appeared isodense relative to brain, masking its fluid nature (Fig. 3A). The extraaxial location and complete extent of the collections were correctly appreciated in one patient (Fig. 4A). The diagnostic efficacy of MR was equal to that of CT in this case (Figs. 4B–4D), and was superior to CT in the other five, with respect to sensitivity for detecting the presence and complete extent of all the collections (Figs. 1C–1F, 5C and 5D) and specificity for determining their nonsolid nature (Figs. 3B and 3C) and extracerebral location (Figs. 2B and 2C).

On CT, it was not usually possible to unequivocally differentiate an extraaxial empyema from a noninflammatory extraaxial lesion, including a sterile effusion, chronic hematoma, or recurrent tumor (Figs. 1A, 3A, 4A, and 5A), though disproportionate medial rim enhancement was suggestive of an underlying infectious origin (Figs. 1B, 3A, and 4E). On MR, otorhinologically induced and postoperative inflammatory collections demonstrated mild hyperintensity relative to CSF on short TR/short TE, 500/30, pulse sequences and more marked hyperintensity relative to CSF on long TR/intermediate TE sequences, 2150/60 (Figs. 1C–1F, 2B, 3B, 3C, and 5C). On the long TR/long TE sequences, the collections were isointense relative to CSF (Figs. 2C and 5D). The two patients with posttraumatic empyemas had hypointense collections with respect to most chronic hematomas on both short and long TR pulse sequences (Figs. 4B–4D).

On the basis of location (interposed between the superior sagittal sinus and falx posteriorly and the calvaria anteriorly) and, to a lesser degree, configuration (lenticiform), a collection in the epidural as opposed to the subdural space was prospectively identified on CT in one of the four patients with a lesion in this compartment (Fig. 1B). In the other three pa-

tients, an extraaxial lesion was accurately compartmentalized in one, though not correctly characterized as a nonsolid collection (Fig. 3A), and was not identified in two (Figs. 5A and 5B). In all four patients, MR was able to unequivocally differentiate an epidural from a subdural empyema on the basis of the presence of a hypointense rim separating the lesion from brain in the former cases (Figs. 1C, 1E, 3B, 3C, and 5D). This finding was absent in all cases of subdural empyemas, even in those patients in whom CT demonstrated dramatic enhancement of an inflammatory membrane (Figs. 1C–1F, 1I–1L, 2B, 2C, 4B–4D, 5C, and 5D).

Parenchymal changes were demonstrated during the course of illness in all patients on both CT and MR, and there were no patients in whom CT depicted these changes earlier or to a greater degree than did MR. Sulcal effacement and ventricular compression, the most common findings, were seen with nearly equal clarity (Figs. 1H, 1K, 3A, 3B, 4A, and 4B). MR was more sensitive than CT in detecting cortical involvement subjacent to an empyema. In particular, foci of cortical hyperintensity on the long TR pulse sequences were seen in two patients in regions in which CT did not demonstrate abnormal cortical enhancement or cortical edema (Figs. 1H, 1J, 1K, and 4C–4E). Of interest was the reversible nature of these hyperintensities, with complete or nearly complete resolution on follow-up MR (Figs. 1L and 4F).

Discussion

Subdural and epidural empyemas are uncommon infections. In children and adults, they occur in three circumstances, each with distinctive clinical and radiographic findings: (1) after sinusitis/mastoiditis, (2) as a postoperative infection of a craniotomy cavity, and (3) as a posttraumatic infection of an extraaxial hematoma. In infants, infection of a meningitis-induced sterile effusion is the most common cause of a subdural empyema [14, 16].

Most commonly, intracranial empyema occurs concomitant with or following an otorhinologic infection [3–6]. Empyemas in this setting are among the most urgent of neurosurgical emergencies, requiring a high clinical index of suspicion, prompt diagnosis, and early and aggressive surgical intervention [4, 9, 17]. Bacterial organisms gain access to the subdural

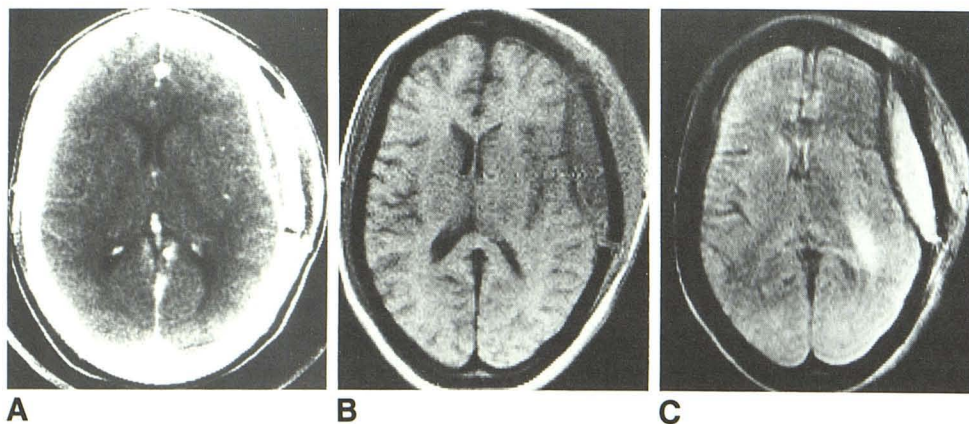


Fig. 3.—24-year-old woman with postoperative epidural empyema (craniotomy 1 year before for epidural metastatic disease).

A, Contrast-enhanced CT scan shows extraaxial mass underlying left frontotemporal craniotomy defect indistinguishable from tumor recurrence. Thick-walled medial rim enhancement suggests inflammatory cause.

B and C, Axial MR images, 500/30 (B) and 2150/60 (C), the same day show extraaxial fluid collection, which is hyperintense relative to CSF and has hypointense medial rim.

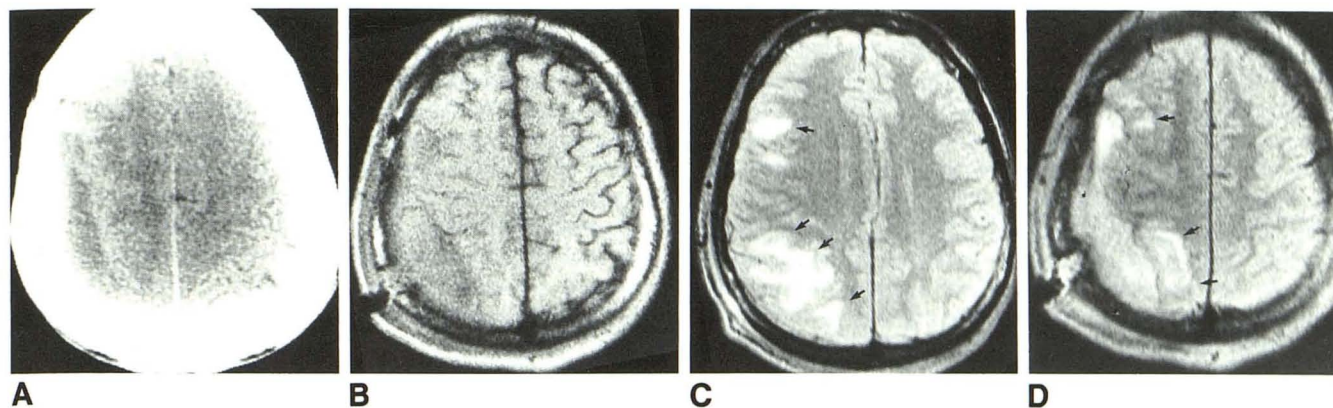


Fig. 4.—34-year-old man with subdural empyema secondary to infection of posttraumatic subdural hematoma.

A, Nonenhanced CT scan 2 weeks after injury shows right frontoparietal extraaxial fluid collection indistinguishable from subacute subdural hematoma.

B–D, Axial MR images, 500/30 (B) and 2150/60 (C and D), the same day show subdural empyema. Collection is hyperintense relative to CSF but hypointense relative to typical chronic hematoma; there is underlying cortical hyperintensity (arrows) and absence of hypointense medial rim.

E, Contrast-enhanced CT scan 2 weeks later shows irregular marginal enhancement suggestive of inflammatory nature of collection. Note lack of abnormal cortical enhancement.

F, Follow-up axial MR image, 2150/60, shows small residual collection and nearly complete resolution of parenchymal abnormalities.

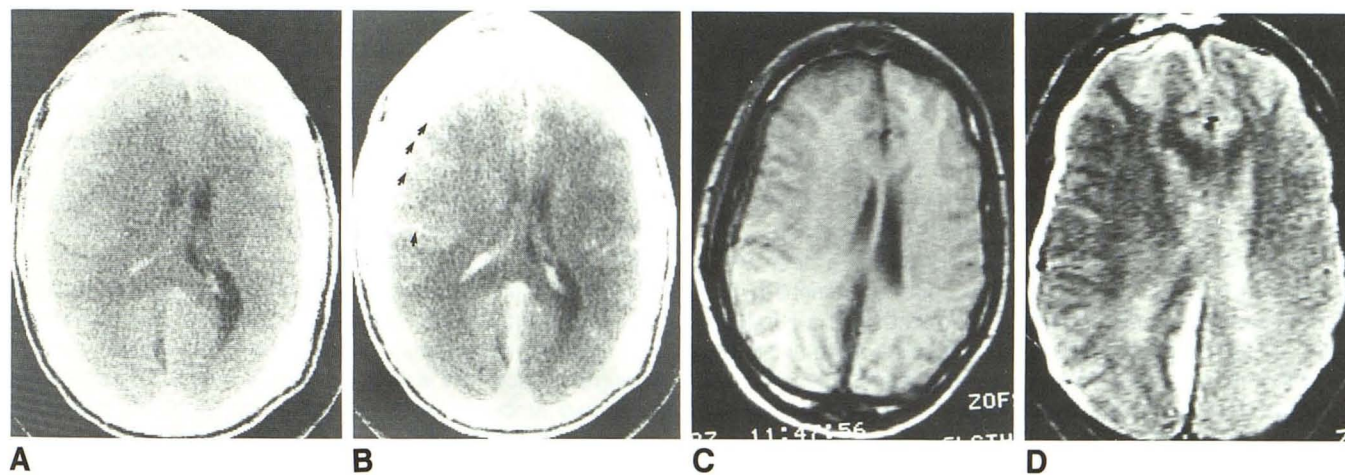
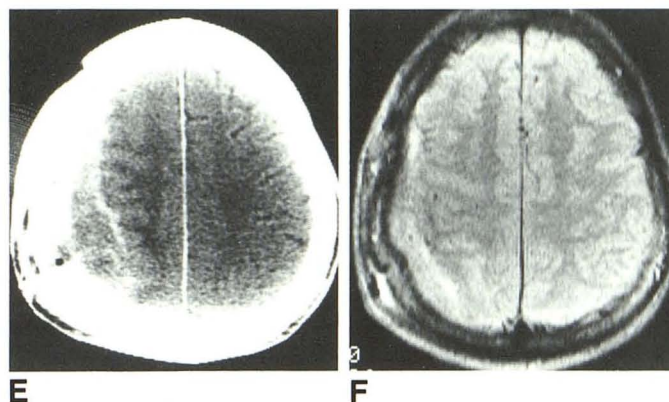


Fig. 5.—24-year-old man with otorhinologically induced subdural and epidural empyemas.

A and B, Nonenhanced (A) and enhanced (B) CT scans show right frontal sinusitis and poorly defined collection in interhemispheric fissure. Right hemispheric edema, mass effect, and right cortical (arrows) and falcine enhancement are present.

C and D, Axial 600/30 (C) and 2150/110 (D) MR images the same day show frontal sinusitis and right frontal, right convexity, and interhemispheric collections with intensity pattern typical of empyemas. Right frontal and convexity empyemas are visible only on MR. Note hypointense rim in former lesion and its absence in the latter, localizing these collections to epidural and subdural spaces, respectively.

space from paranasal sinus and otitic infections by way of retrograde thrombophlebitis of the bridging emissary veins [3, 5, 13]. Though the arachnoid acts initially as a barrier to the deeper spread of infection, unrestricted access in the supratentorial subdural space allows a thin layer of purulent material to be deposited diffusely over the cerebral convexity and/or in the parafalcine and paratentorial regions. An epidural empyema may occur in association with osteomyelitis of the

posterior paranasal sinus wall. However, an epidural empyema rarely occurs as an isolated event without the simultaneous presence or subsequent development of a subdural empyema (Figs. 1 and 5) [3, 13]. Progression of thrombophlebitis to involve the cortical veins and major dural sinuses ensues, with edema and ischemia of the subjacent cortex. Without prompt and aggressive therapy, irreversible dural sinus and venous thrombosis and secondary parenchymal

infection and infarction occur. In these patients, the clinical and radiologic findings, and the high morbidity and mortality (25–40%), are related more to the response of the cerebral vasculature and brain to the inflammatory process and less to the mass effect of the extraaxial collection [10, 13, 18]. A fulminant clinical course is the rule, with fever, lethargy, meningism, and headache followed by the rapid development of seizures, hemiparesis, and coma. Surgical treatment is an absolute requirement, since systemically administered antibiotics do not penetrate the subdural space in therapeutic amounts [3, 4, 9]. In addition, early and aggressive evacuation is an important factor in preventing or limiting the degree of cortical damage and subsequent neurologic deficits.

Postoperative and posttraumatic empyemas are a separate subdivision of extraaxial suppuration. In marked contrast to otorhinologically induced empyemas, postoperative and post-traumatic empyemas occur months to years after the original insult with relatively benign presenting symptoms and minimal or no systemic signs of infection [7, 8]. The indolent symptomatology is due to the presence of a well-formed limiting membrane from prior surgery or trauma, restricting the spread of the inflammatory collection in the extracerebral space, limiting the access to surface veins and dural sinuses, and shielding the underlying parenchyma from irreversible damage. Clinical findings are mainly due to the mass effect of the extraaxial collection.

Though demonstrating similar radiologic features, the three clinical circumstances in which extracerebral empyemas occur present different diagnostic challenges, for which both CT and MR play a role. For empyemas caused by otorhinologic infection, the aim is to identify and localize the collection as early as possible in the course of disease. For empyemas secondary to infection of a preexisting subdural or epidural hematoma, the aim is to distinguish them from extraaxial hematomas. For empyemas caused by infection of a post-craniotomy cavity, the aim is to differentiate them from sterile effusions, tumor recurrence, and parenchymal abscess.

The CT findings of extraaxial empyemas have been well described [2, 5, 13, 14]. Early in the course of disease, CT findings can be subtle and easily overlooked. MR is superior to CT in evaluating these lesions, by enabling more sensitive detection, more accurate localization (compare Figs. 2C and 2E), and more complete delineation of disease. Frequently, loculations of pus are imaged on MR that cannot be appreciated on CT (compare Fig. 5B and Fig. 5D). Superficial lesions are more conspicuous on MR than CT due to the absence of bone artifact, multiplanar imaging capability, and excellent contrast between brain and CSF (compare Figs. 1H and 1K).

On the basis of signal intensity differences, MR can differentiate extraaxial empyemas from most sterile effusions and most chronic (weeks to months old) hematomas (compare Figs. 4A and 4D). As with other proteinaceous fluids, T1 and T2 values of empyemas are shorter than those of CSF and longer than those of gray and white matter, reflected by mild hyperintensity relative to CSF and hypointensity relative to brain on short TR/short TE images and more marked hyperintensity relative to CSF and brain on long TR/long TE images, allowing distinction from sterile effusions [19]. The posttrau-

matic empyemas are hypointense on both the short and long TR sequences as compared with most chronic hematomas. Differentiating these entities can be difficult on CT, because hemorrhage, effusions, and empyemas may appear as hypodense collections. Medial, rimlike enhancement of a fluid collection on contrast-enhanced CT indicates the presence of a granulation tissue membrane or of inflammatory changes in the underlying cortex. However, lack of enhancement does not exclude an acute empyema, and occasionally, marked contrast enhancement can be seen in a chronic subdural hematoma that has undergone several episodes of rehemorrhage [13].

Our study demonstrates greater specificity of MR as compared with CT in differentiating a subdural from an epidural empyema (compare Fig. 3A with Fig. 3C) and from a parenchymal abscess. A hypointense medial rim, representing inflamed dura, is seen in an epidural but not a subdural empyema. Though the presence of osteomyelitis or a subgaleal abscess in association with an extracerebral collection favors the CT diagnosis of epidural empyema over subdural empyema, in its absence, these two lesions can appear similar. With respect to subdural empyema and parenchymal abscess, a characteristic and differential diagnostic feature that has been noted in the latter lesion is the presence of a moderately to markedly hypointense peripheral ring on long TR sequences. This signal characteristic represents preferential T2 proton relaxation enhancement, probably attributable to heterogeneously distributed paramagnetic free radicals produced in macrophages during active phagocytosis at the abscess rim [20].

Parenchymal abnormalities are more readily diagnosed on MR than on CT. Sulcal effacement, which can be a subtle finding on CT, is readily appreciated on MR due to excellent visualization of cortical sulci. Reversible cortical hyperintensities on the long TR pulse sequences were noted in two patients with subdural empyemas, presumably representing cortical hyperemia or edema due to ischemia induced by inflammatory vasospasm (Figs. 1J, 1L, 4C, 4D, and 4F). Moreover, the depiction of parenchymal changes in association with posttraumatic empyemas facilitates distinction from noninfected hematomas, which do not cause cortical changes. Since MR is more sensitive than CT in detecting abnormal amounts of tissue water on long TR pulse sequences, it is not surprising that these parenchymal changes are demonstrated more clearly on MR than on CT. It is of interest that cortical and/or venous thrombosis, though sought, was not identified in any of our cases. On the basis of previous reports, MR is well suited for the evaluation of venous thrombosis, which, if present, should increase diagnostic specificity [21, 22].

Successful management of patients with extraaxial empyemas requires early diagnosis combined with prompt and complete evacuation of every loculation of pus. The high morbidity and mortality associated with these virulent yet potentially curable infections are in part due to failure to recognize these entities on CT, especially small pockets of pus; lack of widespread appreciation of the importance of aggressive treatment at the earliest possible stage; and iatro-

genic transformation of acute extraaxial empyemas into chronic extraaxial abscesses due to incomplete surgical drainage. Improvement in prognosis can be expected with the use of MR, due to its sensitivity and specificity for early and accurate diagnosis and its ability to monitor the response to therapy.

REFERENCES

1. Danziger A, Price H, Schechter MM. An analysis of 113 intracranial infections. *Neuroradiology* 1980;19:31-34
2. Blaquiére RM. The computed tomographic appearances of intra- and extracerebral abscesses. *Br J Radiol* 1983;56:171-181
3. Kaufman DM, Miller MH, Steigbigel NH. Subdural empyema: analysis of 17 recent cases and review of the literature. *Medicine* (Baltimore) 1975;54(6):485-498
4. Joubert MJ, Stephanov S. Computerized tomography and surgical treatment of intracranial suppuration. *J Neurosurg* 1977;47:73-78
5. Sharif HS, Ibrahim A. Intracranial epidural abscess. *Br J Radiol* 1982;55:81-84
6. Kaufman DM, Litman N, Miller MH. Sinusitis: induced subdural empyema. *Neurology* 1983;33:123-132
7. Luken MG, Whelan MA. Recent diagnostic experience with subdural empyema. *J Neurosurg* 1980;52:764-771
8. Post EM, Modesti LM. "Subacute" postoperative subdural empyema. *J Neurosurg* 1981;55:761-765
9. Bannister G, Williams B, Smith S. Treatment of subdural empyema. *J Neurosurg* 1981;55:82-88
10. Sadhu VK, Handel SF, Pinto RS, Glass TF. Neuroradiologic diagnosis of subdural empyema and CT limitations. *AJNR* 1980;1:39-44
11. Dunker RO, Khakoo RA. Failure of computed tomographic scanning to demonstrate subdural empyema. *JAMA* 1981;246:1116-1118
12. Stephanov S, Joubert MJ, Welchman JM. Combined convexity and parasagittal subdural empyema. *Surg Neurol* 1979;11:147-151
13. Zimmerman RD, Leeds NE, Danziger A. Subdural empyema: CT findings. *Radiology* 1984;150:417-422
14. Enzmann DR. Extracerebral infection. In: Enzmann DR, ed. *Imaging of infections and inflammations of the central nervous system: computed tomography, ultrasound, and nuclear magnetic resonance*. New York: Raven, 1984:234-249
15. Weisberg L. Subdural empyema—clinical and computed tomographic correlations. *Arch Neurol* 1986;43:497-500
16. Jacobson PL, Farmer TW. Subdural empyema complicating meningitis in infants: improved prognosis. *Neurology* 1981;31:190-193
17. Borzone M, Capuzzo T, Rivano C, Tortori-Donati P. Subdural empyema: fourteen cases surgically treated. *Surg Neurol* 1980;13:449-452
18. Smith HP, Hendrick EB. Subdural empyema and epidural abscess in children. *J Neurosurg* 1983;58:392-397
19. Kjos BO, Brant-Zawadzki M, Kucharczyk W, Kelly WM, Norman D, Newton TH. Cystic intracranial lesions: magnetic resonance imaging. *Radiology* 1985;155:363-369
20. Sze G, Zimmerman RD. The magnetic resonance imaging of infections and inflammatory diseases. *Radiol Clin North Am* 1988;26:839-860
21. Macchi PJ, Grossman RI, Gomori JM, Goldberg HI, Zimmerman RA, Bilaniuk LT. High field MR imaging of cerebral venous thrombosis. *J Comput Assist Tomogr* 1986;10:10-15
22. McMurdo SK, Brant-Zawadzki M, Bradley WG, Chang GY, Berg BO. Dural sinus thrombosis: study using intermediate field strength MR imaging. *Radiology* 1986;161:83-86