



Discover Generics

Cost-Effective CT & MRI Contrast Agents

 FRESENIUS
KABI

[WATCH VIDEO](#)

AJNR

Intrasellar trigeminal artery.

D N Richardson, A D Elster and M R Ball

AJNR Am J Neuroradiol 1989, 10 (1) 205

<http://www.ajnr.org/content/10/1/205.citation>

This information is current as
of June 15, 2025.

Intrasellar Trigeminal Artery

A case of pituitary macroadenoma is presented in which correct preoperative CT recognition of a persistent trigeminal artery piercing the dorsum sella prompted angiographic evaluation. MR was then used to further examine the intrasellar course of the anomalous vessel. A search of the English literature failed to disclose previous CT or MR demonstration of a persistent trigeminal artery.

Case Report

A 19-year-old man with clinical and biochemical evidence of Cushing syndrome was referred to the neurosurgery department at our institution. An infused CT scan with 1.5-mm axial and coronal images through the sella performed before surgery showed a low-attenuation intrasellar adenoma situated centrally and to the right. A high-density tubular structure branched from the basilar artery, continued parallel to the dorsum sella for a short distance, and then pierced the left side of the dorsum. The structure could not then be separated from the cavernous sinus on the left side. Coronal sections of the dorsum sella with bone windowing showed a rounded, well-margined defect. The neurosurgeons were alerted to the probable presence of an anomalous vessel, and preoperative angiography showed a persistent trigeminal artery. (Fig. 1A).

MR images were obtained in three orthogonal planes. The pituitary adenoma was inhomogeneous and isointense with brain on T1-weighted images and was hyperintense on T2-weighted images. As was the case with CT, axial images showed the persistent trigeminal artery piercing the dorsum sella to the left of midline but medial to the posterior clinoid process and oculomotor nerve. The flow void of the artery had a short intrasellar course before joining the intracavernous carotid artery on its medial surface (Figs. 1B–1D). Although the medial dural wall of the left cavernous sinus was not clearly apparent on any of the MR images, the intrasellar portion of the persistent trigeminal artery was visualized directly and avoided during successful transphenoidal surgery.

Discussion

The persistent trigeminal artery is the most common of the persistent fetal carotid-basilar anastomoses; the prevalence is 0.1–0.2%

[1]. It arises from the immediate precavernous or intracavernous internal carotid artery proximal to the meningohypophyseal trunk and usually joins the distal third of the basilar artery between the superior cerebellar artery and the anterior inferior cerebellar artery. Anatomic dissections have shown variation in the course of the persistent trigeminal artery [2–6]. The usual intracavernous course is from the posterolateral wall of the carotid artery to the posterior dural surface of the cavernous sinus, where the persistent trigeminal artery exits just medial to the sensory root of the trigeminal nerve. As it exits, it may groove or pierce the dorsum sella. One specimen showed an origin from the medial surface of the internal carotid artery and an intrasellar course in close relation to the pituitary gland [2]. This persistent trigeminal artery sharply ascended from the floor of the sella to pierce the dorsum. We believe that our images are virtually identical to this dissected specimen.

Because of its strategic position, the persistent trigeminal artery may pose a hazard to a surgeon who is operating in the sellar and parasellar regions. We have shown that CT and MR may be the first clue to the presence of such a vessel.

Dan N. Richardson

Allen D. Elster

Marshall R. Ball

Bowman Gray School of Medicine

Winston-Salem, NC 27103

REFERENCES

1. Lie TA. *Congenital anomalies of the carotid arteries*. Amsterdam: Excerpta Medica Foundation, 1968;52–70
2. Tulsi RS, Lockett NA. Persistent trigeminal artery: an anatomical study. *Aust NZ J Surg* 1985;55:397–402
3. Schmid AH. Persistent trigeminal artery: an autopsy report. *Neuroradiology* 1974;7:173–175
4. Sunderland S. Neurovascular relations and anomalies at the base of the brain. *J Neurol Neurosurg Psychiatry* 1948;11:243–257
5. Harrison CR, Luttrell C. Persistent carotid-basilar anastomosis. *J Neurosurg* 1953;10:205–215
6. Parkinson D, Shields CB. Persistent trigeminal artery: its relationship to the normal branches of the cavernous carotid. *J Neurosurg* 1974;40:244–248

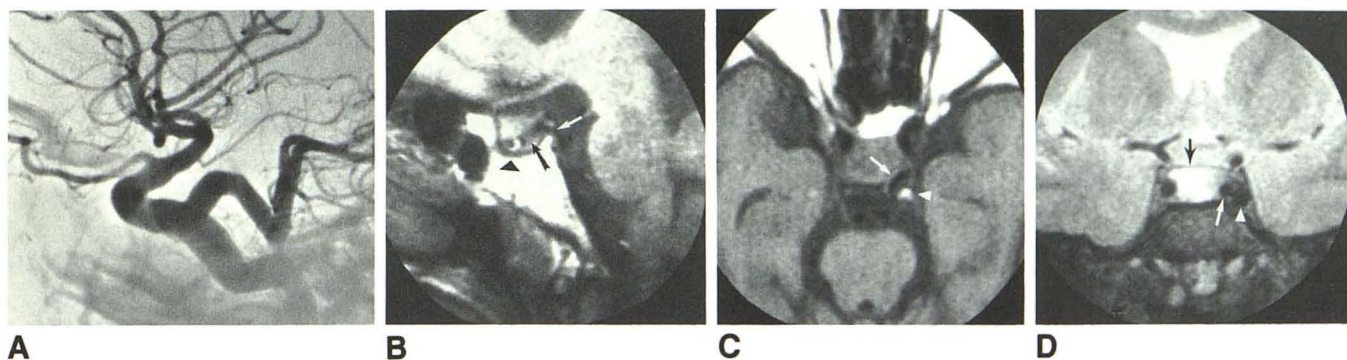


Fig. 1.—Intrasellar trigeminal artery.

A, Left internal carotid angiogram shows persistent trigeminal artery joining intracavernous internal carotid to distal basilar artery. Trigeminal artery ascends from floor of sella to pierce dorsum and then descends to join basilar artery.

B, T1-weighted (SE 500/20) parasagittal MR image shows intrasellar flow void of persistent trigeminal artery (black arrow) in relation to cortical margin of sella (arrowhead) and defect in dorsum (white arrow).

C, T1-weighted (SE 500/20) axial MR image shows that flow void of trigeminal artery (arrow) coursing medial to marrow-containing posterior clinoid process (arrowhead) lies in posterior inferior corner of sella.

D, T2-weighted (SE 2000/80) coronal MR image shows intrasellar persistent trigeminal artery (white arrow) and its relationship to high-signal pituitary adenoma (black arrow) and left internal carotid artery (arrowhead).