



Discover Generics

Cost-Effective CT & MRI Contrast Agents



WATCH VIDEO

AJNR

Cerebral MR of Menkes kinky-hair disease.

E N Faerber, W D Grover, G J DeFilipp, M A Capitanio, T H Liu
and J D Swartz

AJNR Am J Neuroradiol 1989, 10 (1) 190-192
<http://www.ajnr.org/content/10/1/190.citation>

This information is current as
of June 18, 2025.

Cerebral MR of Menkes Kinky-Hair Disease

Eric N. Faerber,¹ Warren D. Grover,² Gary J. DeFilipp,^{3,4} Marie A. Capitanio,¹ Te-Hua Liu³ and Joel D. Swartz⁵

Menkes kinky-hair disease (trichopoliodystrophy, steely-hair disease) is an X-linked neurodegenerative disorder that occurs predominantly in males. It was first described by Menkes in 1962 [1]. The characteristic clinical features are steely hair, profound retardation, spastic quadriplegia, seizures, and hypothermia. The disease is caused by an underlying defect of copper metabolism; and the serum and hepatic copper levels are below normal [2, 3]. The radiologic features of this disorder include bone changes, tortuous cerebral vessels, cerebral atrophy, extracerebral fluid collections, and bladder diverticula [4–7]. Cerebral atrophy, extraaxial accumulation of fluid, and low-density cortical areas have been described in the limited number of children with this disorder who have had cerebral CT [8, 9].

We report on the cerebral MR imaging appearances in three patients with Menkes disease. MR was correlated with CT in each case.

Subjects and Methods

Three male children with Menkes disease ranging in age from 6 months to 13 years were studied by MR using a 0.3-T Fonar Beta 3000M permanent magnet. T1- and T2-weighted spin-echo (SE) sequences, 28,56/500,1999 (TRs/TEs), were used in all three patients. Inversion recovery (IR) sequences, 333/1545 (TI/TR), were also used in one patient (case 2). Images (512² matrix) were obtained in the axial plane initially, followed by coronal and/or sagittal planes. Patients fasted for 4 hr before the study, and they were sedated with oral chloral hydrate (80–100 mg/kg) 30 min before the study.

Case Reports

Case 1

J.D. is a 13-year-old boy in whom Menkes disease was diagnosed at 3 days of age. Physical examination at 8 hr of age revealed knots of friable kinky hair covering the scalp, a cephalhematoma, small mandible, talipes equinovarus, icterus, and thrombocytopenia. Skull radiographs demonstrated multiple wormian bones. The serum cop-

per level was 16 $\mu\text{g/dl}$, (normal, 90–110 $\mu\text{g/dl}$), serum ceruloplasmin 4 mg/dl (normal, 20–40 mg/dl), and hepatic copper concentration of 14 $\mu\text{g/gm}$ dry weight (normal, 226 ± 57). Low serum levels of dopamine- β -hydroxylase activity were documented by enzyme assay. Elevated levels of dopamine and decreased levels of norepinephrine were found both in blood and CSF. A scalp biopsy performed in the second week of life showed miniature hair follicles, pili torti, and monilethrix.

Although no seizures have been documented in this patient, a slowly progressive loss of motor, cognitive, and language abilities has been noted over a 12-year period.

Cerebral angiography performed in infancy revealed no abnormalities. A second angiogram at 5 years of age demonstrated typical arterial tortuosity. Cerebral CT, performed at the age of 9 years, demonstrated tortuosity of the middle cerebral arteries, dilated ventricles, and cortical atrophy.

At 12 years of age multiplanar cerebral MR scans were obtained. Vascular tortuosity (Fig. 1), increased ventricular size, and cortical atrophy were well demonstrated.

Case 2

D. McF. was admitted to our hospital at the age of 6 months for the evaluation of steely hair, seizures, and developmental delay. The serum copper level was 19 $\mu\text{g/dl}$. Serum catecholamine values were consistent with defective activity of dopamine- β -hydroxylase. CT scans revealed evidence of cerebral atrophy and a large left extracerebral fluid collection.

An MR scan at the age of 15 months demonstrated the large extracerebral fluid collection and underlying cortical atrophy (Fig. 2). The subdural hygroma was subsequently drained by a ventriculoperitoneal shunt. Tortuosity of cerebral vessels was demonstrated.

Case 3

F.S., a 21-month-old boy, was admitted to our hospital at the age of 9 months for evaluation of Menkes disease. The initial physical examination revealed steely scalp hair, infantile spasms, mild spastic quadriplegia, and a functioning level of 3 months. The serum copper level was 17 $\mu\text{g/dl}$, and serum ceruloplasmin was 9 mg/dl, confirming the diagnosis.

Received April 24, 1987; accepted after revision August 13, 1987.

¹ Department of Radiology, St. Christopher's Hospital for Children, Temple University Hospital, Medical College of Pennsylvania Hospital, and Hahnemann University Hospital, Philadelphia, PA. Address reprint requests to E. N. Faerber, Department of Radiology, St. Christopher's Hospital for Children, 2600 N. Lawrence St., Philadelphia, PA 19133.

² Department of Neurology, St. Christopher's Hospital for Children, Philadelphia, PA 19133.

³ Department of Radiology, Temple University Hospital, Philadelphia, PA 19133.

⁴ Present address: Division of Neuroradiology, University of Michigan Hospitals, Ann Arbor, MI 48105.

⁵ Department of Radiology, Medical College of Pennsylvania Hospital, Philadelphia, PA 19129.

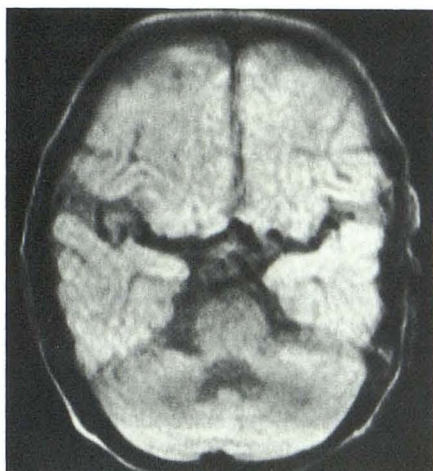


Fig. 1.—Spin-echo axial MR image (TE = 56/TR = 1999) of 12-year-old boy shows tortuosity of both middle cerebral arteries.

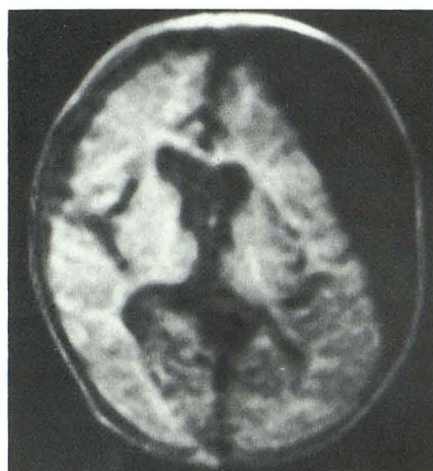

Fig. 2.—Inversion-recovery MR image (TI = 333/TR = 1545) of 15-month-old boy shows compression of left frontal horn and contralateral ventricular shift by the subdural collection.

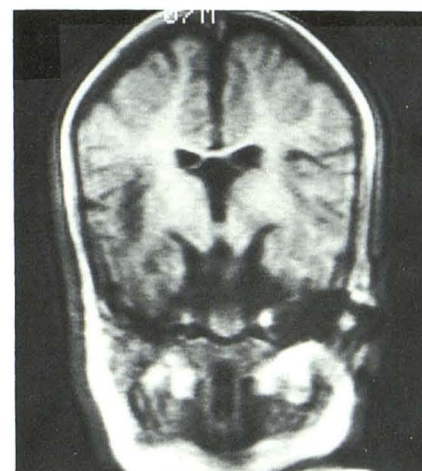

Fig. 3.—Spin-echo coronal MR image (TE = 28/TR = 500) of 15-month-old boy shows cortical atrophy and increased ventricular size.

A CT scan at 6 months of age revealed evidence of cortical atrophy. An MR scan at 15 months of age, which employed similar pulse sequences to those used for the previous two patients, revealed evidence of cortical atrophy and increased ventricular size (Fig. 3). Tortuosity of cerebral vessels was not noted.

Discussion

Menkes disease is associated with an underlying abnormality of copper metabolism. Biochemical features of the disease include low serum, hepatic, and brain-copper levels. Defective intracellular binding and membrane transport of copper have been related to an abnormal metallothionein (a copper-binding protein). Decreased absorption of copper from the gastrointestinal tract and the variations in copper concentrations from normal levels are noted in all organs [10]. There is decreased activity of copper-dependent enzymes, cytochrome oxidase A1 and A3 in liver, brain [11], and white cells [12]. Deficiency of dopamine- β -hydroxylase, with abnormal catecholamine levels in the blood and CSF, has been described [13]. The disease is typically recognized between 2 and 3 months of age, although it has been detected as early as 3 days (case 1) [14, 15]. The scalp hair is sparse, coarse, stubby, and devoid of pigment [1]. The microscopic examination of the hair demonstrates twisting of the hair shaft (pili torti), periodic narrowing (monilethrix), and fragmentation (trichorrhexis nodosa). Microcephaly and growth failure are common. Other congenital abnormalities frequently associated with this disorder include pectus excavatum, high arched palate, undescended testes, hiatal or inguinal hernias, and club feet [14].

The intracranial abnormalities encountered in this disorder have been attributed to numerous pathogeneses. The large subdural fluid collections (Fig. 2) are considered to be a consequence of the marked cerebral atrophy and the abnormal vascular structures. As the atrophied brain recedes from the dura, the bridging cortical veins tear, resulting in subdural

effusions [8]. The extracerebral fluid collections, originally demonstrated by ventriculography [7], are now easily demonstrated by both CT and MR. Early in infancy, these children may have infractions of the metaphyses of the long bones. The infractions and subdural effusions may suggest an erroneous diagnosis of the battered child syndrome. The diagnosis of Menkes disease should be considered in infants with large bilateral subdural collections who fail to respond to both medical and surgical treatment [2, 8].

Pathologic examination of the brain reveals multifocal areas of infarction and edema [8]. Neuronal loss and gliosis have been demonstrated in the cortex, basal ganglia, and thalami. The neuronal loss especially affects cells in the neocortex and cerebellum, and may be accompanied by calcification and iron deposition [16, 17]. Secondary axonal degeneration and gliosis are most intense during the first postnatal year [17–19]. Two etiologies for CNS pathology include an abnormality of copper metabolism [19, 20] and ischemic encephalomalacia secondary to vascular abnormalities [19].

Excessive tortuosity of the cerebral arteries has been demonstrated on angiography [7]. Tortuosity of the abdominal arterial system has also been described [9]. The tortuosity of the intracerebral vasculature may be well demonstrated by both CT and MR, and the relative ease with which this feature is demonstrated on MR will obviate the need for cerebral angiography.

REFERENCES

1. Menkes JH, Alter M, Steigleder GK, Weakley DR, Sung JH. A sex-linked recessive disorder with retardation of growth, peculiar hair and focal cerebral and cerebellar degeneration. *Pediatrics* 1962;29:764–779
2. Danks DM, Campbell PE, Stevens BJ, Mayne V, Cartwright E. Menkes kinky hair syndrome: an inherited defect in copper absorption with wide-spread effects. *Pediatrics* 1972;50:188–201
3. Danks DM, Campbell PE, Walker Smith J, Stevens BG, Gillespie JM, Blomfield J. Menkes kinky hair syndrome. *Lancet* 1972;50:1000–1102
4. Wesenberg RL, Gwinn JL, Barnes GR Jr. Radiological findings in the kinky

- hair syndrome. *Radiology* **1969**;92:500-506
5. Adams PC, Strand RD, Bresnan MJ, Lucky AW. Kinky hair syndrome: serial study of radiological findings with emphasis on the similarity to the battered child syndrome. *Radiology* **1974**;112:401-407
 6. Harcke HT, Capitanio MA, Grover WD, Valdes-Dapena M. Bladder diverticuli and Menkes syndrome. *Radiology* **1977**;124:459-461
 7. Aguilar MJ, Chadwick DL, Okuyama K, Kamoshita S. Kinky hair disease. I. Clinical and pathological features. *J Neuropathol Exp Neurol* **1966**;25:507-522
 8. Seay AR, Bray PF, Wing SD, Thompson JA, Bale JF, Williams DM. CT scans in Menkes disease. *Neurology* **1979**;29:304-312
 9. Farrelly C, Stringer DA, Daneman A, Fitz CR, Sass-Kortsak A. CT manifestations of Menkes kinky hair syndrome (trichopoliodystrophy). *J Can Assoc Radiol* **1984**;35:406-408
 10. Danks DM, Cartwright E, Stevens BJ, Townley RRW. Menkes kinky hair disease: further definition of the defect in copper transport. *Science* **1973**;179:1140-1142
 11. French JH, Sherard ES, Lubell H, Brotzky M, Moore CL. Trichopoliodystrophy. Report of a case and biochemical studies. *Arch Neurol* **1972**;26:229-244
 12. Nooijen CT, DeGroot CJ, Van Den Hemer CJA, Monnens AH, Willemse J, Niermeijer MF. Trace element studies in three patients with Menkes disease. Effects of copper therapy. *Pediatr Res* **1981**;15:284-289
 13. Grover WD, Henkin RI, Schwartz M, Brodsky N, Hobbell E, Stolk JM. A defect in catecholamine metabolism in kinky hair disease. *Ann Neurol* **1982**;12:263-266
 14. Greenwood RS, Kahler SG, Aylsworth AS. Inherited metabolic disease. In: Farmer TW, ed. *Pediatric neurology*, 3rd ed. New York: Harper & Row, **1984**:375-377
 15. Grover WD, Scrutton MC. Copper infusion therapy in trichopoliodystrophy. *J Pediatr* **1975**;86:216-220
 16. Barnard RO, Best PV, Erdohazi M. Neuropathology of Menkes disease. *Dev Med Child Neurol* **1978**;20:586-597
 17. Williams RS, Marshall PC, Lott IT, Caviness VS. The cellular pathology of Menkes steely hair syndrome. *Neurology* **1978**;28:575-583
 18. Vagn-Hansen PL, Reske-Nielsen E, Lou HC. Menkes disease—a new leukodystrophy? A clinical and neuropathological review together with a new case. *Acta Neuropathol (Berl)* **1973**;25:103-119
 19. Vuia O, Heye D. Neuropathological aspects in Menkes kinky hair disease (trichopoliodystrophy). *Neuropediatric* **1974**;5:329-339
 20. Hirano A, Liena JF, French JH, Gha Tak NR. Fine structure of the cerebellar cortex in Menkes kinky hair disease. *Arch Neurol* **1977**;34:52-56