



Providing Choice & Value

Generic CT and MRI Contrast Agents



FRESENIUS
KABI

CONTACT REP

AJNR

**Spinal pachymeningeal carcinomatosis:
myelographic features.**

K S Kim, P E Weinberg and M Hemmati

AJNR Am J Neuroradiol 1980, 1 (2) 199-200

<http://www.ajnr.org/content/1/2/199.citation>

This information is current as
of July 18, 2025.

Spinal Pachymeningeal Carcinomatosis: Myelographic Features

KWANG S. KIM,¹ PETER E. WEINBERG, and
MASSOUD HEMMATI

Metastases to the spine resulting in spinal neuropathy occur commonly. The vast majority involve the vertebrae and the epidural spaces. Intradural metastases, either extra- or intra-medullary arising from a primary lesion outside of the central nervous system are seldom encountered. Another rare form of metastatic disease to the spinal central nervous system is leptomeningeal carcinomatosis. This type of metastasis is characterized by diffuse tumor infiltration of the pia-arachnoid of the spinal cord and of the nerve roots [1]. We recently observed a case with pachymeningeal carcinomatosis in the cervical region with diffuse sheetlike tumor infiltration of the dura. To our knowledge, this form of metastasis has not been previously reported.

Case Report

A 66-year-old man had a recent history of neck pain of increasing severity which radiated to the occipital area and into both shoulders. He also complained of limited neck motion and intermittent numbness in both hands. Significant medical history included a colectomy for adenocarcinoma 4 years earlier.

Physical examination revealed limitation of neck motion secondary to pain, mild weakness of the deltoids and intrinsic hand muscles, and hyperreflexia in the left lower extremity. Cerebrospinal fluid analysis including protein, glucose, and cell count was normal.

Plain films of the cervical spine demonstrated normal alignment of the vertebral bodies, intact disc spaces, and no evidence of significant degenerative changes or destructive lesion. Pantopaque myelography, performed under general anesthesia because of severe neck pain, demonstrated a uniform concentric narrowing of the subarachnoid space extending from C2 to C6. There was increased distance between the medial margins of the pedicles and the lateral aspects of the subarachnoid space at the same levels (fig. 1).

At surgery, a complete laminectomy was performed from C3 to C6. The dura was markedly thickened, taut, and whitish in appearance. The dura was opened, revealing a normal-appearing subarachnoid space. Microscopy showed tumor infiltration of the dura with adenocarcinoma (fig. 2). This was believed to represent metastasis from the known primary adenocarcinoma of the colon. The

patient died 2 weeks after surgery due to pulmonary complications. No autopsy was performed.

Discussion

Most metastatic deposits involving the central nervous system are nodular. Leptomeningeal carcinomatosis is a rare form of malignant invasion consisting of diffuse carcinomatous infiltration of the pia-arachnoid of the brain and spinal cord with extension into the arachnoid prolongation around the cranial and spinal nerve roots [1].

Our patient had a long segment of diffuse sheetlike infiltration of the cervical spine pachymeninges. The pia-arachnoid was free of tumor. This form of metastasis appears to be unique and has not been previously described.

The patient's predominant clinical symptom was progressive severe neck pain due to spinal nerve root compression. There was minimal, if any, myelopathy due to spinal cord compression. The myelographic findings in this case were unusual. There was a long segment of uniform concentric narrowing of the subarachnoid space with increased distance between the contrast column and the bony margins of the spinal canal on both sides from C2 to C6 (fig. 1). The levels of concentric narrowing of the subarachnoid space correlated with the surgical finding of diffuse thickening of the dura.

Hypertrophic spinal pachymeningitis [2, 3] and mucopolysaccharidosis [4] may give an identical myelographic appearance, the common pathogenesis being a diffuse thickening of the dura. Spondylosis may also produce diffuse narrowing of the subarachnoid space; however, the presence of bar formation at the disc levels and compression of the nerve roots are additional myelographic findings that should permit this diagnosis. Differentiation from arachnoiditis may be more difficult. In cases of arachnoiditis in which there is marked narrowing of the subarachnoid space, there is usually associated irregularity of the pantopaque column

Received August 13, 1979; accepted after revision November 19, 1979.

¹ All authors: Department of Radiology, Northwestern Memorial Hospital and Northwestern University Medical School, Superior Street and Fairbanks Court, Chicago, IL 60611. Address reprint requests to K. S. Kim.

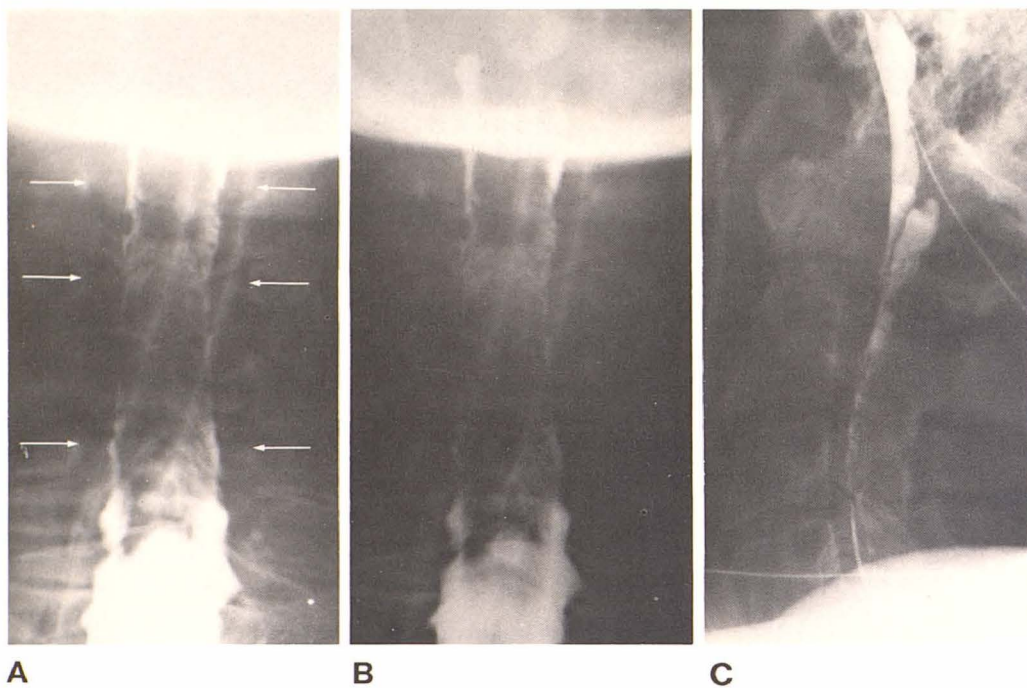


Fig. 1.—Cervical myelograms. **A**, Anteroposterior view. Subarachnoid space around cord uniformly narrowed and distance between contrast column and pedicles (arrows) increases from C2 to C6. **B**, Penetrated anteroposterior view. Normal subarachnoid space above C2 and below C6. **C**, Lateral view. Increased distance from contrast column to posterior vertebral margin. Lower cervical spinal canal obscured by shoulders.

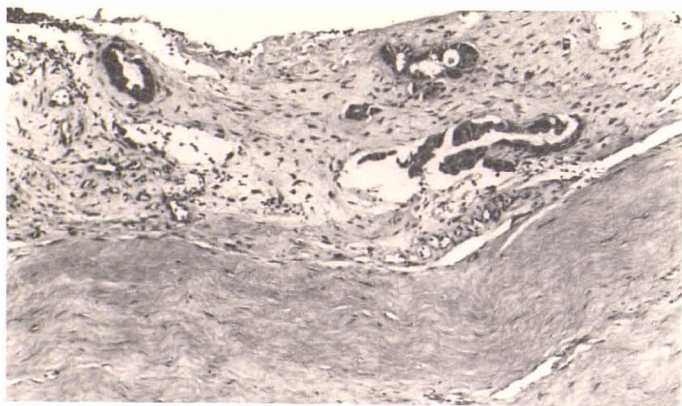


Fig. 2.—Photomicrograph of involved dura. Thickening and adenocarcinomatous infiltration. (H and E $\times 100$).

and varying degrees of obstruction to the flow of contrast. The marked concentric narrowing of the subarachnoid space without irregularity or obstruction in our case suggested that arachnoiditis would be unlikely.

REFERENCES

1. Grain GO, Karr JP. Leptomeningeal carcinomatosis: clinical and pathological characteristics. *Neurology* 1955;5:706-722
2. Wirth FP Jr, Gado M. Incomplete myelographic block with hypertrophic spinal pachymeningitis. *J Neurosurg* 1973;38:368-370
3. Taveras, JM, Wood EH. *Diagnostic Neuroradiology*. Baltimore: Williams & Wilkins, 1976;1164-1165
4. Sostrin RD, Hasso AN, Peterson DI, Thompson JR. Myelographic features of mucopolysaccharidosis: a new sign. *Radiology* 1977;125:421-424