



Discover Generics

Cost-Effective CT & MRI Contrast Agents



FRESENIUS
KABI

WATCH VIDEO

AJNR

MR imaging in Aicardi syndrome.

P Baierl, A Markl, M Thelen and M C Laub

AJNR Am J Neuroradiol 1988, 9 (4) 805-806

<http://www.ajnr.org/content/9/4/805.citation>

This information is current as
of June 25, 2025.

MR Imaging in Aicardi Syndrome

We have recently studied a case of Aicardi syndrome by sonography, CT, and MR of the brain and orbit, and we report on our findings, emphasizing the MR findings only.

Case Report

A 4-month-old girl (first child of healthy parents) was referred for evaluation of right-sided microphthalmia and focal seizures. The pregnancy and the development of the baby so far had been normal (birth weight, 3250 g; length, 52 cm; head circumference, 34 cm). No other abnormalities could be seen, and the neurologic examination did not show pathologic findings at this time. The EEG showed spike and wave complexes followed by asymmetrical activity (duration, 40–60 sec) in the right hemisphere. Eye movements to the right side and repeated infantile spasms could be related to the EEG pattern. On ophthalmologic examination, a chorioretinopathy lacunaris was found bilaterally. Extensive blood, urine, and CSF examinations did not reveal any abnormalities. Tests for antibodies against viruses and *Toxoplasma* were negative in both mother and child, and cytogenetic testing failed to show chromosomal aberrations. Radiographs of the spine and thorax were normal. Sonography, plain and contrast-enhanced CT, and MR (on a 1-T Siemens Magnetom imager) of the brain and orbit showed several abnormalities: complete absence of corpus callosum, two arachnoid cysts, and right-sided microphthalmia with a cystic intraorbital lesion (Fig. 1).

Discussion

Agenesis of the corpus callosum is due to a lesion of the commissural plate that occurs between the 12th and the 17th week of embryonic life or even earlier [1, 2]. A range of malformations is associated with callosal agenesis, as a result of lesions to other embryonic structures during this vulnerable period: cranial and ocular abnormalities, heterotopic gray matter, septooptic dysplasia, Dandy-Walker syndrome, Chiari malformation, interhemispheric cysts, midline lipomas, aqueduct stenosis, and porencephaly. Callosal agenesis

thus can be considered as one part of a developmental disturbance of the prosencephalon [3].

Advances in MR imaging now allow direct visualization of anatomic details previously seen only on gross dissection. Atlas et al. [4] were able to list 32 abnormalities intrinsic to agenesis of the corpus callosum and to assess their frequency in 11 patients. Obligatory findings in complete agenesis were high third ventricle, medially concave frontal horns, Probst bundles, absent midline cingulate sulci, lateral or absent fornices, and underdeveloped deep white matter. Culocephaly (persistence of the fetal dilatation of the atrium and occipital horns of the lateral ventricles) and hippocampal hypoplasia (keyhole temporal horns) occurred in all but one case.

Aicardi syndrome is characterized by agenesis of the corpus callosum, chorioretinopathy, and infantile spasms [5–7]. The syndrome occurs in females only. Other abnormalities associated with the syndrome are microphthalmia and coloboma, EEG changes, heterotopic gray matter, porencephaly, and vertebral abnormalities. The cause remains obscure, though an X-linked inheritance is discussed. The differential diagnosis includes congenital toxoplasmosis and other malformations of the midline structures (e.g., de Morsier septooptic dysplasia and related conditions [3]). At first, recognition of the Aicardi syndrome was based on ophthalmologic examinations and pneumoencephalography. Meanwhile CT has replaced pneumoencephalography in the diagnosis of callosal agenesis and other intracranial anomalies [1, 2]. Cranial sonography through the anterior fontanelle can show absence of the corpus callosum in infants [8].

Since Aicardi's description in 1965 [5], some 184 cases had been described by 1986. Up to now, three cases of Aicardi syndrome have been reported in MR literature [9, 10]. However, after CT diagnosis, as in our patient, additional anatomic details could be shown in the sagittal, frontal, and transverse MR images. All anomalies obligatory in agenesis of the corpus callosum [4] were found in our patient. The images were negative for heterotopic gray matter and for changes in the brainstem and posterior fossa. The cystic orbital lesion may be one of the ophthalmologic features of Aicardi syndrome reported in the literature [6]: coloboma, intraocular mass, microphthalmia, synechia of the iris, and so forth. A duplication of the right eyeball also was discussed, but a fine membrane was seen in all images between the true eyeball and the cystic lesion. In summary, MR imaging provides a good basis for a thorough assessment of the anatomic

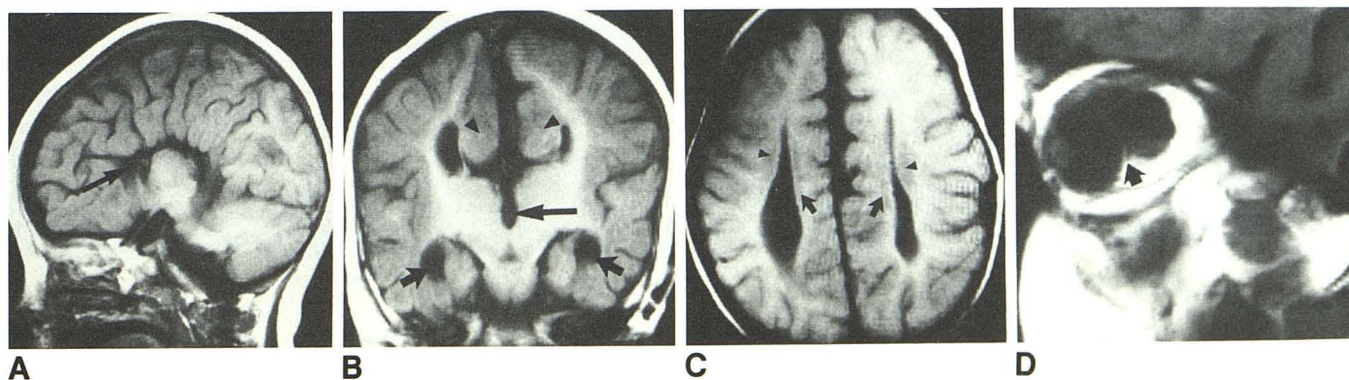


Fig. 1.—Aicardi syndrome in a 4-month-old girl.

A, T1-weighted sagittal MR image, SE 500/28, shows complete absence of corpus callosum, "sunburst pattern" of radiating gyri and elevated third ventricle (arrow). Cingulate gyrus is displaced laterally and is not seen here.

B, T1-weighted frontal MR image, SE 500/28, shows widely separated ventricles, wide interhemispheric fissure, keyhole deformity of temporal horns due to hippocampal deficiency (short arrows), elevated third ventricle (long arrows), and rotated and hypertrophied cingulate gyrus (arrowheads).

C, T1-weighted axial MR image, SE 2000/28, shows deficiency of centrum semiovale (arrowheads) and Probst bundles (arrows).

D, T1-weighted sagittal MR image of orbit, SE 500/28, shows right-sided microphthalmia and cystic space-occupying intraorbital lesion. Signal intensity of lesion is equal to intensity of eyeball. A thin membrane separates lesion and eyeball (arrow).

changes found in Aicardi syndrome and provides information that is hardly available with any other imaging technique.

Peter Baierl
August Markl
Marianne Thelen
University of Munich
Munich 2, Federal Republic of Germany
Michael C. Laub
Behandlungszentrum
Vogtareuth, Federal Republic of Germany

REFERENCES

1. Guibert-Tranier F, Piton J, Caille JM. Agenesis of the corpus callosum. *J Neuroradiol* **1982**;9:135-160
2. Kendall BE. Dysgenesis of the corpus callosum. *Neuroradiology* **1983**;25:239-256
3. Laub MC, Walther JU, Boergen K. Sonographic imaging of congenital brain midline defects with ocular involvement. In: Neetens A, ed. *Proceedings neuro-ophthalmology*. Antwerp: University of Antwerp, **1984**:259-262
4. Atlas SW, Zimmerman RA, Bilaniuk LT, et al. Corpus callosum and limbic system: neuroanatomic MR evaluation of developmental anomalies. *Radiology* **1986**;160:355-362
5. Aicardi J, Lefebvre J, Lerique-Koechlin A. A new syndrome: spasm in flexion, callosal agenesis, ocular abnormalities. *Electroencephalogr Clin Neurophysiol* **1965**;19:609-610
6. Renier W, Gabreels F, Mol L, Korten J. Agenesis of the corpus callosum, chorioretinopathy and infantile spasms (Aicardi syndrome). *Psychiatr Neurol Neurochir* **1973**;76:39-45
7. Deodati F, Bec P, Carrière JP, Labro JB. Le syndrome d'Aicardi. *Arch Ophthalmol (Paris)* **1974**;34:85-98
8. Gebarski SS, Gebarski KS, Bowerman RA, Silver TM. Agenesis of the corpus callosum: sonographic features. *Radiology* **1984**;151:443-448
9. Curnes JT, Laster DW, Koubek TD, Moody DM, Ball MR, Witcofski RL. MRI of corpus callosal syndromes. *AJNR* **1986**;7:617-622
10. Igidbashian V, Mahboubi S, Zimmerman RA. CT and MR findings in Aicardi syndrome. *J Comput Assist Tomogr* **1987**;11:357-358