



Discover Generics

Cost-Effective CT & MRI Contrast Agents



WATCH VIDEO

AJNR

Preoperative embolization of brain AVMs with isobutyl-2 cyanoacrylate.

D M Pelz, A J Fox, F Viñuela, C C Drake and G G Ferguson

AJNR Am J Neuroradiol 1988, 9 (4) 757-764

<http://www.ajnr.org/content/9/4/757>

This information is current as
of June 28, 2025.

Preoperative Embolization of Brain AVMs with Isobutyl-2 Cyanoacrylate

David M. Pelz^{1,2}
 Allan J. Fox^{1,2}
 Fernando Viñuela^{1,2,3}
 Charles C. Drake²
 Gary G. Ferguson²

The role of embolization in the management of brain arteriovenous malformations remains controversial. The benefits of embolization alone are not clear and surgical removal may be technically difficult or impossible in many cases. In an attempt to facilitate surgical removal, we performed preoperative embolization in 15 cases using a mixture of isobutyl-2 cyanoacrylate and glacial acetic acid. In one case, a mixture of polyvinyl alcohol particles, microfibrillar collagen, and 30% ethanol was used. In 10 of these cases the surgeon felt that the embolization significantly aided the operative removal by decreasing blood loss, reducing the size of draining veins, and removing portions of the nidus itself. In no patient did the embolization result in an unanticipated significant neurologic deficit.

The major role for embolization in the management of brain arteriovenous malformations may be as an aid to surgical removal.

The role of embolization in the management of brain arteriovenous malformations (AVMs) continues to evolve as the possibilities and limitations of present techniques become apparent. Complete obliteration of these lesions with isobutyl-2 cyanoacrylate (IBCA) or other materials is not common [1, 2] and may be impossible in large, complex AVMs. Partial obliteration without surgical removal may be helpful for the management of progressive neurologic deficits and severe localized headaches [3, 4]. Evidence that partial obliteration reduces the risks of future events, especially hemorrhage, is lacking [1, 5–7]. In our institution we are now attempting embolization primarily in cases of large AVMs as a preoperative measure to decrease the risk of major intraoperative hemorrhage. Embolization has also been performed in cases of compelling progressive deficit or headache in which surgery is not to be performed and partial embolization may provide some relief of symptoms. Our objective is to demonstrate that preoperative embolization can significantly aid the surgical removal of brain AVMs.

Materials and Methods

The clinical records and radiographs of 15 patients who underwent preoperative embolization of brain AVMs at our institution since January 1985 were reviewed for details of clinical presentation, radiographic findings, and neuroradiologic therapy. It was at this time that we began to add between 20 and 40 μ l of glacial acetic acid to our embolization mixture of 1 ml IBCA, 1 g tantalum powder, and 0.3 ml iophendylate. The addition of glacial acetic acid offers an effective way to manipulate and lengthen the polymerization time without increasing the viscosity of the mixture [8].

All the AVMs in this series were moderate to large in size (2–5 cm in diameter) with multiple feeding vessels, and were considered to be surgically treatable once their size was reduced by preoperative embolization. The lesions were either hemispheric or cerebellar. Any lesions in the brainstem, ganglionic, or thalamic region that were not surgically approachable were excluded from the study. Small lesions with only one or two principal feeders in which the surgeon felt that embolization would confer no benefit to the removal were also not included.

Received June 29, 1987; accepted after revision November 19, 1987.

¹ Department of Radiology, University Hospital, University of Western Ontario, 339 Windermere Rd., London, Ontario Canada N6A 5A5. Address reprint requests to D. M. Pelz.

² Department of Clinical Neurological Sciences, University Hospital, University of Western Ontario, London, Ontario, Canada.

³ Present address: Department of Radiological Sciences, UCLA Medical Center, Los Angeles, CA 90024-1721.

AJNR 9:757–764, July/August 1988

0195–6108/88/0904–0757

© American Society of Neuroradiology

In each patient, multiple small injections of this mixture were initially made into the AVM with the intent to decrease the nidus size as much as possible. The calibrated-leak, latex balloon delivery system [9, 10] was used in all cases except in one case in which the Tracker* catheter was used for three injections. The tip of the catheter was usually placed 1.5–2.0 cm from the AVM nidus whenever possible. If the distance from the nidus was greater, careful evaluation with a sodium amytal test was necessary to ensure that normal vessels would not be embolized. When the balloon catheter was thought to be in satisfactory position for embolization, a superselective injection of 20–25 mg sodium amytal was usually performed to assess any potential neurologic sequelae. This dosage has recently been increased to 40 mg. Patients were immediately tested for any gross motor or sensory deficits or any speech disturbance. A superselective angiogram was then performed to assess balloon behavior and circulation time through the AVM. This helps in the calibration of IBCA polymerization time to facilitate deposition of embolic material in the AVM nidus rather than in feeding arteries or draining veins. The system was then thoroughly flushed with dextrose and the dead space of the catheter was filled with 0.1 or 0.2 ml of embolization mixture. This was then pushed with 1.0 ml of dextrose, producing a shower of embolic material that disseminated and polymerized mostly within the AVM nidus. The balloon catheter was then removed each time and replaced for the next embolization with another catheter. Theoretically, a catheter could be left in place for further injections if thorough flushing with dextrose is performed. Larger feeding vessels were also occluded at the end when it was thought that further safe embolization of the nidus was not possible.

The operative records and surgeons' reports were closely examined for details of blood loss and technical difficulties during surgery. Neurologic status before and after the embolizations and operations as well as the subsequent clinical course was recorded.

Results

Clinical and neuroradiologic data are summarized in Table 1. There were 15 patients in this study group ranging in age from 12–54 years. Ten patients presented with prior hemorrhage, four with intractable seizures, and one with headache, visual field defect, and diplopia. All the AVMs were moderate (2–4 cm in diameter) to large (greater than 5 cm in diameter) in size and seven of the lesions were located in the frontal lobes or corpus callosum, five in the parietal or parietooccipital regions, one in the occipital lobe, and two in the cerebellum.

In each case, the angiograms were critically reviewed with a consulting neurosurgeon and the joint decision to attempt embolization of the lesion was made after the surgeon had decided that operative removal was indicated and possible.

The number of individual injections ranged from three injections in one session in two patients to 20 injections in four sessions in one patient. Superselective angiograms and sodium amytal tests preceded all embolizations. The embolization sessions were generally well tolerated and were technically uneventful except for one case, in which the balloon catheter had to be left in place in the anterior cerebral artery after one injection of 0.15 ml IBCA mixture. After thorough flushing with dextrose, an injection of iohexol was made through the catheter, which apparently initiated polymerization of a small amount of residual glue, possibly from the

needle stub adapter of the catheter, which then filled and blocked the balloon. The balloon therefore could not be deflated and on attempted withdrawal it moved back about 5 cm and stuck within the vessel. The silastic tubing then broke in the distal common carotid artery, but fortunately the tubing entered the external carotid artery and remained securely in this position with no clinical sequelae.

The amount of AVM obliteration by embolization ranged from approximately 80–90% in three patients (Fig. 1) to no appreciable change in one patient. In 10 patients there was an approximately 50–75% decrease in the AVM nidus size (Fig. 2), and in one patient a 40–50% obliteration. Seven patients developed new neurologic deficits or worsening of their previous deficits from the embolization, five patients developed new neurologic deficits from the embolization alone, and three patients developed a visual field defect; all were known risks that had been accepted by the patients prior to the procedure. One of these deficits cleared prior to surgery (case 1). Four patients also developed mild weakness as a result of the interventional procedure, one such weakness remained prior to surgery (case 11) with gradual recovery postoperatively. Therefore, three of 15 patients (20%) developed new deficits from the embolization, two of which were predictable and accepted by the patients prior to the procedure.

Surgical removal of the lesions was performed within the first 2 weeks after embolization in 11 patients. In two patients, the surgery was at 2–3 months, one was at 5 months, and another was at 7 months postembolization. In the cases of delayed surgery, the operation was postponed until resolution of transient neurologic deficits or until the patients were willing to undergo a major neurosurgical procedure. In 10 of these cases, the surgeon felt that preoperative embolization had significantly enabled the surgical removal by limiting intraoperative bleeding. The surgery notes contained comments that the surgeon believed were related to the embolization, such as the ease of dissection, the large number of thrombosed veins, and the minimal blood loss. In one patient the surgeon thought that surgical removal would have been extremely difficult without prior embolization (Fig. 2). All patients except for one have done well postoperatively, with mild residual deficits persisting in nine patients.

Discussion

The development of endovascular interventional techniques was initially conceived as an adjunct to surgical removal of lesions [7]. The techniques of endovascular occlusion then evolved into a definitive therapy for lesions that were considered inoperable [1, 9, 10]. Initial enthusiasm for embolotherapy centered on the belief that significant or complete obliteration of the AVM could be attained. Large amounts of IBCA mixed with tantalum and iophendylate [1, 9] were injected into AVM feeders in hopes of obliterating the nidus. The risks of this aggressive approach have become apparent, and include such complications as stroke after inadvertent embolization of normal vessels, balloon rupture of vessels, gluing of balloons in vessels, severe vasogenic edema, breakthrough

* Target Therapeutics, 2100 S. Sepulveda Blvd., Los Angeles, CA 90025.

TABLE 1: Preoperative Embolization of Brain AVMs

Case No.	Age	Gender	Clinical Presentation	AVM Location and Principal Feeders	Embolizations and Complications	Percent Embolized	Surgery	Course
1.	28	M	SAH	Giant R parietal ACA, MCA	20 injections in 4 sessions; L arm drift and homonymous hemianopia post-embolization; recovered preop	50–75%	Complete removal 5 months post-embolization; 2 operating room sessions; 4 U-packed cells	L arm drift and homonymous hemianopia postop; gradually improving
2.	38	F	Diplopia, headache, R homonymous hemianopia	Medium L parietooccipital PCA, MCA, ACA	8 injections in 2 sessions; dense R homonymous hemianopia post-embolization	70–80%	Complete removal 7 months post-embolization; 3½ hr surgery; no blood replacement	Persistent R hemianopia; embolization helped surgery
3.	45	M	ICH	Large R frontal ACA, MCA	7 injections in 2 sessions; mild L hemiparesis and confusion postembolization; resolved in 48 hr	60–70%	Complete removal 3 months post-embolization	L hemiparesis postop, which resolved; persistent memory deficit; embolization helped surgery
4.	54	M	ICH; R homonymous hemianopia; mild R-sided weakness	Large L parietooccipital splenium of corpus callosum ACA, MCA, PCA	9 injections in 3 sessions; ACA, MCA, MCA embolized; no complications	50–60%	Complete removal 7 days postembolization	Mild R homonymous hemianopia on discharge; embolization helped surgery
5.	29	F	Seizures	Large R mesiofrontal ACA, MCA	3 injections into ACA in 1 session; no complications	40–50%	Complete removal 5 days postembolization; 5 U-packed cells	No deficits
6.	12	M	Cerebellar hemorrhage, diplopia	Large R cerebellum SCA, PICA	8 injections into SCA in 2 sessions; no complications	50%	Complete removal 3 days postembolization; 14-hr operation	No worsening of deficits postop; gradual recovery
7.	21	M	Seizures	Giant R frontal ACA, MCA	17 injections in 3 sessions; no complications	70–75%	Complete removal 7 days postembolization; 5 U-packed cells	Good recovery

TABLE 1—Continued

Case No.	Age	Gender	Clinical Presentation	AVM Location and Principal Feeders	Embolizations and Complications	Percent Embolized	Surgery	Course
8.	35	F	SAH and cerebellar hemorrhage clot evacuation and partial AVM removal 9 months PTA, akinetic mutism, quadriparetic	Large cerebellar vermis L and R SCA	2 injections into L SCA; no complications	50–75%	Complete removal 7 days postembolization; surgeon remarks on large thrombosed veins	Initially unchanged postop, respiratory arrest 3 days postop, remains locked-in on respirator
9.	34	F	SAH	Giant R frontal MCA, ACA	17 injections in 3 sessions; no complications	50–75%	95% removal 3 days postembolization; great deal of bleeding from ACA and MCA feeders	Patient refused further surgery; embolization not very helpful
10.	25	M	SAH	Moderate R parietooccipital ACA, PCA, MCA	4 injections into PCA in 1 session; developed L homonymous hemianopia and mild L-sided weakness; developed small ICA 3 days postembolization	90%	Complete removal 2 months postembolization	Residual complete L hemianopia
11.	19	M	SAH, ICH	Giant L frontal and corpus callosum R and L ACA	14 injections in 2 sessions; developed weak L foot postembolization	60–70%	Complete excision 5 days postembolization; 2½ hr surgery; minimal blood loss; no blood replacement	Gradual improvement in strength of L foot; embolization helped surgery
12.	46	M	SAH, ICH	Giant L parietooccipital ACA, MCA, PCA	8 injections in 2 sessions; R inferior quadrant anopia postembolization; gradual recovery	80–90%	Complete removal 2 weeks postembolization	Complete R homonymous hemianopia postop
13.	32	M	Seizures	Large L parietal ACA, MCA, PCA	16 injections in 4 sessions; balloon catheter broke in common carotid artery	50–75%	Complete removal 3 days postembolization	No neurologic deficit

TABLE 1—Continued

Case No.	Age	Gender	Clinical Presentation	AVM Location and Principal Feeders	Embolizations and Complications	Percent Embolized	Surgery	Course
14.	19	F	ICH, dysarthria and R hemiparesis; gradual complete recovery	Large L frontal and sylvian MCA, lenticulostriates	3 injections in 1 session; unable to catheterize large lateral lenticulostriate feeder; no complications	No significant change	Complete removal 4 days postembolization under local anesthetic	Mild dysarthria, slowly improving
15.	26	F	Seizures	L frontal opercular MCA, ACA feeders	2 sessions; (1) Tracker Avitene/Ivalon/ethanol mixture 0.2 ml × 5; (2) IBCA 0.2 ml × 2; no complications	80–90%	Complete excision 4 days postembolization	No deficit

Note.—SAH = subarachnoid hemorrhage, ACA = anterior cerebral artery, MCA = middle cerebral artery, R = right, L = left, PCA = posterior cerebral artery, ICH = intracerebral hemorrhage, SCA = superior cerebellar artery, PICA = posterior inferior cerebellar artery, PTA = prior to admission, ICA = internal carotid artery.

hemorrhage, and death [1, 2, 5, 11, 12]. Despite modifications in technique, the procedure remains technically demanding and limited in large AVMs to partial obliteration because of these risks. Complete obliteration has been possible only in small, simple AVMs fed by only one or two major feeders.

It would seem that complete surgical removal should be the goal in any attempted curative treatment for large cerebral AVMs that have bled [13, 14]. Many AVMs, particularly large cortical and cerebellar lesions, may be amenable to surgery but technically difficult to remove. It is in these cases that embolization may be of value to decrease nidus size, reduce the size of arterial feeders and draining veins, and occlude fistulous connections. These factors can combine to enable easier, less dangerous surgical removal. In those cases in which deep arterial feeders may be difficult to expose, preoperative occlusion may similarly aid the surgeon [3]. Blocking major feeding vessels alone without obliterating or surgically removing the nidus is of no use or may even be detrimental because this leads to greater participation of deeper, less accessible feeders [15]. In our experience, embolization has been particularly valuable in lesions of the corpus callosum involving primarily anterior cerebral artery supply and lesions of the occipital lobes supplied primarily by a large posterior cerebral artery.

The technique of using multiple small injections of embolization mixture, including glacial acetic acid and pushed with dextrose, has been an effective modification in our experience. It allows a more controllable, safer injection that is more likely to deliver embolic material to the nidus, leaving larger feeders intact. There is less risk of gluing balloons in place

and there is a theoretical advantage of using the same balloon for several injections, although this advantage has not yet been realized in our experience. We have had problems with the one case where this was tried, possibly due to accumulation of IBCA in the well of the Luer lock end of the catheter, which then plugs the balloon on subsequent injections. We therefore currently continue to remove the catheter after each glue injection.

In our series, a significant decrease in AVM nidus size was obtained by embolization in all but one patient and surgical removal was facilitated in 10 of 15 patients. In one patient, it was thought that surgery would have been extremely difficult without prior embolization. In 20% of our cases, new neurologic deficits were produced by the embolization alone; however, two of these were visual field defects accepted by the patient. In one patient, mild foot weakness persisted prior to surgery. The relative safety in this small series may relate to the fact that multiple small injections of a less viscous mixture of IBCA pushed with dextrose are safer and more controllable than a large bolus injection. The staging of the procedure over several days may also help prevent perfusion breakthrough bleeding.

The overall surgical morbidity in this small series is six of 15 cases, but this includes four cases of visual field defect that were accepted by the patients prior to surgery. Our figures compare favorably with those of Luessenhop and Rosa [16], who quote a 10% mortality and 30% morbidity in the surgical treatment of large cerebral AVMs.

We have recently begun using a modification of this technique for preoperative embolization using newly available

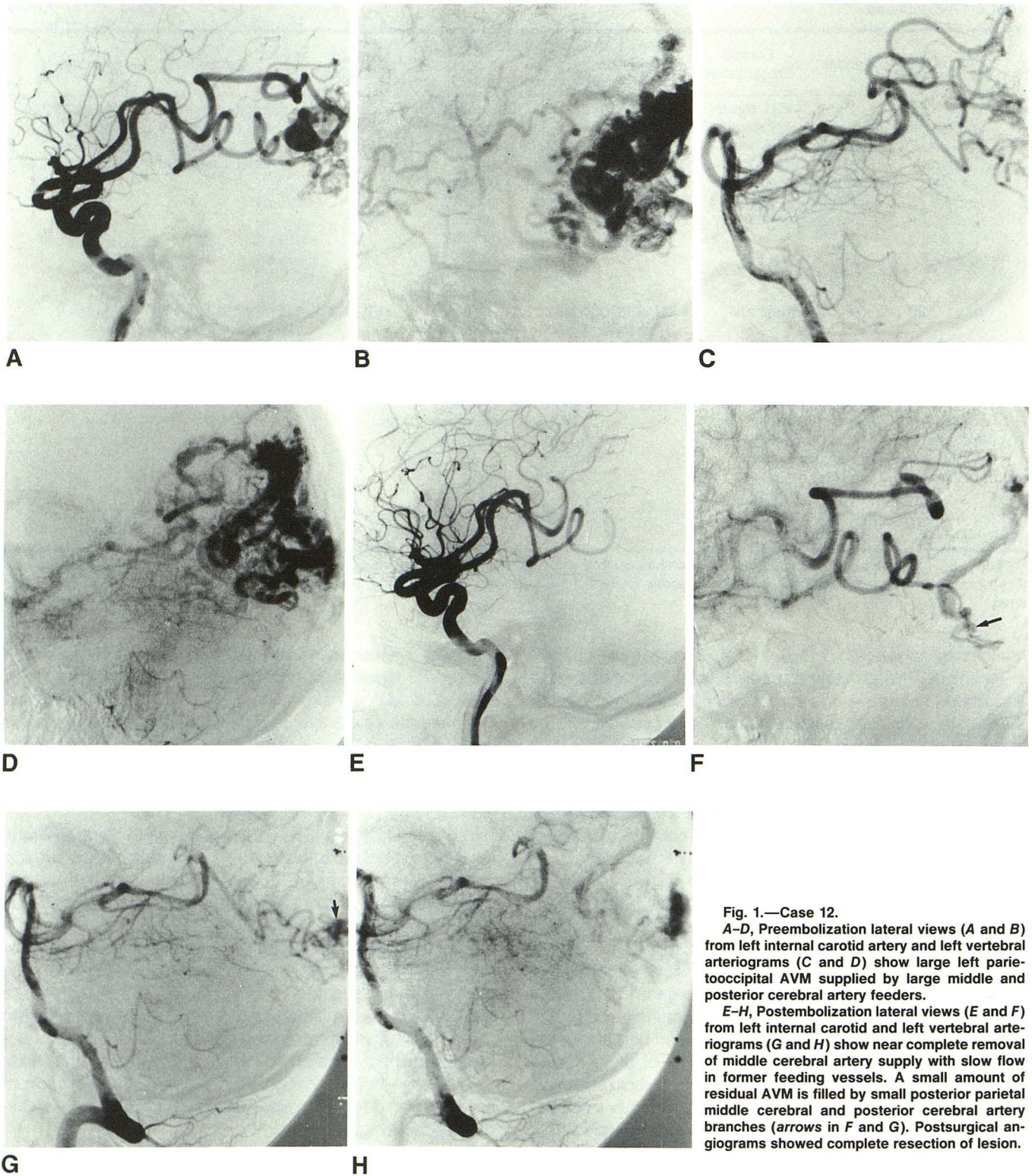


Fig. 1.—Case 12.

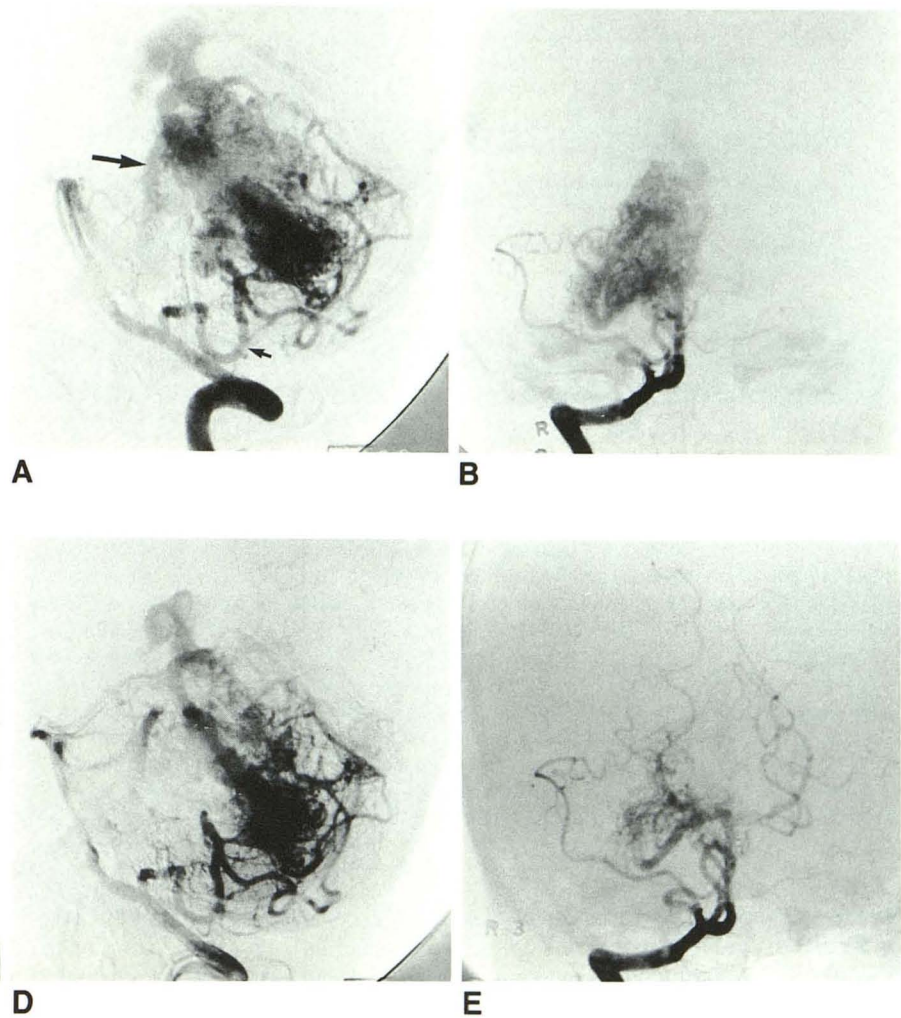
A-D, Preembolization lateral views (A and B) from left internal carotid and left vertebral arteriograms (C and D) show large left parietooccipital AVM supplied by large middle and posterior cerebral artery feeders.

E-H, Postembolization lateral views (E and F) from left internal carotid and left vertebral arteriograms (G and H) show near complete removal of middle cerebral artery supply with slow flow in former feeding vessels. A small amount of residual AVM is filled by small posterior parietal middle cerebral and posterior cerebral artery branches (arrows in F and G). Postsurgical angiograms showed complete resection of lesion.

Fig. 2.—Case 6.

A and B, Right vertebral arteriograms. Preembolization lateral (**A**) and anteroposterior (**B**) views show large right cerebellar AVM supplied by large right superior cerebellar artery (*large arrow in A*) and large right posterior inferior cerebellar artery (*small arrow in A*).

C–E, Postembolization lateral (**C** and **D**) and anteroposterior (**E**) views show removal of superior aspect of AVM with occlusion of superior cerebellar artery (*open arrow*). Right posterior inferior cerebellar artery continues to fill inferior aspect of lesion. Postoperative angiograms show complete resection of AVM.



technology. We are now employing the 2-French Tracker catheter, which will advance quite far distally into the cerebral vessels. After superselective injections of 40 mg of sodium amytal, we are now embolizing with a mixture containing Ivalon particles[†] (200–300 μ size), Avitene[‡] (100 mg), and

30% ethanol. Injections range from 0.2–1.0 ml of this mixture and our initial results have been encouraging (Fig. 3). In our first case, the angiographic results were so favorable that surgery was deferred and a follow-up angiogram has been arranged to assess potential recanalization.

Our experience indicates that close cooperation between neuroradiologists and neurosurgeons is essential for the development of rational therapeutic strategies in cases of large brain AVMs, and that embolization can significantly aid the surgical removal of these challenging lesions.

[†] Polyvinyl alcohol particles. Pacific Medical Industries, Inc., San Diego, CA 92122.

[‡] Avitene microfibrillar collagen hemostat. Alcon Laboratories, Inc., Fort Worth, TX 76134.

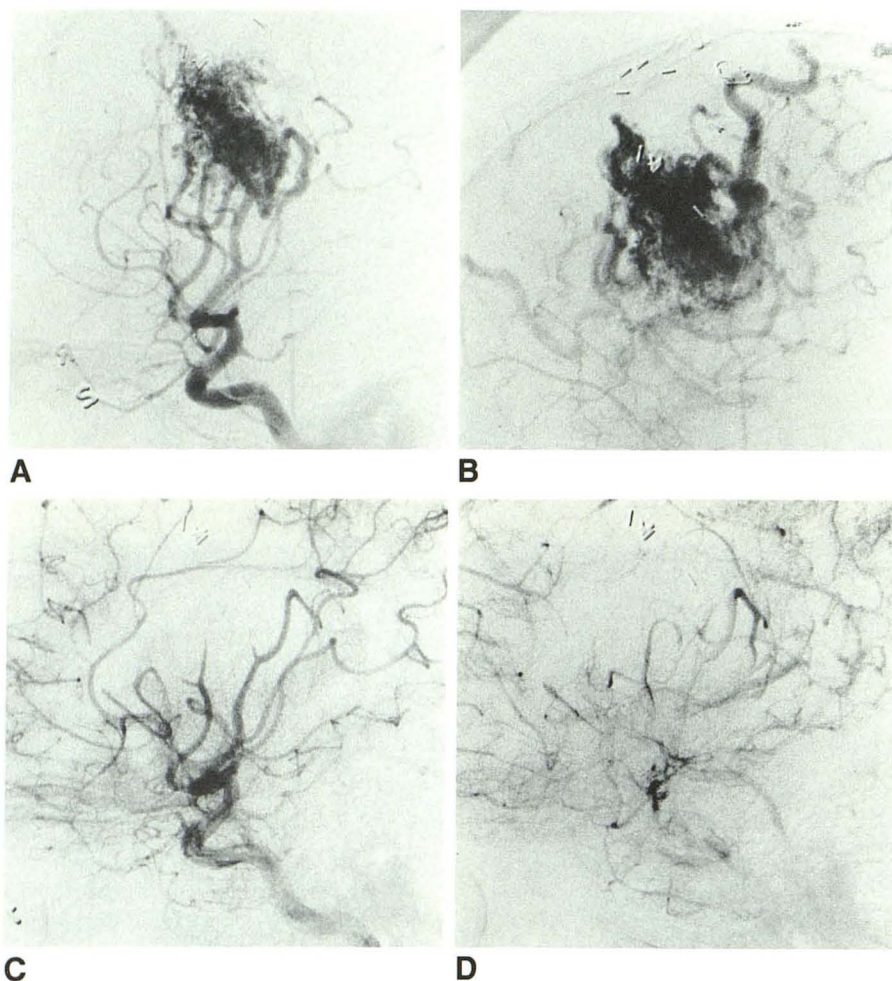


Fig. 3.—14-year-old boy with prior intracerebral hemorrhage from large right prerolantic AVM.

A and B, Right common carotid arteriograms, lateral views from early and late arterial phases. Large right frontal prerolantic AVM supplied primarily by large middle cerebral artery branches.

C and D, Postembolization right internal carotid arteriograms, mid and late arterial phases. After embolization of middle cerebral artery branches with a mixture of Ivalon, Avitene, and 30% ethanol, there has been virtual obliteration of AVM. Patient was completely intact after the procedure.

REFERENCES

- Debrun G, Viñuela F, Fox AJ, Drake CG. Embolization of cerebral arteriovenous malformations with bucrylate. Experience in 46 cases. *J Neurosurg* 1982;56:615-627
- Viñuela F, Fox AJ. Interventional neuroradiology in the management of arteriovenous malformations and fistulas. *Neurol Clin North Am* 1983;1:131-154
- Fox AJ, Girvin JP, Viñuela F, Drake CG. Rolandic arteriovenous malformations: improvement in limb function by IBC embolization. *AJNR* 1985;6:575-582
- Kusske JA, Kelly WA. Embolization and reduction of the "steal" syndrome in cerebral arteriovenous malformations. *J Neurosurg* 1974;40:313-321
- Viñuela F, Debrun G, Fox AJ, Girvin JP, Peerless SJ. Dominant hemisphere arteriovenous malformations: therapeutic embolization with isobutyl-2 cyanoacrylate. *AJNR* 1983;4:959-966
- Viñuela F, Fox AJ, Debrun G, Drake CG, Peerless SJ, Girvin JP. Progressive thrombosis of brain arteriovenous malformations after embolization with isobutyl-2 cyanoacrylate. *AJNR* 1983;4:1233-1238
- Luessenhop AJ, Presper JH. Surgical embolization of cerebral arteriovenous malformations through internal carotid and vertebral arteries: long-term results. *J Neurosurg* 1975;42:443-451
- Spiegel SM, Viñuela F, Goldwasser JM, Fox AJ, Pelz DM. Adjusting the polymerization time of isobutyl-2 cyanoacrylate. *AJNR* 1986;7:109-112
- Kerber CW, Bank WO, Cromwell LD. Calibrated leak balloon microcatheter: a device for arterial exploration and occlusive therapy. *AJR* 1979;130:207-212
- Debrun G, Viñuela F, Fox AJ, Kan S. Two different calibrated leak balloons: experimental work and applications in humans. *AJNR* 1982;2:407-414
- TerBrugge KG, Lasjaunias P, Chiu MC. Surgical neuroangiography of intracranial vascular malformations. *Can J Neurol Sci* 1987;14:70-74
- Viñuela F, Fox AJ, Debrun G, Pelz D. Preembolization superselective angiography: role in the treatment of brain arteriovenous malformation with isobutyl-2 cyanoacrylate. *AJNR* 1984;5:765-769
- Graf CJ, Perret GE, Torner JC. Bleeding from cerebral arteriovenous malformations as part of their natural history. *J Neurosurg* 1983;58:331-337
- Fults D, Kelly DL Jr. Natural history of arteriovenous malformations of the brain: a clinical study. *Neurosurgery* 1984;15:658-662
- Drake CG. Cerebral arteriovenous malformations: considerations for and experience with surgical treatment in 166 cases. *Clin Neurosurg* 1979;26:145-208
- Luessenhop AJ, Rosa L. Cerebral arteriovenous malformations: indications for and results of surgery, and the role of intravascular techniques. *J Neurosurg* 1984;60:14-22