



## Discover Generics

Cost-Effective CT & MRI Contrast Agents

 FRESENIUS  
KABI

[WATCH VIDEO](#)

# AJNR

## Myelographic study of the spinal cord ascent during fetal development.

N D Hawass, M G el-Badawi, J A Fatani, A A Meshari, F S Abbas, Y B Edrees, F A Jabbar and M Banna

*AJNR Am J Neuroradiol* 1987, 8 (4) 691-695

<http://www.ajnr.org/content/8/4/691>

This information is current as  
of June 24, 2025.

# Myelographic Study of the Spinal Cord Ascent During Fetal Development

N. D. Hawass<sup>1</sup>  
 M. G. El-Badawi<sup>1</sup>  
 J. A. Fatani<sup>1</sup>  
 A. A. Meshari<sup>1</sup>  
 F. S. Abbas<sup>1</sup>  
 Y. B. Edrees<sup>2</sup>  
 F. A. Jabbar<sup>3</sup>  
 M. Banna<sup>3</sup>

To assess the length of the spinal cord relative to the vertebral column during fetal development, we performed translumbar myelograms on 340 spontaneously aborted fetuses. Of these, 146 were selected for study. There were 76 males and 70 females, with fetal age ranging from 7 to 33 weeks. Significant variation in the level of spinal cord termination was found in fetuses between 12 and 25 weeks gestational age. In fetuses between 25 and 33 weeks gestational age, the cord ended at or above the third lumbar vertebra.

The study of spinal cord termination in embryonal life has hitherto been limited to anatomic dissection carried out many years ago [1]. The information obtained at that time—that the vertebral column increases in length at a much faster rate than the spinal cord does, resulting in what is generally known as “ascent” of the spinal cord—was later passed on from one author to another. In the normal fetus, the information continues, the vertebral column and the spinal cord are of equal length up to the second [2] or perhaps the third month [3, 4]. According to Streeter [1], the spinal cord starts to “ascend” after 9 weeks, reaching the level of the last sacral piece around 12 weeks of age. The cord reaches the level of the lower border of the first sacral piece at 15 weeks, the lower border of the fourth lumbar vertebra at 6 months, and the lower border of the third lumbar vertebra at full term.

Employing a radiologic approach, the present study was undertaken for two reasons: (1) to verify the findings published in the early years of anatomic dissection, and (2) to determine the rate at which the spinal cord normally “ascends.”

## Materials and Methods

Translumbar myelograms were obtained on 340 spontaneously aborted fetuses as part of a major multidisciplinary project of normal and abnormal fetuses. Of these, 146 were selected for this study, including 76 males and 70 females. Fetal age was estimated on the basis of crown-rump length (CRL) [5]. The smallest fetus was 7 weeks old, with a crown-rump length of 19 mm and a weight of 0.81 g; the largest fetus was 33 weeks old. Selection of the cases was based on absence of any relevant morphologic abnormality, on inspection and anatomic dissection, and on clear depiction of the conus medullaris at myelography. The tip of the conus medullaris was defined as the point at which two lines drawn along its lateral sloping borders meet.

## Technique

Access to the subarachnoid space was made by the translumbar route in all cases. A 27-French-gauge butterfly needle was used in large fetuses. In smaller fetuses, especially made 30- and 35-French-gauge needles were used. The needle was inserted into the lumbar region with slight angulation and was carefully advanced until it was felt to penetrate the dural sac. The position of the needle within the subarachnoid space was verified by injecting 0.1 ml or less of contrast medium through a tuberculin syringe. If the needle was correctly placed, a

Received May 6, 1986; accepted after revision November 25, 1986.

This work was supported by the King Abdul Aziz Center for Science and Technology under grant number AT-5-64.

<sup>1</sup> Department of Radiology (40), College of Medicine, King Saud University Hospital, P.O. Box 2925, Riyadh 11461, Saudi Arabia. Address reprint requests to N. D. Hawass.

<sup>2</sup> The Riyadh Maternity Hospital, Riyadh 11196, Saudi Arabia.

<sup>3</sup> King Faisal Specialist Hospital, Riyadh 11211, Saudi Arabia.

AJNR 8:691-695, July/August 1987  
 0195-6108/87/0804-0691

© American Society of Neuroradiology



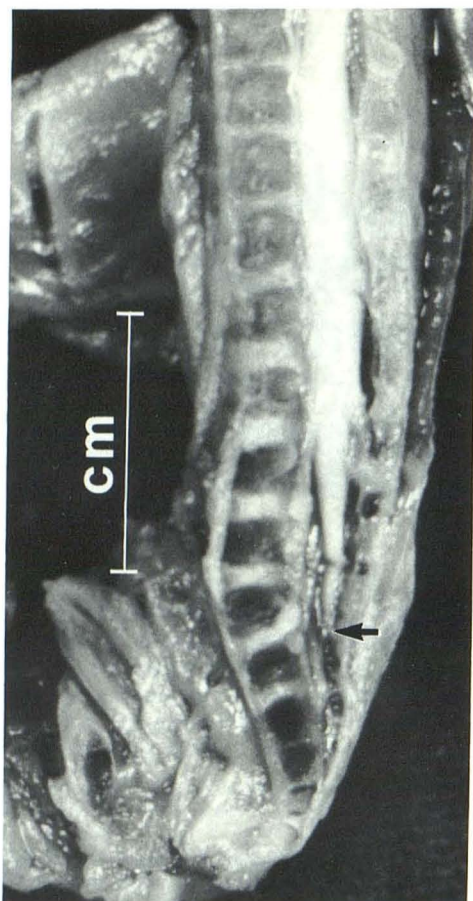


Fig. 1.—Sagittal section of a fetus with crown-rump length of 9.6 cm. Arrow indicates spinal cord termination.

small amount of meglumine iothalamate (Conray 280) was injected. The amount of contrast medium required to outline the entire cord varied with the size of the fetus. All myelograms were performed within 48 hr from the time of abortion. Formalin as a preservative was avoided because correct placement of the needle was difficult to achieve in preserved fetuses. After the completion of the radiologic study, all fetuses were taken to the anatomy laboratory where different anthropometric measurements were recorded. The CRL was used to estimate gestational age [5]. All fetuses were routinely dissected and a binocular stereomicroscope was used when necessary. Early in this series, the spinal cord of some fetuses was exposed prior to fixation to verify the level of spinal cord termination. In other fetuses, multiple sagittal sections were performed for the same purpose (Fig. 1). Correlation of radiologic and anatomic findings proved to be very accurate. Nonscreen mammographic films were preferred for this study, and an X-ray tube with a 0.2-mm focal spot was used.

Measurement of the length of the spinal cord and vertebral column was made from the interpediculate line of the 12th thoracic vertebra to the last sacral segment. We chose the 12th thoracic vertebra for two reasons: (1) it is the level below which there is discrepancy between the cord and the vertebral column length, and (2) the spine distal to the 12th thoracic vertebra in infants is almost straight. Measurement of the entire length of the vertebral column and spinal cord was avoided because: (1) it is not possible to determine where the spinal cord begins, and (2) the presence of dorsal kyphosis makes an exact measurement difficult. If the last sacral segments were not ossified, their height was assumed to be equal to the adjacent ossified segment and measurements were made accordingly. If the last ribs were not ossified or if there was a questionable cervical rib, the 12th thoracic vertebra was identified as the 19th segment commencing with the atlas. Thus, the disparity between vertebral column length and spinal cord length was calculated on the basis of measurements made between the 12th thoracic vertebra and the end of the spine or cord.

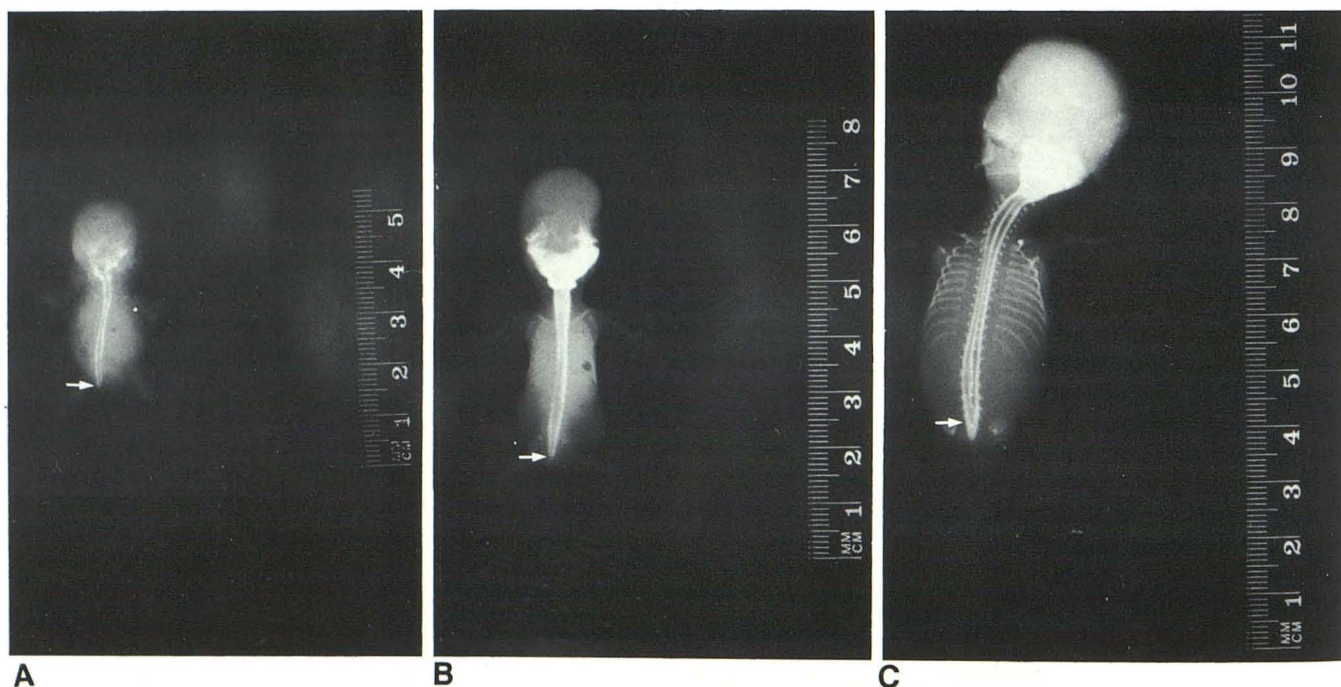
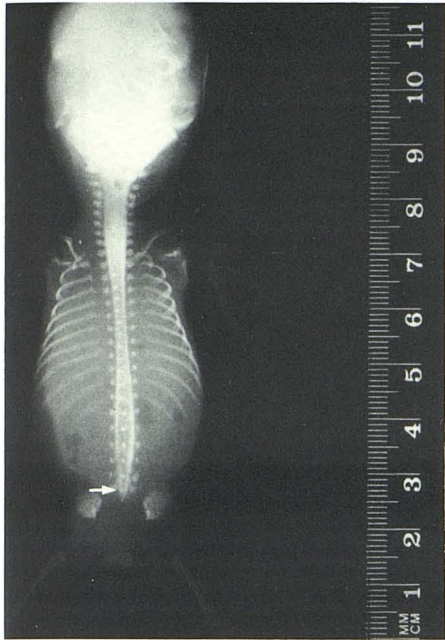


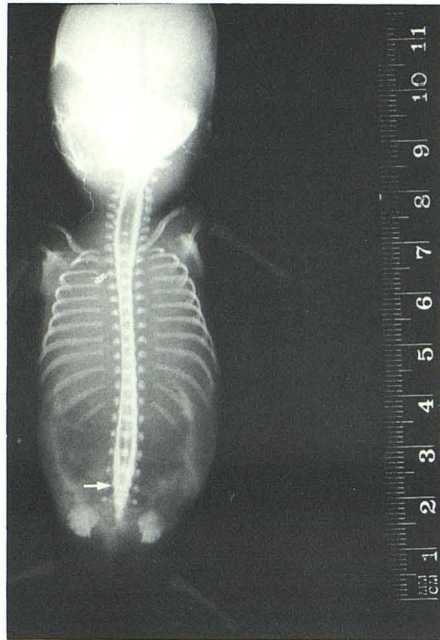
Fig. 2.—Myelograms of fetuses showing how the spinal cord terminates (arrows) at different ages. All photographs have been almost uniformly reduced by 30%; therefore, the relative size of the fetuses is preserved. Note demonstration of central canal in C, E, F, and G.

A, CRL = 2.2 cm; B, CRL = 3.3 cm; C, CRL = 7.8 cm; D, CRL = 9.7 cm; E, CRL = 11.7 cm; F, CRL = 13.9 cm; G, CRL = 16.4 cm; H, CRL = 22.8 cm. (See facing page.)

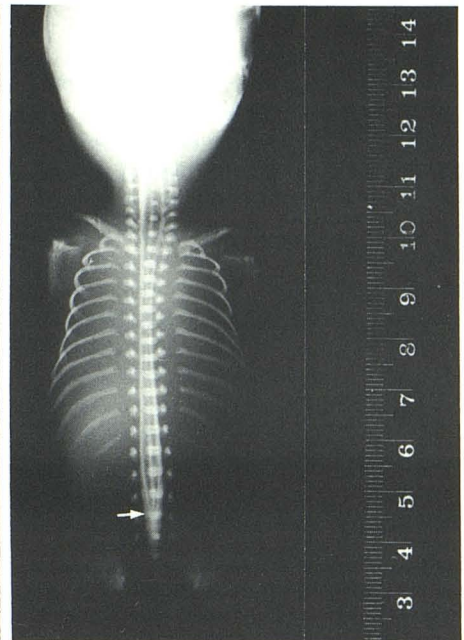




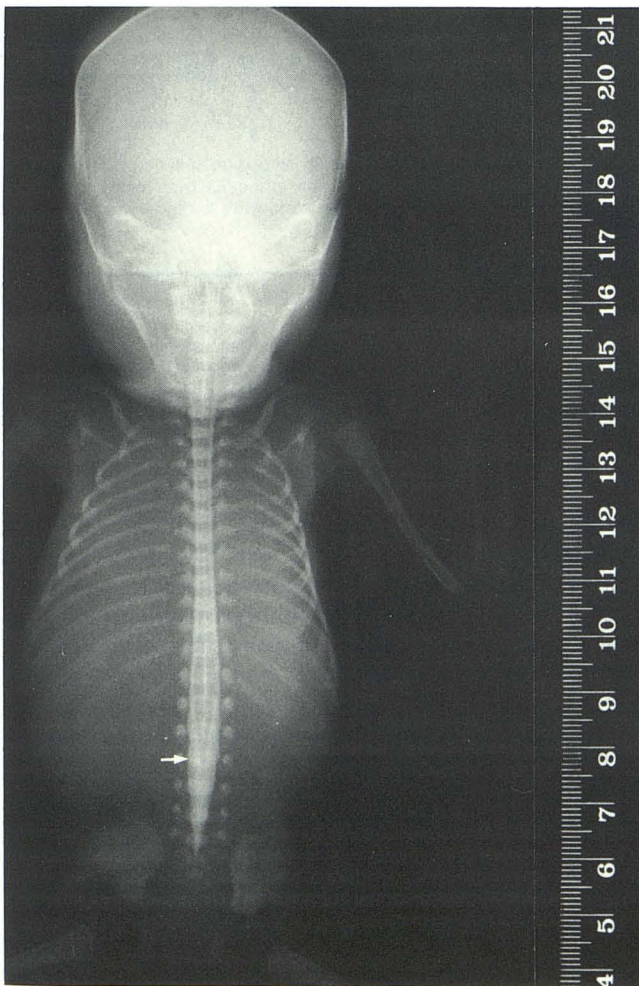
D



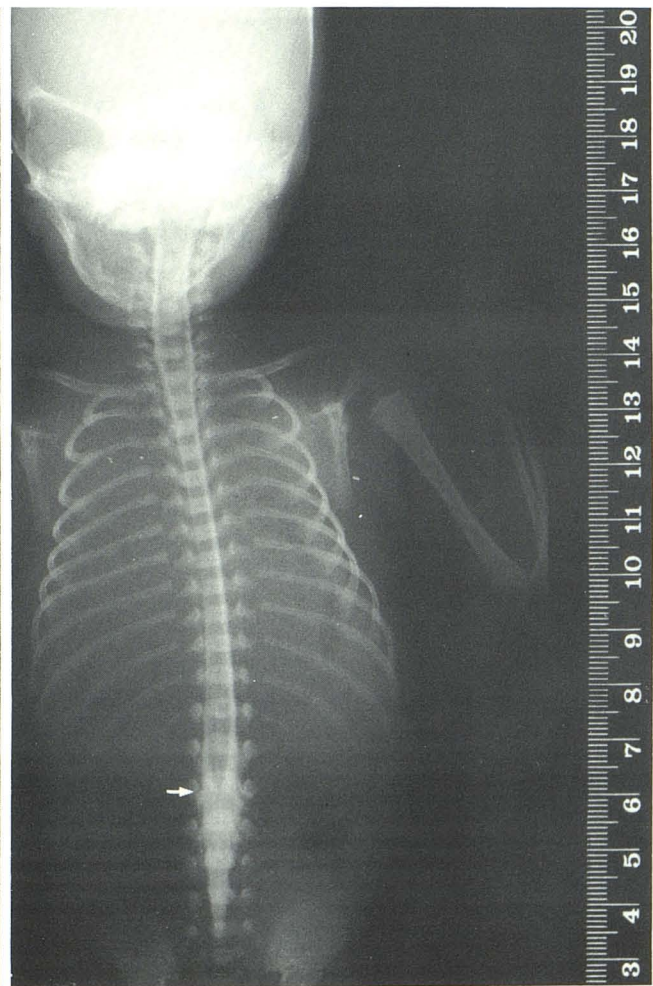E



F



G



H



## Results

Representative illustrations of the myelographic appearances of the spinal cord in fetuses of different ages are shown in Fig. 2. These figures confirm previous anatomic studies of spinal cord "ascent." However, when the level of the spinal cord termination was studied in 146 fetuses, it became evident that the tip of the conus medullaris was present at the level of the fifth sacral segment in fetuses having a gestational age of 7 weeks. In older fetuses, the cord was invariably shorter than the vertebral column, with significant variation in the level of the conus medullaris in fetuses aged 12 to 25 weeks. Between 25 and 33 weeks, the conus was situated at or above the level of the third lumbar vertebra. The range of anatomic variation of the conus level is illustrated in Figure 3. The relative length of the vertebral column to the length of the spinal cord is shown in Figure 4, and the exact difference in lengths of the vertebral column and spinal cord in each case against ages in weeks is shown in Figure 5.

## Discussion

We have illustrated in this study the feasibility of water-soluble contrast myelography in very small fetuses. This method is certainly the most reliable means for determining

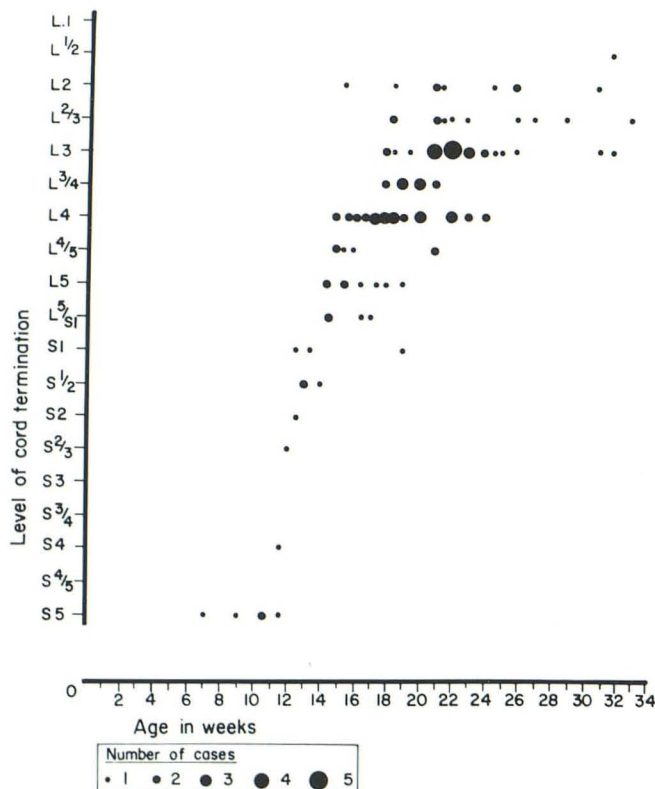


Fig. 3.—Level of spinal cord termination at different gestational ages in weeks. S = sacral; L = lumbar. Whole numbers (e.g., 1, 2, 3) refer to level of vertebral body. Fractions (e.g.,  $\frac{1}{2}$ ,  $\frac{2}{3}$ ,  $\frac{3}{4}$ ) refer to level between the two vertebrae.

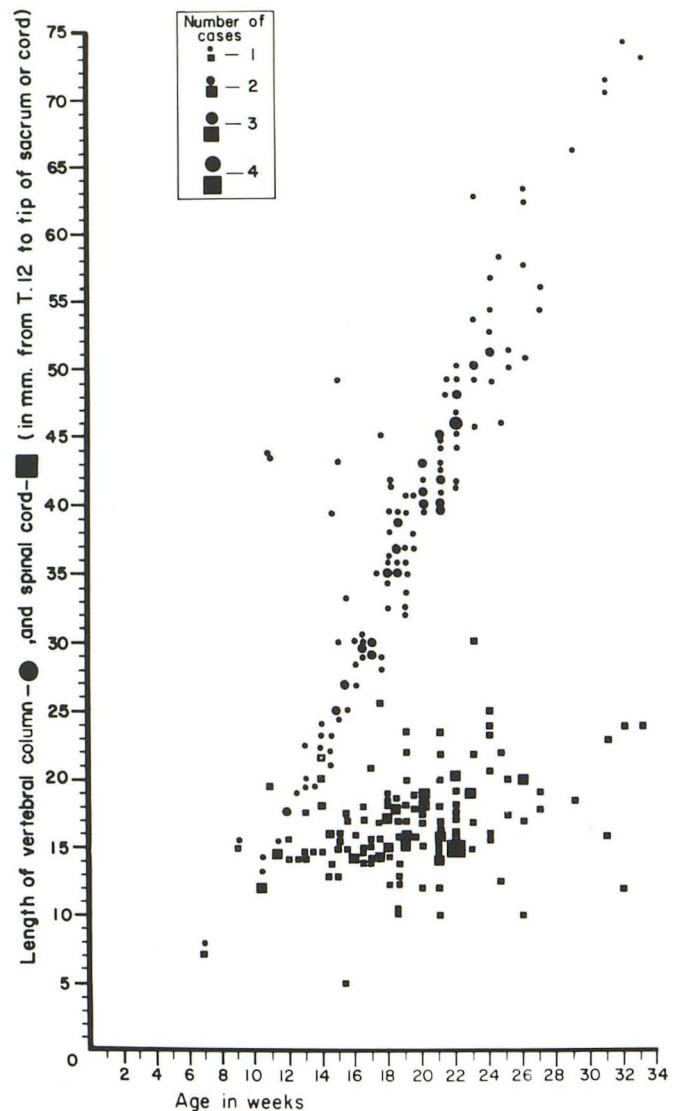


Fig. 4.—Relationships of length of vertebral column (as measured from interpedicular distance of T12 to tip of sacrum) to age and of corresponding length of spinal cord to age.

the spinal cord level in relation to the vertebral column. We have shown that the spinal cord ends at or above the third lumbar vertebra after 25 weeks gestational age. Between 12 and 25 weeks, however, there is significant variation in the level of the conus medullaris. This finding may have significant implication on future attempts for in utero diagnosis of spinal dysraphia using computed sonography and MR imaging. Of the various occult forms of spinal dysraphism, the diagnosis of the tethered cord syndrome in utero may prove to be unreliable before 25 weeks gestational age. Between 25 and 33 weeks, the spinal cord terminates at or above the level of the third lumbar vertebra. At the end of the second year the spinal cord terminates above the intervertebral disk space between the second and third lumbar vertebrae.

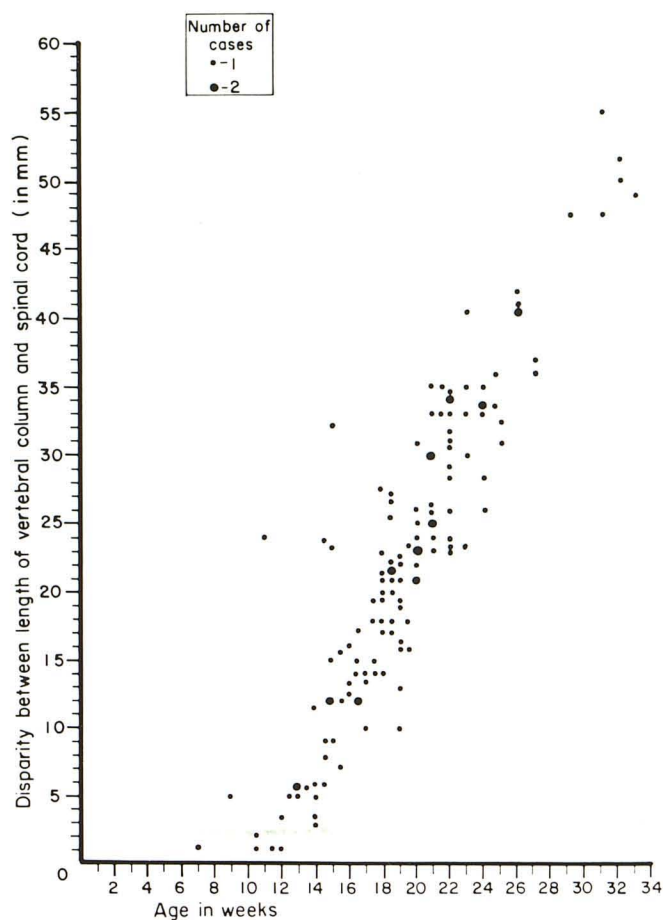


Fig. 5.—Relationship of age to disparity between length of vertebral column and spinal cord. Disparity was measured by subtracting length of spinal cord from length of vertebral column.

#### REFERENCES

1. Streeter GL. Factors involved in the formation of the filum terminale. *Am J Anat* 1919;25:1-11
2. Patten BM. *Human embryology*. New York: McGraw-Hill, 1976:205-207
3. Langman J. *Medical embryology*, 4th ed. Baltimore: Williams & Wilkins, 1981:324-330
4. Hamilton WH, Mossman HW. *Human embryology*. Baltimore: Williams & Wilkins, 1972:449-453
5. Potter ED, Craig JM. *Pathology of the fetus and the infant*. London: Lloyd-Luke, 1976:Ch. 2.