

# Generic Contrast Agents

Our portfolio is growing to serve you better. Now you have a *choice*.



FRESENIUS  
KABI

[VIEW CATALOG](#)

# AJNR

## Neuroimaging and the lesion of multiple sclerosis.

C M Poser, J Kleefield, G V O'Reilly and F Jolesz

*AJNR Am J Neuroradiol* 1987, 8 (3) 549-552

<http://www.ajnr.org/content/8/3/549>

This information is current as  
of May 27, 2025.



# Neuroimaging and the Lesion of Multiple Sclerosis

Charles M. Poser<sup>1</sup>  
Jonathan Kleefield<sup>2</sup>  
Gerald V. O'Reilly<sup>2</sup>  
Ferencz Jolesz<sup>3</sup>

In a patient with long-standing multiple sclerosis (MS), a double-dose delayed contrast-enhanced CT scan obtained during exacerbation revealed many areas of enhancement. Vigorous treatment with corticotrophic hormone was followed by almost complete disappearance of these abnormalities. No areas of low attenuation were seen on a later unenhanced CT scan. Finally, MR imaging showed only a single area compatible with a plaque of MS. It is suggested that pathologic alteration of the blood-brain barrier seen in MS is not necessarily followed by demyelination and plaque formation. Restoration of the integrity of the blood-brain barrier may thus possibly prevent the formation of plaques in some MS patients, in particular if this can be accomplished early in the course of the exacerbation.

The exact nature of the initial lesion of multiple sclerosis (MS) that causes plaque formation remains unknown, partly because the precise pathogenesis of MS is unknown. It has recently been proposed that a decisive and obligatory step in the evolution of MS requires an increase in blood-brain barrier (BBB) permeability [1]. The existence of such an alteration has been amply demonstrated by means of experimental work [2], radionuclide uptake [3], and contrast-enhanced CT [4]. This disintegrity of the BBB is transient and of unknown, but probably variable, duration. Serial studies with CT and MR imaging in MS may provide valuable information about the natural history of the MS lesion. Furthermore, some tentative hypotheses may be drawn regarding the effect of certain forms of therapy on this evolution.

## Case Report

A 26-year-old white woman had the first symptom of MS in May 1971 when her gait became unsteady. She also had diplopia, which lasted for a week, and developed stammering speech and severe clumsiness of the right hand. A neurologic examination revealed dysarthria; horizontal, vertical, and rotary nystagmus in all directions of gaze; severe dysmetria, tremor, and incoordination of the right hand; and hyperactive reflexes without pathologic responses. Examination of her cerebrospinal fluid (CSF) showed several abnormalities (Table 1). The diagnosis of MS was established, and she was treated with intramuscular adrenocorticotrophic hormone (ACTH) (Table 2) and was discharged definitely improved.

In December 1971 she was readmitted because of recurrent gait and speech difficulties as well as weakness of both hands and numbness of the perioral area. In addition to the previous abnormalities, she had developed left ankle clonus and a Babinski sign. She was treated with oral prednisone (Table 2), after which she remained asymptomatic for 8 years.

In 1980 her disease appeared to become progressive. She had numerous exacerbations including transient symptoms such as urinary incontinence, trunkal ataxia, diplopia, and visual loss as well as slow, steadily progressive spastic paraparesis. In 1981 and 1982 she received a series of treatments with oral prednisone (Table 2), with resulting symptomatic improvement. In May and September of 1983 she had relapses requiring hospitalization. Her neurologic examination showed a moderately severe spastic paraparesis, more marked on the left, generalized hyperreflexia, and bilateral Babinski signs. Her urinary frequency, urgency, and incontinence were particularly distressing. Her response to further treatment with prednisone was less dramatic.

Received September 19, 1986; accepted after revision December 16, 1986.

<sup>1</sup> Department of Neurology, Beth Israel Hospital, and Harvard Medical School, 330 Brookline Ave., Boston, MA 02215. Address reprint requests to C. M. Poser.

<sup>2</sup> Department of Radiology, Beth Israel Hospital, and Harvard Medical School, Boston, MA 02115.

<sup>3</sup> Department of Radiology, Brigham and Women's Hospital, and Harvard Medical School, Boston, MA 02115.

**AJNR 8:549-552, May/June 1987**

0195-6108/87/0803-0549

© American Society of Neuroradiology



**TABLE 1: Cerebrospinal Fluid Findings in Multiple Sclerosis**

Date	Leukocytes (% Lymphocytes)	TP (mg/dl)	Gamma Globulin (% TP)	IgG (% TP)	Oligoclonal Bands
6/6/71	8 (87)	38	17	...	...
6/10/71	18 (95)	46	19	...	...
7/28/71	2 (100)	50	12.5	...	...
12/27/72	1 (100)	32	11.5	...	...
1/10/84	62 (100)	110	...	36.1	...
1/28/84	27 (100)	87	...	25.7	0
6/4/84	20 (100)	83	...	34.7	0

Note.—TP = total protein; IgG = immunoglobulin G.

**TABLE 2: Treatment Regimens in Multiple Sclerosis**

Dates: Drug	Dosage
June 1971:	
Intramuscular ACTH	60 units for 10 days
Total	600 units over 10 days
Dec. 1971–Nov. 1983: <sup>a</sup>	
Oral prednisone	80 mg for 10 days 70 → 10 mg for 3 days each
Total	1640 over 31 days
Jan. 1984:	
IV ACTH	100 units for 1 day 80 units for 17 days 70 → 10 units for 1 day each
Total	1740 units over 25 days
June 1984:	
Oral prednisone	80 mg for 7 days 60 mg for 7 days 70 → 10 mg for 5 days each
Total	2380 mg over 49 days
Dec. 1984:	
IV cosyntropin	1 mg for 10 days
Total	10 mg over 10 days

Note.—ACTH = adrenocorticotrophic hormone; cosyntropin =  $\alpha^{1-24}$ -corticotropin (trade name, Cortrosyn).

<sup>a</sup> This treatment was administered in December 1971, April 1980, January 1981, July 1981, September 1981, December 1981, April 1982, June 1982, May 1983, September 1983, and November 1983.

In mid-December 1983, for about a week after her last course of oral prednisone, she had increasing difficulty walking as well as severely diminished speech production that made her unable to communicate verbally. A neurologic examination on admission in early January 1984 showed her to be alert and oriented with almost complete lack of spontaneous speech and no alterations of cognitive functions. The rest of the examination was essentially unchanged. CSF examination (Table 1) and a head CT scan with double-dose delayed IV administration of contrast material (Fig. 1A) revealed severe abnormalities. She received a course of IV ACTH (Table 2), and she improved dramatically. She had, however, complete amnesia for a period extending from 2 weeks before until 2 weeks after her admission.

Another double-dose delayed CT scan 1 week after termination of

ACTH treatment showed a considerable reduction in the number of enhancing areas (Fig. 1B), while the unenhanced CT scan showed no evidence whatsoever of low-attenuation lesions.

About 4 months later she had another exacerbation characterized by increasing leg weakness, diplopia, and hand clumsiness. Her CSF again showed lymphocytosis (Table 1), and a double-dose delayed CT scan showed several new enhancing lesions. She responded well to treatment with oral prednisone (Table 2). In December 1984 she was readmitted after 6 weeks of slowly progressive right arm and leg weakness. A double-dose delayed CT scan again showed some enhancing areas (Fig. 1C). This time she was treated with IV cosyntropin (Table 2), whereupon her new symptoms completely disappeared.

Since that time she has been followed on a regular basis, and, as of November 1986, her ability to live her daily life and involve herself in social activities had actually improved. An unenhanced CT scan in March 1985 showed no low-density lesions, but only some generalized ventricular enlargement (Fig. 1D). Finally, in December 1985, an MR scan using T2-weighting revealed only a single lesion in the left frontal area (Fig. 1E).

## Discussion

There is general agreement that areas of contrast enhancement demonstrated by CT represent sites of alteration of BBB impermeability [4, 5]. The evolution of such abnormalities is variable: Complete resolution repeatedly has been shown to occur in MS after the administration of corticosteroids and corticotrophic hormones, although some of these areas will also resolve spontaneously. Often loci of low attenuation on unenhanced CT will be found to correspond to areas that enhance, although many of them may disappear completely and result in isodense undetectable areas. Since the regions of low attenuation have the same characteristics as edema, it is quite likely that the low density is caused by the increased water content of the early plaque, with associated demyelination. It is also possible that many of these areas, in particular in chronic cases, represent the actual plaques of MS.

It is now known that MR reveals considerably more lesions than are visible on both enhanced and unenhanced CT scans.

The nature of the lesion visible on MR remains controversial. The increase in T2 relaxation time shown by spin-echo MR is believed to represent an increase in water content caused by edema. It is not clear whether or not actual demyelination contributes to changes in MR. Some investigators have stated that myelin-bound protons contribute relatively little to the MR signal for normal brain tissue and thus would not play an important role in changing the T2 relaxation time if myelin were destroyed [6]. Others think that a decrease in myelin lipids can result in increased signal intensity [7, 8]. Young et al. [9] believe that the increased water content in the MS lesion results from the destruction of hydrophobic myelin. Ormerod et al. [10] believe that myelin loss per se is unlikely to account for MR changes, but that altered signals are produced by a change in the atomic environment of water-based protons as a result of astrocytic proliferation.

These may be largely semantic considerations, since it is most likely that in the early plaque edema is always associated with demyelination, whereas later astrocytic gliosis becomes an integral part of it.



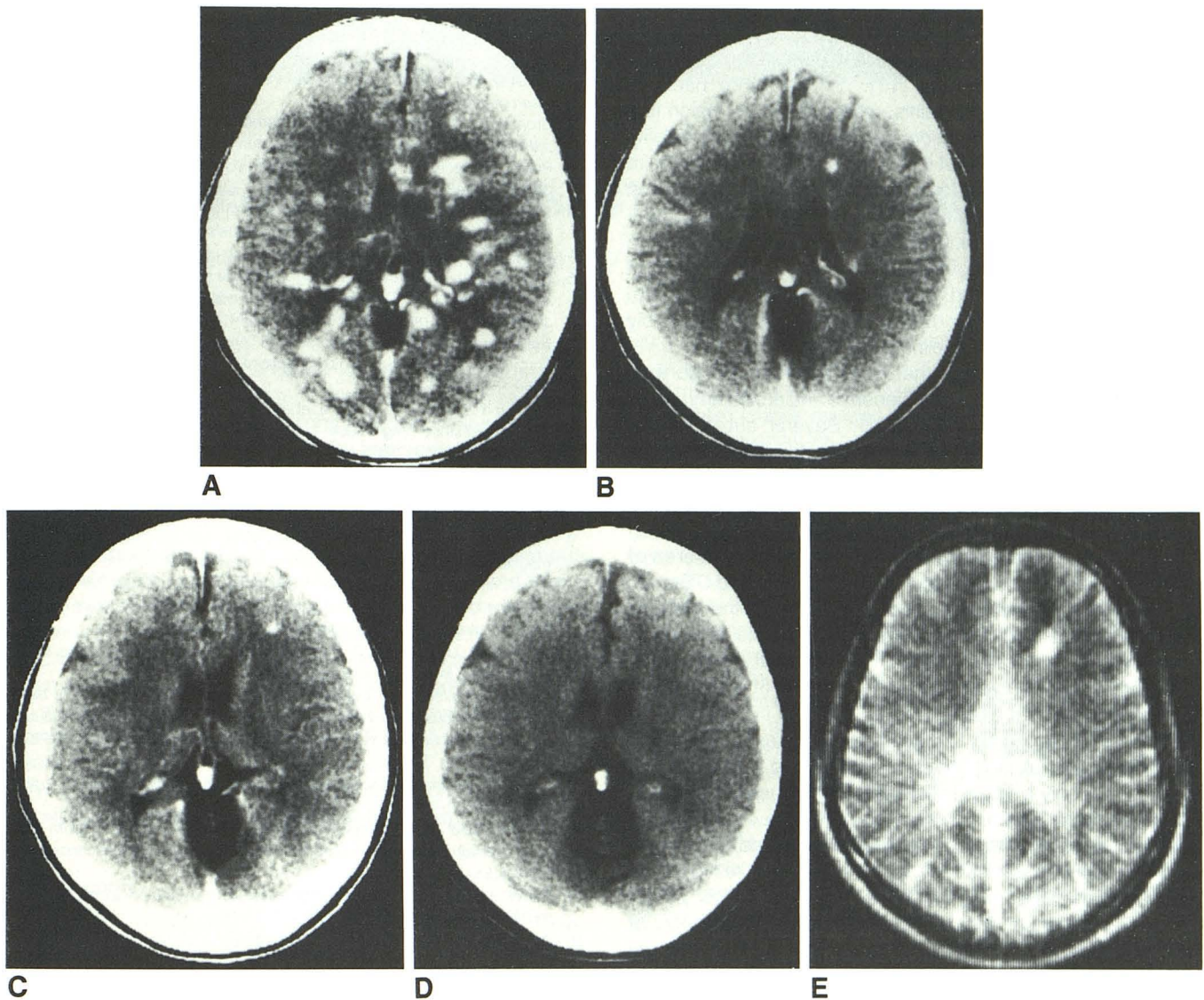


Fig. 1.—A, January 1984: CT scan with double-dose contrast enhancement (see text). Innumerable contrast-enhancing lesions in both cerebral hemispheres. Mild bilateral effacement of lateral ventricles.

B, 1 month later: double-dose contrast enhancement. Several white-matter enhancing lesions are still visible, but considerably fewer than before treatment. Mild, generalized brain atrophy.

C, December 1984: double-dose contrast enhancement. Two punctate

left-frontal-lobe white-matter enhancing lesions. Mild, generalized brain atrophy.

D, March 1985: unenhanced study. Generalized brain atrophy unchanged after 3 months.

E, MR image (spin-echo pulse sequence, repetition time = 1 sec, echo time = 203 msec) with T2-weighting. One area of prolonged T2 relaxation corresponds to more anterior of two left frontal lesions in C.

Experience to date strongly supports the hypothesis that the lesions visible by T2-weighted spin-echo MR represent actual lesions of MS, that is, plaques at various stages of development. This is indicated by the fact that serial MR studies in MS patients have shown shrinkage and better delineation of such lesions, suggesting the disappearance of edema and the consolidation and scarring of the demyelinated area by gliosis [11].

On the other hand, MR does not reflect the decrease in BBB impermeability that is shown by contrast-enhanced CT scanning. It is unlikely that the resolution of such contrast-enhancing areas represents remyelination, since such reso-

lution can occur in as little as 8 hr after the IV use of methylprednisolone [12]. It has also been demonstrated that some of the contrast-enhancing lesions are not visible by spin-echo MR performed shortly after CT scanning [5]. Therefore, it is worth considering the possibility that the alteration of BBB impermeability does not necessarily lead to demyelination and plaque formation in MS.

There has been only one published observation comparing contrast-enhanced CT with MR of the brain in MS. In that article many more lesions were shown by MR, and all the contrast-enhanced areas were represented by areas of increased signal intensity in MR [11].



As far as we know from a very limited number of studies, MR abnormalities have not been seen to disappear completely in MS, treated or untreated [11]. On the other hand, in postinfectious encephalomyelitis, where the initial lesion is a vasculopathy with inflammation and decreased impermeability of BBB, demyelination is not inevitable and may actually never occur [13]. In a series of four such cases in which follow-up MR scans were obtained after treatment with IV corticosteroids [14], complete resolution of all lesions was noted in two cases, whereas in the other two the size and number of abnormal areas decreased. This experience tends to confirm that the CT abnormalities represented edema and possibly inflammation, but not demyelination.

There is much evidence that corticosteroid and corticotropic hormones are not only antiedemic and antiinflammatory agents but also stabilize the BBB. Several authors have established that these medications will restore the integrity of the BBB [12, 15–17].

Therefore, our case is remarkable for several reasons: (1) there was a dramatic reduction in the number of contrast-enhancing areas after treatment with IV ACTH; (2) no area of decreased attenuation was seen on the unenhanced CT scan; (3) although the possibility exists that some of the plaques may have been isodense and therefore invisible, it is more likely that the restoration of BBB impermeability in so many areas prevented demyelination and formation of MS plaques; (4) after subsequent exacerbations, areas of increased BBB permeability reappeared and again were not associated with the formation of low-attenuation lesions; and (5) finally, MR showed that only a single lesion, that is, presumably a plaque of MS, could be found.

Vigorous treatment with corticosteroids and/or corticotropic hormone in this patient, which apparently restored the integrity of the BBB, may have prevented the further pathogenetic evolution of the MS process to its final stage of demyelination and plaque formation. This suggests that the initial lesion of MS, resulting from the alteration of the BBB, simply consists of edema and inflammation and that demyelination may not occur immediately or at all.

## REFERENCES

- Poser C. The pathogenesis of multiple sclerosis: a critical reappraisal. *Acta Neuropathol* **1986**;71:1–10
- Broman T. *The permeability of the cerebrospinal vessels in normal and pathological conditions*. Copenhagen: Munksgaard, **1949**
- Poser C. Recent advances in multiple sclerosis. *Med Clin North Am* **1974**;56:1343–1362
- Sears E, McCammon A, Bigelow B, Hayman L. Maximizing the harvest of contrast enhancing lesions in multiple sclerosis. *Neurology* **1982**;32:815–820
- Ebers G, Paty D, Sears E. Imaging in multiple sclerosis. In: Poser C, Paty D, Scheinberg L, McDonald W, Ebers G, eds. *The diagnosis of multiple sclerosis*. New York: Thieme-Stratton, **1984**:185–201
- Bottomley P, Hart H, Edelstein W, et al. Anatomy and metabolism of the normal human brain studied by magnetic resonance at 1.5 Tesla. *Radiology* **1984**;150:441–446
- Rumbach L, Caires M, Warter J, et al. Contribution a l'etude de l'imagerie par la resonance magnetique nucleaire du proton dans la sclerose en plaques. *Rev Neurol* **1985**;141:583–586
- Sears E. Nuclear magnetic resonance versus computerized tomographic enhancement imaging in multiple sclerosis: an apples and oranges comparison? *Ann Neurol* **1984**;15:309–310
- Young I, Randell C, Kaplan P, James A, Bydder G, Steiner R. Nuclear magnetic resonance imaging in white matter disease of the brain using spin echo sequences. *J Comput Assist Tomogr* **1984**;7:290–294
- Ormerod I, Roberts R, DuBoulay E, et al. NMR in multiple sclerosis and cerebral vascular disease. *Lancet* **1984**;2:1334–1335
- Johnson M, Li D, Bryant D, Payne J. Magnetic resonance imaging: serial observations in multiple sclerosis. *AJNR* **1984**;5:495–499
- Troiano R, Hafstein M, Ruderman M, Dowling P, Cook S. Effect of high-dose intravenous steroid administration on contrast-enhancing computed tomographic scan lesions in multiple sclerosis. *Ann Neurol* **1984**;15:257–263
- Poser C. Disseminated vasculomyelinopathy. *Acta Neurol Scand [Suppl]* **1969**;45[37]:1–44
- Dunn V, Bale J, Zimmerman R, Perdue Z, Bell W. MRI in children with post-infectious disseminated encephalomyelitis. *Magnetic Resonance Imag* **1986**;4:25–32
- Barrett L, Drayer B, Shin C. High resolution computed tomography in multiple sclerosis. *Ann Neurol* **1985**;17:33–38
- Poser C, Goutieres F, Carpentier M, Alcardi J. Schilder's myelinoclastic diffuse sclerosis. *Pediatrics* **1986**;77:107–112
- Sears E, Tindall S, Zarnow H. Active multiple sclerosis: enhancing computerized tomography imaging of lesions and the effect of corticosteroids. *Arch Neurol* **1978**;35:426–434