

Generic Contrast Agents

Our portfolio is growing to serve you better. Now you have a *choice*.



FRESENIUS
KABI

[VIEW CATALOG](#)

AJNR

Tapeworm cysts of the cauda equina.

A D Hyman, C E Gray, C Lanzieri and A S Belman

AJNR Am J Neuroradiol 1986, 7 (5) 977-978

<http://www.ajnr.org/content/7/5/977.citation>

This information is current as
of May 31, 2025.

REFERENCES

1. Manelfe C, Pasquine U, Banks WO. Metrizamide demonstration of the subarachnoid space surrounding the optic nerves. *J Comput Assist Tomogr* 1978;2:545-547
2. Haughton VM, Davis JP, Eldevik OP, Gager WE. Optic nerve sheath imaging with metrizamide. *Invest Radiol* 1978;13:544
3. Haughton VM, Davis JP, Harris GJ, Ho KC. Metrizamide optic nerve sheath opacification. *Invest Radiol* 1980;15(4):343-345
4. Davis JP, Haughton VM, Harris GJ, Eldevik OP, Gager WE. Cat optic nerve imaging with metrizamide. *Invest Ophthalmol Vis Sci* 1979;18:273-277
5. Fox AJ, Debrun G, Viñuela F, Assis L, Coates R. Intrathecal metrizamide enhancement of the optic nerve sheath. *J Comput Assist Tomogr* 1979;3:653-656
6. Tenner NS, Trokel SL. Demonstration of intraorbital portion of the optic nerves by pneumoencephalography. *Arch Ophthalmol* 1968;79:572-573

Tapeworm Cysts of the Cauda Equina

Cysticercus, coenurus, and echinococcus may affect the intracranial structures and spread to the spinal subarachnoid space via cerebrospinal fluid pathways [1, 2]. At myelography, tapeworm cysts in the spinal subarachnoid space may be difficult to distinguish from other causes of arachnoiditis and other intradural extramedullary processes, such as metastatic tumor implants. We recently encountered a case in which the mobility of the intradural masses allowed us to make the proper diagnosis.

Case Report

A 69-year-old female Peruvian immigrant was hospitalized for tonic-clonic movements of the upper extremities, lethargy, and transient loss of consciousness. One year before, she had developed sudden hemiparesis that resolved completely. Physical examination revealed nuchal rigidity, flaccid and severely paretic lower extremities, absent knee and ankle jerks, and extensor plantar reflexes bilaterally. The WBC was 12,200 cells/mm³ (71 neutrophils, 19 band forms, nine lymphocytes, one eosinophil). A lumbar puncture yielded opaque fluid at an opening pressure of 500 mm H₂O, containing 21,300 WBC/mm³, 0 mg% glucose, 600 mg% protein. No organisms were present. A lumbar myelogram showed multiple spherical filling defects ranging from several millimeters to approximately 2 cm in size in the dependent portion of the thecal sac while metrizamide was being injected under fluoroscopic control. As the patient was tilted to a 30° Trendelenburg position, several of these filling defects gravitated cephalad (Figs. 1A and 1B), and vice versa as the patient was returned to the erect position. At surgery the dura was thickened and approximately 10 to 12 clear yellow cysts up to 1.5 cm in size lay in the subarachnoid space among the nerve roots of the cauda equina, which were thickened and inflamed. Most cysts were free-floating but some were interconnected by thin branching stalks, forming grapelike clusters. All were easily extracted from the thecal sac by flushing the operative site with saline.

The cysts were identified as cysticerci or possibly coenuri, based on the presence of branching stalks and the absence of daughter vesicles within the cyst cavities. The absence of scoleces (larva "heads" with their distinctive arrays of hooklets and suckers) prevented a more precise diagnosis. A cerebral CT scan showed dilatation of all ventricles with no evidence of parenchymal mass or calcifications. The patient was treated with corticosteroids, diphenylhydantoin and helminthicide praziquantel; she became progressively more alert but did not regain the use of her lower limbs.

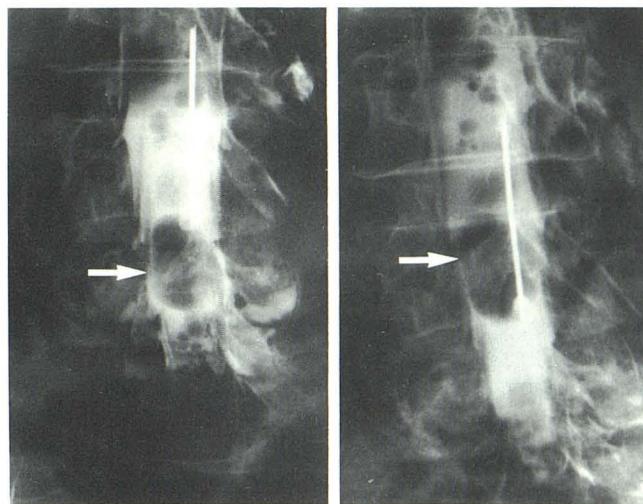


Fig. 1.—Metrizamide myelogram in semierect position (A). Multiple filling defects are seen in thecal sac including a 2-cm lesion at level of top of L5 vertebral body (arrow). In 30° Trendelenburg position, large cyst (arrow) gravitates to level of middle of L4 vertebral body (B).

Discussion

Many cases of tapeworm cysts of the CNS defy specific diagnosis because the cysts do not contain the characteristic scoleces at the time they are discovered [3]. Most reported cases of so-called "sterile" cysts have been attributed to cysticercosis on the basis of associated clinical or laboratory findings, such as soft-tissue calcification or infestation of the bowel by the adult tapeworm *Taenia solium*. Involvement of the spinal cord and its envelopes by tapeworm cysts is a rare condition in the United States.

The myelographic features of spinal subarachnoid cysticercosis are usually nonspecific and consist of single or multiple intradural filling defects caused by the cysts themselves, as well as irregularity of the dural sac contours and blunting of nerve roots sleeves because of associated leptomeningitis. The most commonly affected site is the high cervical region [4], presumably as a result of direct spread from posterior fossa cisterns where cysticercus cysts are often found. Cysts may settle in the caudal portion of the thecal sac and affect the nerve roots of the cauda equina.

Spherical filling defects from other causes of arachnoiditis or tumor implants are difficult to distinguish from tapeworm cysts, unless mobility of the latter can be demonstrated by positional variation. In our case several cysts showed rostrocaudal positional changes in response to tilting of the table, indicating that they were free-floating and able to gravitate within the cerebrospinal fluid of the thecal sac. This sign virtually excludes tumor and arachnoiditis as the cause of such filling defects and should be of help in diagnosing tapeworm-cyst disease in the proper clinical setting.

Alain D. Hyman
Cynthia E. Gray
Moutn Sinai Medical Center
New York, NY 10029

Charles Lanzieri
The Cleveland Clinic Foundation
Cleveland, OH 44106

Alexander S. Belman
South Nassau Community Hospital
Oceanside, NY 11572

REFERENCES

1. McCormick GG, Zee C-S, Heiden J. Cysticercosis cerebri: review of 127 cases. *Arch Neurol* **1982**;39:534-539
2. Bettaieb A, Khaldi, Ben Rhouma T, Touibi S. L'Echinococcose vertebro—medullaire a propos de 32 cas. *Neurochirurgie* **1978**;24:205-210
3. Proctor NSF. Tapeworm cyst infestation of the central nervous system: some observations. *Med Proc* May, **1964**;10:168-171
4. Rocca ED, Neira B. Cysticercosis of the rachis. *Int Surg* **1980**;65(1):31-35