



Discover Generics

Cost-Effective CT & MRI Contrast Agents



FRESENIUS
KABI

WATCH VIDEO

AJNR

Fatal brain edema after contrast-agent overdose.

L Junck and W H Marshall

AJNR Am J Neuroradiol 1986, 7 (3) 522-525

<http://www.ajnr.org/content/7/3/522.citation>

This information is current as
of June 24, 2025.

Fatal Brain Edema After Contrast-Agent Overdose

Larry Junck¹ and William H. Marshall²

Most cases of brain edema after arteriography are associated with focal brain infarction resulting from embolism or other vascular complications of the procedure. Rarely, brain edema not apparently a result of infarction has been reported as a complication of arteriography [1–4]. Available details of such cases are limited, but some authors have attributed the brain edema to a toxic effect of the contrast agent [1, 3]. We report a case in which a contrast-agent overdose at aortography led to high concentrations of contrast agent in the brain and resulted in fatal brain edema.

Case Report

An asymptomatic 7-year-old girl weighing 22 kg was found to be hypertensive at 140/90. A holosystolic murmur, loudest at the left scapular tip, an abdominal bruit, and absent lower extremity pulses were noted. A urinalysis was unremarkable.

At another hospital, aortography was performed via a left axillary approach under halothane anesthesia with endotracheal intubation. Each injection of diatrizoate meglumine sodium (Renografin-76) consisted of 68 ml, given at 17 ml/sec over 4 sec. Because the film changer failed during some of the series, five injections were made in less than 20 min. The total dose was 340 ml (15.5 ml/kg). Radiographs after at least one injection showed dense opacification of the brachiocephalic and carotid arteries. Aortic coarctation was demonstrated distal to the left subclavian artery. Immediately after

the fifth injection, the patient began having generalized seizures despite continued halothane administration. Status epilepticus failed to respond to 45 mg diazepam, 110 mg phenobarbital, and 100 mg phenytoin given intravenously. Her blood pressure initially remained stable at 130/80, but gradually rose to 180/120 3 hr later. She developed a supraventricular tachycardia of 225/min, which slowed to 160/min with intravenous propranolol without a fall in blood pressure. At 4 hr, arterial blood gas values, while she was on a respirator with supplemental oxygen, were pO₂ 309 torr (normal range on room air is 80–100), pCO₂ 85 torr (38–42), pH 7.04 (7.32–7.43), and HCO₃[−] 22 mEq/l (23–28). Sodium bicarbonate and pancuronium were administered, and subsequent blood gases were improved. At 5 hr, the temperature was 40.9°C, and cooling therapy was instituted. After 200 mg phenobarbital were given intravenously at 6 hr, only occasional, brief seizures were noted.

Upon transfer to Stanford University Hospital 10 hr after the procedure, the patient was deeply comatose. Her temperature was 38°C, blood pressure 110/80 (measured through a radial artery catheter), and heart rate 128. Retinal hemorrhages were noted. Normal brainstem reflexes were present. Muscle tone was markedly increased, and stimulation elicited decorticate posturing. Stretch reflexes were abnormally brisk. Hematocrit and platelet counts were normal. The results of other laboratory studies were WBC 16,400/mm³ (4,000–10,000), urea nitrogen (BUN) 22 mg/dl (8–20), creatinine 1.9 mg/dl (0.5–1.0), and uric acid >12 mg/dl (2.7–7.8). Bilirubin was 1.4 mg/dl (0.1–0.9) and SGOT, LDH, and alkaline phosphatase were elevated. Serum osmolality was 330 mosmoles/kg (269–298), while

TABLE 1: Hounsfield Numbers from CT Scan 22 Hours after Aortography

Brain Region	Values for This Patient (H) ^a	Reference Values (H) ^b	Enhancement (H) ^c	Calculated Iodine Concentration (mg/ml) ^d
Insular cortex	82 ± 6
Caudate nucleus	71 ± 5	39 ± 2	32	1.2
Thalamus	103 ± 6	38 ± 2	65	2.4
Centrum semivale	58 ± 4	32 ± 2	26	1.0
Corpus callosum	47 ± 6	30 ± 2	17	0.7
Lateral ventricle	19 ± 2	10 ^e	9	0.4

^a Mean ± standard deviation.

^b Values from gray and white matter regions are from measurements performed on a similar machine by Arimitsu et al. [5].

^c The value for ventricle is from Ramsey [6].

^d Normal contrast enhancement for most brain regions averages 1–2 H with the usual contrast agent dose [5].

^e Calculation is based on equivalency of 26 H to 1 mg/ml iodine [7].

Received December 28, 1984; accepted after revision August 6, 1985.

Dr. Junck is the recipient of Teacher-Investigator Development Award #1 KO7 NS00908-01 from the National Institutes of Health.

¹ Department of Neurology, University of Michigan Medical School, Ann Arbor, MI 48109. Address reprint requests to Larry Junck, Department of Neurology, 1914/0316 Taubman Center, University of Michigan Hospitals, Ann Arbor, MI 48109-0010.

² Department of Radiology, Stanford University School of Medicine, Stanford, CA 94305.

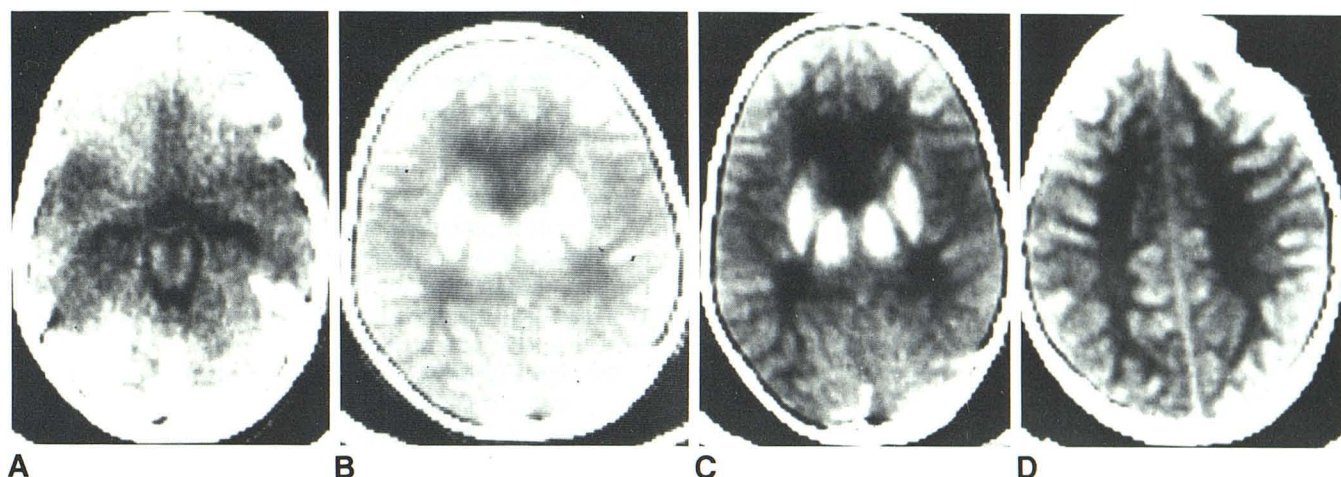


Fig. 1.—Postmortem CT scan performed approximately 48 hr after the administration of contrast material. The appearance is nearly identical to a scan made at 22 hr, but contains less artifact. A, Level 65 H, window 75 H; the circle of Willis and anterior, middle, and posterior cerebral arteries are filled with contrast medium. B, The level of central gray structures, displayed at the usual

viewing level of 40 H, window 75 H. Both gray and white matter are markedly enhanced by contrast material. C, The same cut as B, displayed at level 65 H, window 75 H. The greater degree of enhancement in gray matter is evident. D, A higher level displayed at level 65 H, window 75 H.

urine osmolality was 550 mosmol/kg (300–1300). Urine sodium was 75 mEq/L and potassium was 70 mEq/L, indicating possible renal tubular damage. Urinalysis revealed pH 8, +++ proteinuria, +++ hemoglobin, a few RBCs, and granular casts; no uric acid crystals were noted. Subsequently, total hemolytic complement (CH_{50}) was <200 units (800–1650 units), third component of complement ($C'3$) was 40 mg/dl (110–210), and fourth component of complement ($C'4$) was 3.2 mg/dl (11–75). She was treated with dexamethasone 10 mg every 6 hr.

At 22 hr, a CT scan without additional contrast-medium administration demonstrated contrast agent in the arteries at the base of the brain. Cerebral cortex, basal ganglia, and thalamus were markedly increased in density, consistent with retained intracerebral contrast agent. Hounsfield numbers for some brain regions are shown in Table 1. Bilateral nephrograms were noted on a chest X-ray. Electroencephalography (EEG) revealed a diffuse burst-suppression pattern, indicative of severe generalized encephalopathy.

The patient's blood pressure again rose to 134/105 (mean 116 torr), and sodium nitroprusside was administered. Her urine output had averaged 30 ml/hour through the 24th hr, but she was nearly anuric thereafter. An epidural pressure monitor was placed. Intracranial pressure was initially mildly elevated at 18 torr (normal \leq 15 torr) and remained stable near that level for several hours. At the 31st hr, ventricular tachycardia developed during Swan-Ganz catheter placement and responded to a precordial blow delivered within 1 min. Her mean arterial pressure remained low for several minutes at 50 torr, but rose after albumin infusion. The intracranial pressure steadily rose, and 33 hr after the procedure her pupils became unreactive. Her intracranial pressure remained elevated at 50–60 torr and did not respond to mannitol. Examinations after 33 hr were consistent with brain death, and an EEG was isoelectric. Respiratory support was discontinued 48 hr after the procedure. A postmortem CT scan demonstrated the continued presence of contrast agent in high concentrations (Fig. 1).

At autopsy, the brain weighed 1480 g (normal for age is approximately 1208–1265 g) [8]. The cerebrum and cerebellum were diffusely edematous, with enlargement and flattening of gyri, obliteration of sulci, and compression of the ventricles. The right uncus and

cerebellar tonsils were herniated. Subarachnoid hemorrhage overlaid the spinal cord, with a lesser amount of blood in the intracranial subarachnoid space. A 1-cm hemorrhagic infarct was noted in the right frontal cortex, and a few scattered petechial hemorrhages were present. Microscopic infarcts were noted in several regions. Ischemic change of neurons was present throughout the brain, perhaps reflecting changes after brain death. Alzheimer type-II glia were present, suggesting metabolic encephalopathy.

General autopsy revealed left ventricular hypertrophy, a bicuspid aortic valve, and a 2.5-mm coarctation of the descending aorta with a small recent thrombus adherent to the aortic wall distal to the coarctation. Tiny renal cortical infarcts were present bilaterally, and microscopy demonstrated coagulation necrosis of the proximal and distal tubules. Fibrin obstructed the afferent arterioles in both infarcted and uninfarcted areas. Eosinophilic and granular casts obstructed the proximal tubules in some areas. The distal collecting tubules appeared vacuolated. In the lungs, multiple microscopic fibrin emboli were found. The fibrin in the kidneys and lungs, the multiple small infarcts of the brain and kidneys, and the hemorrhages in the brain and subarachnoid space were interpreted as evidence of disseminated intravascular coagulation (DIC).

Multiple samples of brain and other tissues were obtained within 4 hr of death for iodine assay by fluorescence excitation. The results (shown in Table 2) indicate extremely high iodine concentrations throughout the brain as well as in all other tissues examined. The iodine concentrations measured postmortem in the brain agree reasonably well with iodine levels estimated from CT (see Table 1), considering that the sites sampled by the two methods were not identical.

Discussion

The doses administered to this 22-kg child were grossly excessive. The dose per injection and the total dose exceeded recommendations for aortography in adults [9, 10]. The 15.5 ml/kg total dose is similar to the median lethal dose (LD_{50}) of 10–20 ml/kg in most species for concentrated contrast agents [11].

TABLE 2: Postmortem Tissue Iodine Concentrations

Tissue	Iodine Concentration (mg/g or mg/ml) ^a
Body fluids	
Serum	8.75 ^b
Urine	21.75 ^b
Central nervous system ^c	
Frontal cortex	1.01
Frontal white matter	0.59
Lenticular nucleus	1.02
Thalamus	1.40
Hippocampus	0.40
Cerebellum	0.58
Pons	0.44
Medulla	0.21
Cervical spinal cord	0.31
Choroid plexus	0.44
Cerebrospinal fluid	1.08
Other tissues	
Kidney	4.69
Thyroid	2.14
Heart	0.61
Liver	0.63
Spleen	0.37
Stomach	0.85
Adrenal	0.77

^a Except for serum and urine, all samples were analyzed by fluorescence excitation by Dr. Michael Okerlund, University of California at San Francisco. Results are expressed as mg/g.

^b Urine was collected on the day after aortography, while serum was collected shortly before terminating care. These samples were analyzed by Bioscience Laboratories, Van Nuys, CA, by a chemical method employing catalysis of ceric acid reduction. Results are expressed as mg/ml. Normal serum iodine is approximately 0.0001 mg/ml.

^c Iodine concentration in a control brain sample was 0.00002 mg/g.

The neurologic complications in this patient were probably initiated by osmotic opening of the blood-brain barrier by the large volume of Renografin-76 delivered to the cerebral vasculature [12, 13]. Direct injection of concentrated contrast agents (>60%) including Renografin-76 into the carotid and vertebral arteries is contraindicated because of the increased risk of neurologic complications [9, 14]. Experimental studies indicate that osmotic opening of the blood-brain barrier may be accompanied by brain edema, apparently resulting from the flux of protein, electrolytes, and water across the abnormally permeable cerebral vessels into the extracellular space [13, 15]. The increase in cerebrovascular permeability may also account for the increase in the amount of contrast agent entering the brain, resulting in seizures. Contrast agents that have entered the brain are known to be epileptogenic [12, 16]. The seizures probably caused or contributed to further medical complications, including hypertension, respiratory and metabolic acidosis, and hyperthermia. Seizures, hypertension, hypercapnia, and hyperthermia have all been shown in experimental studies to increase cerebrovascular permeability [17-20]. It seems likely that these complications aggravated the blood-brain barrier opening, contributing to the extracellular brain edema as well as perhaps allowing the contrast agent even greater entry to the brain.

We postulate that a direct cytotoxic effect of the contrast agent also contributed to the patient's prolonged coma and caused progressive cellular (cytotoxic) brain edema. After 10 hr, the seizures, hypertension, hypercapnia, and hyperthermia

were all under good control, and serum osmolality was only moderately increased. Since the blood-brain barrier opening resulting from these conditions is transient, improvement in the brain edema and a decline in intracranial pressure would have been expected in the absence of the cytotoxic effect. The Alzheimer type-II glia noted at autopsy may be evidence of such a cytotoxic effect.

The brief hypotensive episode at the 31st hr (50 torr), in combination with the patient's increased intracranial pressure (20 torr), caused a brief decline in cerebral perfusion pressure. This may have resulted in sufficient brain ischemia to contribute to the terminal increase in intracranial pressure.

The high iodine levels demonstrated in our patient's brain on CT scan and at autopsy are presumed to represent intact diatrizoate ions, as metabolism of diatrizoate is minimal [21]. Studdard et al. [22] reported a patient in whom CT demonstrated high iodine levels in cerebral cortex as well as mild brain edema after aortography with a standard dose (Renografin-76, approximately 150 ml). That patient had seizures, cortical blindness, and mild renal failure but recovered fully. Junck et al. [23] reported a neonate with herpes simplex encephalitis who retained high concentrations of iodine in the brain (48-58 μ g/g) for as long as 25 days after contrast-agent administration for CT. The authors postulated that the contrast agent was bound to some structure or molecule to which it is not normally exposed.

Both DIC and complement activation have been reported after contrast-agent administration. Simon et al. [24] reported asymptomatic DIC, diagnosed by coagulation tests, in 41% of patients undergoing excretory urography. Batsakis [25] reported a case of fatal brain edema after cerebral arteriography with widespread brain petechiae, perhaps representing fulminant DIC. The pathologic findings on our patient suggest that DIC contributed to her neurologic complications. The decrease in complement levels CH₅₀, C'3, and C'4 in our patient is consistent with complement activation via the classic pathway; but activation has also been reported by the alternative pathway as well as by a third pathway [24, 26, 27].

Our patient's oliguric renal failure probably resulted from a combination of renal ischemia and tubular obstruction. She was well hydrated and had no risk factors for contrast-agent-induced renal failure [28]. Renal ischemia probably resulted from fibrin obstructing the renal arterioles together with the pressure drop across the coarctation. The eosinophilic material obstructing the tubules may have been Tamm-Horsfall protein, a normal kidney-derived mucoprotein that is precipitated by high concentrations of contrast agent [29, 30]. The tubular vacuolation probably represents "osmotic nephrosis," a benign histologic abnormality caused by contrast agents and other hypertonic substances, such as mannitol [31]. Despite our patient's elevated serum uric acid value (>12 mg/dl), we doubt that uric acid nephropathy contributed to her renal failure because her urinary alkalinity should have prevented uric acid crystallization and because intratubular uric acid crystals were not seen at autopsy.

Complications such as those seen in this case can be prevented by careful tabulation of administered dose and

adherence to recommended doses. However, should severe neurologic complications and severe renal failure occur after contrast-agent administration, we recommend prompt dialysis to clear remaining contrast agent from the body.

ACKNOWLEDGMENTS

The authors thank Thelma Jordan for typing the manuscript.

REFERENCES

- Abbott KH, Gay JR, Goodall RJ. Clinical complications of cerebral angiography. *J Neurosurg* **1952**;9:258-274
- Abrams HL. Radiologic aspects of operable heart disease. III. The hazards of retrograde thoracic aortography: a survey. *Radiology* **1957**;68:812-824
- Lalli AF. Contrast media reactions: data analysis and hypothesis. *Radiology* **1980**;134:1-12
- Pribram HFW. Complications of cerebral arteriography. In: Fields WS, Sahs AL, eds. *Intracranial aneurysms and subarachnoid hemorrhage*. Springfield: Thomas, **1965**:184-214
- Arimitsu T, Di Chiro G, Brooks RA, Smith PB. White-gray matter differentiation in computed tomography. *J Comput Assist Tomogr* **1977**;1(4):437-442
- Ramsey RG. *Neuroradiology with computed tomography*. Philadelphia: Saunders, **1981**;129
- Gado MH, Phelps ME, Coleman RE. An extravascular component of contrast enhancement in cranial computed tomography. *Radiology* **1975**;117:589-593
- Altman PL, Dittmer DS. *Growth including reproduction and morphological development*. Washington: Federation of American Societies for Experimental Biology, **1962**:346.
- Seaman WB, Buenger RE, Fischer HW, et al. *Prevention and management of adverse reactions to intravascular contrast media*. American College of Radiology, **1977**.
- Shehadi WH. Contrast media in diagnostic radiology: recommendations for labels, package inserts, and dosage determination. *AJR* **1977**;129:167-170
- Almen T. Lethal doses of radiocontrast agents in laboratory animals. In: Knoefel PK, ed. *International encyclopedia of pharmacology and therapeutics, Appendix III*. Oxford: Pergamon, **1971**:687-691
- Junck L, Marshall WH. Neurotoxicity of radiological contrast agents. *Ann Neurol* **1983**;13:469-484
- Rapoport SI, Thompson HK, Bidding JM. Equi-osmolal opening of the blood-brain barrier in the rabbit by different contrast media. *Acta Radiol [Diagn]* **1974**;15:21-32
- Kuramoto S, Watanabe M, Yoshimura K, et al. Complications in 1869 cerebral angiographies with Urografin. *Kurume Med J* **1967**;14:95-99
- Pappius HM, Savaki HE, Fieschi C, Rapoport SI, Sokoloff L. Osmotic opening of the blood-brain barrier and local cerebral glucose utilization. *Ann Neurol* **1979**;5:211-219
- Heimbürger RF, Kalsbeck JE, Campbell RL, Mealey J Jr. Positive contrast cerebral ventriculography using water-soluble media: clinical evaluation of 102 procedures using methylglumine iohthalamate 60%. *J Neurol Neurosurg Psychiatry* **1966**;29:281-290
- Cutler RWP, Barlow CF. The effect of hypercapnia on brain permeability to protein. *Arch Neurol* **1966**;14:54-63
- Johansson B, Li C-L, Olsson Y, Klatzo I. The effect of acute arterial hypertension on the blood-brain barrier to protein tracers. *Acta Neuropathol (Berl)* **1970**;16:117-124
- Lorenzo AV, Barlow CF, Roth LJ. Effect of Metrazol convulsions on ³⁵S entry into cat central nervous system. *Am J Physiol* **1967**;212(6):1277-1287
- Mueller SM. Increased blood-brain barrier permeability during hyperthermia in the awake rat. *Trans Am Neurol Assoc* **1979**;104:81-83
- Talner LB, Coel MN, Lang JH. Salivary secretion of iodine after urography; further evidence for in vitro deiodination and salivary secretion of contrast media. *Radiology* **1973**;106:263-268
- Studdard WE, Davis DO, Young SW. Cortical blindness after cerebral angiography. *J Neurosurg* **1981**;54:240-244
- Junck L, Enzmann DR, DeArmond SJ, Okerlund M. Prolonged brain retention of contrast agent in neonatal herpes simplex encephalitis. *Radiology* **1981**;140:123-126
- Simon RA, Schatz M, Stevenson DD, et al. Radiographic contrast media infusions. Measurement of histamine, complement, and fibrin split products and correlation with clinical parameters. *J Allergy Clin Immunol* **1979**;63(4):281-288
- Batsakis JG. Brain damage following Urokon injection in the brachial artery: report of a case. *Univ Mich Med Bull* **1957**;23:45-52
- Lasser EC, Slivka J, Lang JH, et al. Complement and coagulation: causative considerations in contrast catastrophes. *AJR* **1979**;132:171-176
- Neoh SH, Sage MR, Willis RB, Roberts-Thomson P, Bradley J. The in vitro activation of complement by radiologic contrast materials and its inhibition with epsilon-aminocaproic acid. *Invest Radiol* **1981**;16:152-158
- Byrd L, Sherman RL. Radiocontrast-induced acute renal failure: a clinical and pathophysiologic review. *Medicine (Baltimore)* **1979**;58:270-279
- Tamm I, Horsfall FL Jr. A mucoprotein derived from human urine which reacts with influenza, mumps, and Newcastle disease viruses. *J Exp Med* **1952**;95:71-97
- Berdon WE, Schwartz RH, Becker J, Baker DH. Tamm-Horsfall proteinuria. *Radiology* **1969**;92:714-722
- Moreau J-F, Droz D, Sabto J, et al. Osmotic nephrosis induced by water-soluble triiodinated contrast media in man. *Radiology* **1975**;115:329-336