



## Discover Generics

Cost-Effective CT & MRI Contrast Agents

 FRESENIUS  
KABI

[WATCH VIDEO](#)

# AJNR

## Delayed metrizamide CT enhancement of syringomyelia: postoperative observations.

S Kan, A J Fox and F Viñuela

*AJNR Am J Neuroradiol* 1985, 6 (4) 613-616

<http://www.ajnr.org/content/6/4/613>

This information is current as  
of June 2, 2025.

# Delayed Metrizamide CT Enhancement of Syringomyelia: Postoperative Observations

Shinichi Kan<sup>1,2</sup>  
Allan J. Fox<sup>1,3</sup>  
Fernando Viñuela<sup>1,3</sup>

Delayed metrizamide computed tomography (CT) was performed both preoperatively and postoperatively in 11 syringomyelia patients. Change of syrinx size between the studies was easily assessed on CT. The morphologic change of the syrinx gave useful information about its continuity. One of our cases had reoperation as a result of this CT information. All cases with Chiari I malformation still showed filling of the syrinx cavity by metrizamide after posterior fossa decompression and obex plugging. This supports the idea that the abnormal fluid circulation maintaining syringomyelic cavities is more than just the flow through the obex to the central canal but may also be from fluid passage through the cord substance.

Understanding the etiology of syringomyelia is still a controversial topic. The Gardner [1] theory explains syringomyelia as due to abnormal cerebrospinal fluid (CSF) circulation via an open obex between the fourth ventricle and the central canal of the spinal cord. It has been recognized, however, that there are instances where the obex cannot be the explanation for the pathogenesis of syringomyelia [2, 3], and this has led to the idea of "noncommunicating" forms of syringomyelia [4], in contradistinction to the "communicating" syringomyelia of Gardner.

Just as the specific causes of syringomyelia remain controversial, so does the surgical management. A variety of procedures exists [4] with variable results. We had the opportunity to study 11 patients with syringomyelia who had metrizamide myelography with delayed CT scans [5] both pre- and postoperatively. While the follow-up time did not allow for definitive long-term evaluation, the opportunity existed for a comparison between the short-term clinical and delayed CT findings. While the results of these studies are variable, they further support the idea that multiple factors are in existence in the maintenance of some syringomyelic cavities, including both an open obex and abnormal CSF flow through the cord substance.

Received August 29, 1984; accepted after revision November 26, 1984.

Presented at the annual meeting of the American Society of Neuroradiology, San Francisco, June 1983.

<sup>1</sup> Department of Diagnostic Radiology, University of Western Ontario, University Hospital, P.O. Box 5339, Station A, London, Ontario N6A 5A5, Canada. Address reprint requests to A. J. Fox.

<sup>2</sup> Present address: Department of Radiology, Kitasato University Hospital, Kanagawa-ken, Japan.

<sup>3</sup> Department of Clinical Neurological Sciences, University of Western Ontario, London, Ontario N6A 5A5, Canada.

**AJNR 6:613-616, July/August 1985**

0195-6108/85/0604-0613

© American Roentgen Ray Society

## Materials and Methods

The 11 patients reviewed all had surgical intervention for syringomyelia. Those with Chiari malformation in association with syringomyelia were subjected to foramen magnum decompression with plugging of the obex [4]. Those without Chiari malformation or with recurrence of symptoms after previous posterior fossa surgery had a direct drainage procedure to the syringomyelic cavity itself [5]. Delayed CT scans obtained after postoperative metrizamide myelography were reviewed in comparison with preoperative studies. Five mm slices were done every 2 cm from the foramen magnum to the sternal notch, and then every 3 cm to the conus. All cases had syrinx cavities involving both the cervical and thoracic cord. CT scans were obtained 6-12 hr after complete myelography [6]. The sizes of both the cavity and the spinal cord were compared on the respective examinations for each patient. A simple classification summarizing the overall clinical condition of the patients was used. Patients were grouped into three clinical categories: improved, unchanged, and worse. Patients were considered improved if there was decrease in the neurologic signs noted during the follow-up period. Postoperative CT studies were done 1-10 months after surgery, with the mean



TABLE 1: CT Findings at Follow-up after Surgery for Syringomyelia

Surgical Procedure: Case No., No. of Months to Follow-up	Cord Size				Syrinx Size				Clinical Status
	Cervical	Upper Thoracic	Middle Thoracic	Lower Thoracic	Cervical	Upper Thoracic	Middle Thoracic	Lower Thoracic	
Foramen magnum decompression and obex plugging:									
1, 5 . . . . .	Smaller	No change	No change	No change	No change	No change	No change	Not visible	Unchanged
1, 10 . . . . .	Inadequate	Inadequate	Inadequate	Inadequate	No change	No change	No change	Not visible	Unchanged
2, 2 . . . . .	Smaller	Smaller	No change	No change	Not visible	Not visible	Not visible	Larger	Improved
2, 5 . . . . .	Larger	Larger	No change	No change	Larger	Larger	Larger	No change	Unchanged
3, 2 . . . . .	No change	Inadequate	Inadequate	Inadequate	No change	Inadequate	Inadequate	Inadequate	Improved
4, 3 . . . . .	Smaller	Smaller	Smaller	No change	Smaller	Smaller	Smaller	No change	Improved
5, 4 . . . . .	No change	No change	No change	No change	No change	No change	No change	No change	Improved
Direct syrinx drainage:									
6, 2 . . . . .	No change	Smaller	Smaller	No change	No change	Smaller	Smaller	Not visible	Improved
7, 1 . . . . .	No change	Smaller	No change	No change	No change	Smaller	No change	Not visible	Unchanged
7, 3 . . . . .	Smaller	Inadequate	Smaller	No change	Smaller	Inadequate	Smaller	Not visible	Improved
7, 9 . . . . .	Inadequate	Inadequate	Inadequate	No change	No change	Inadequate	No change	Not visible	Unchanged
8, 4 . . . . .	No change	No change	No change	No change	No change	No change	No change	Not visible	Improved
8, 7 . . . . .	No change	No change	No change	No change	No change	No change	No change	Not visible	Unchanged
9, 10 . . . . .	No change	No change	No change	No change	No change	No change	No change	Not visible	Unchanged
10, 2 . . . . .	No change	No change	No change	No change	No change	No change	Smaller	Smaller	Unchanged
11, 1 . . . . .	No change	Inadequate	Inadequate	Inadequate	No change	Inadequate	Inadequate	Inadequate	Unchanged

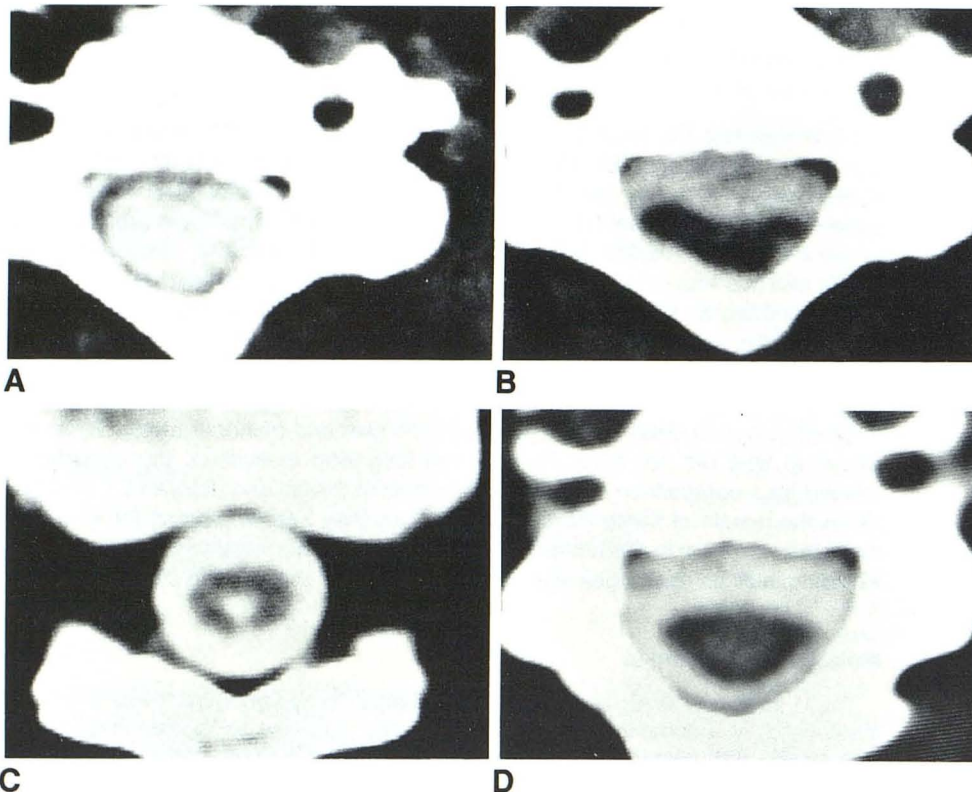


Fig. 1.—Case 2. Obex plugging. A, Preoperative metrizamide CT scan. Large syrinx in cervical cord. B, 2 months after obex plugging. Marked diminution of cervical cord and nonfilling of syrinx. C, Filling of syrinx cavity in lower thoracic cord. D, 5 months after surgery. Enlargement of cord and filling of syrinx cavity in cervical region.

follow-up time postoperatively being 4.5 months, and the studies were correlated with the clinical situation at follow-up.

## Results

The delayed CT scans for these postoperative cases have been categorized according to the type of surgical procedure performed [4]: foramen magnum decompression with plug-

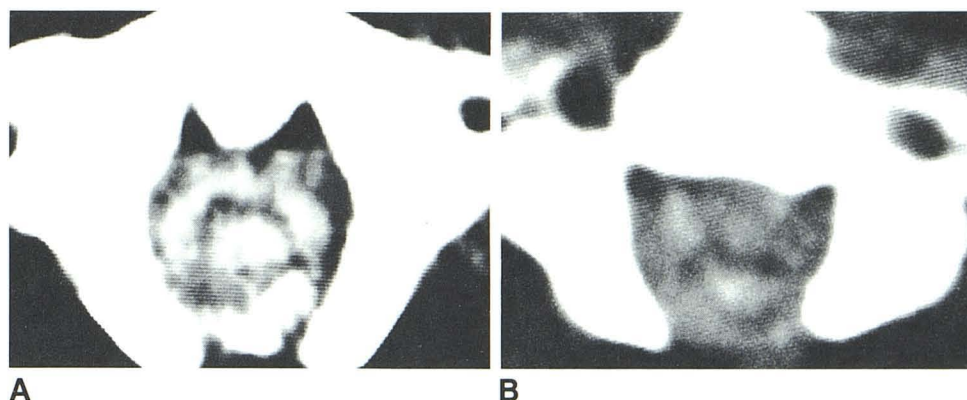
ging of the obex (when done as the only procedure) or direct drainage or shunting of the syrinx cavity.

## Foramen Magnum Decompression and Obex Plugging

In this group of five patients, three had postoperative follow-up by CT once and two had two follow-ups. The CT findings and clinical courses are shown as table 1. All these patients



Fig. 2.—Case 7. Syrxinx shunting. A, Initial metrizamide CT scan. Syrxinx cavity in cervical cord. After syrxinx drainage in thoracic region, cervical syrxinx cavity was unchanged on follow-up metrizamide study. B, After syrxinx drainage in cervical region. Reduction in cervical cord size and syrxinx cavity.



had Chiari I malformation. Improvement of the clinical signs and symptoms was noted in four of five cases. All of the five cases still showed filling of the cavities after obex plugging. Three of five cases showed reduction of the size of syrinx. In one of these cases (case 2), the first follow-up metrizamide CT scan showed marked reduction of the cervical cord size and nonfilling of the cavity at the cervical and midthoracic parts (figs. 1A and 1B). However, the syrinx cavity was demonstrated in the lower thoracic cord, where the preoperative CT scan had not shown the syrinx cavity (fig. 1C). A CT scan 5 months after surgery showed a large syrinx affecting the whole length of the thoracic and cervical cord and enlargement of the cervical cord (fig. 1D).

#### *Direct Drainage of Syrxinx*

In this group of six patients, four had one postoperative follow-up study, one had two follow-ups, and one had three studies.

The CT findings and clinical courses are shown as table 1. Reduction in size of the syrinx cavity was demonstrated in three cases. In case 7 there was reduction in the syrinx size in the upper thoracic region, which had been drained, but not in the cervical region (fig. 2A). From this CT finding, discontinuity of the cavity was presumed and another syrxinx drainage procedure was performed in the cervical region. After this procedure, reduction of the syrinx cavity in the cervical cord was noted (fig. 2B), and there was also further reduction of the size of the syrinx cavity in the midthoracic cord.

In both groups of patients, improvement of the clinical course, when seen, was noted whether the syrinx cavity became smaller or was unchanged on this CT evaluation. Clinical signs were unchanged in cases where the syrinx cavity became bigger, was unchanged, or became smaller. No case showed worsening of clinical signs after surgical treatment.

#### **Discussion**

Delayed metrizamide CT scanning has been an important diagnostic method for syringomyelia. This examination can also be done to evaluate surgical results for syringomyelia. Different surgical approaches are available [4, 7]. Most common has been obex plugging based on the hydrodynamic

theory that ventricular pulse waves travel down through the obex to the central canal and cause syringomyelia. Another is direct drainage or shunting of the syrinx cavity itself.

The clinical indications for follow-up myelography and CT in the cases reported here were twofold: (1) documentation of morphologic effects of surgery as a baseline for future comparison in patients who were initially improved and (2) guidance for further surgery in those who were clinically unchanged. This provided the opportunity to catalog the postoperative CT findings in this complex condition.

Postoperative delayed metrizamide CT scanning can provide useful morphologic information such as that in case 7 (fig. 2), where discontinuity of the syrinx cavity was suggested by the second CT study, and another surgical procedure was carried out.

Postoperative delayed metrizamide CT also gives some information regarding the maintenance of fluid in syrinx cavities. In our five patients with obex plugging, all cases still showed some filling of the syrinx cavity after surgery. This does not mean failure of the procedures since there was presumably change in fluid dynamics or pressure within the cavities (as suggested by the clinical improvement postoperatively in four cases). The persistence of filling is merely an anatomic observation. Three of five cases with obex plugging showed appreciable diminution of the syrinx cavity. One of them (case 2, fig. 1) demonstrated "disappearance" and subsequent "reappearance" of the cavity in the cervical region after obex plugging. For this kind of case, it is difficult to know whether the obex plugging was only temporarily successful or if a mechanism of filling of a cavity must be postulated other than direct filling from the fourth ventricle through the obex to cause the late increase of the cavity size. We suggest the latter, supported by the fact that, before surgery, the syrinx was demonstrated at all cord levels except for the lower thoracic region, which was then clearly demonstrated as the only visible syrinx at the time of the first postoperative study. The maintenance of a cavity in the lower thoracic region, without involvement higher up, is unlikely due to CSF coming down from the obex, but more likely through the cord substance.

We previously postulated direct filling of the syrinx cavity through the cord substance in noncommunicating syringomyelia, best exemplified in cases associated with tumor [8]. Pathologic study has demonstrated communication between a syrinx cavity and the subarachnoid space around the cord

via the Virchow-Robin spaces [2] for cases of so-called "non-communicating syringomyelia." This pathway along the perivascular spaces is also suggested as the mechanism of maintenance of fluid within syringes for patients with communicating syringomyelia after obex plugging, and it is likely that this "alternate" pathway preexisted the surgery. Williams [9] proposed a "slosh" mechanism to explain the progression of a syrinx cavity, that is, when excess fluid is present inside the cord, pulsation in the subarachnoid space may be transmitted to the fluid in the syrinx. This movement of fluid within a syrinx presumably can produce enlargement of a syrinx, and may do so in cases such as case 2 where later enlargement of the cavity occurred.

Delayed metrizamide CT can be useful as a postoperative study for syringomyelia, especially if the clinical outcome has been disappointing. From our cases with obex plugging, it is suggested that the initiating cause of some cases of syrinx and the maintenance of cavities may be different. That is, these cases suggest that abnormal CSF circulation via the obex is not the only mechanism maintaining some syringomyelic cavities, and abnormal passage of fluid through the cord substance may be included.

## REFERENCES

1. Gardner WJ. Hydrodynamic mechanism of syringomyelia: its relationship to myelocoele. *J Neurol Neurosurg Psychiatry* **1965**;28:247-259
2. Ball MJ, Dayan AD. Pathogenesis of syringomyelia. *Lancet* **1972**;2:799-801
3. Barnett HJM, Jousse AT, Wortzman GW. Four distinct varieties of the syringomyelic syndrome. *Trans Am Neurol Assoc* **1972**;97:171-174
4. Peerless SJ, Durward QJ. Management of syringomyelia . . . a pathophysiological approach. *Clin Neurosurg* **1983**;30:531-576
5. Aubin ML, Vignaud, J, Jardin C, Barr O. Computed tomography in 75 clinical cases of syringomyelia. *AJNR* **1981**;2:199-204
6. Fox AJ, Viñuela F, Debrun G. Complete myelography with metrizamide. *AJNR* **1981**;2:79-84.
7. Logue V, Edwards MR. Syringomyelia and its surgical treatment—an analysis of 75 patients. *J Neurol Neurosurg Psychiatry* **1981**;44:273-284
8. Kan S, Fox AJ, Viñuela F, Barnett HJM, Peerless SJ. Delayed CT metrizamide enhancement of syringomyelia secondary to tumor. *AJNR* **1983**;4:73-78.
9. Williams B. On the pathogenesis of syringomyelia: a review. *J R Soc Med* **1980**;73:798-806