



Discover Generics

Cost-Effective CT & MRI Contrast Agents



FRESENIUS
KABI

WATCH VIDEO

AJNR

Contrast Enhancement in CT Differentiation between Recurrent Disk Herniation and Postoperative Scar: Prospective Study

Ira F. Braun, James C. Hoffman, Jr., Patricia C. Davis, Jeffrey A. Landman and George T. Tindall

This information is current as of June 3, 2025.

AJNR Am J Neuroradiol 1985, 6 (4) 607-612
<http://www.ajnr.org/content/6/4/607>

Contrast Enhancement in CT Differentiation between Recurrent Disk Herniation and Postoperative Scar: Prospective Study

Ira F. Braun¹
James C. Hoffman, Jr.¹
Patricia C. Davis¹
Jeffrey A. Landman¹
George T. Tindall²

Recurrent disk herniation and postoperative scarring are among the major causes of recurrent symptoms after surgery for lumbar disk disease. The myelographic differentiation between these two etiologies is, at best, difficult. To evaluate the role of intravenous contrast enhancement and its impact on making this differentiation using computed tomography (CT), 98 postoperative symptomatic patients were studied prospectively with this technique. Twenty-two patients had subsequent reexploration (23 disk spaces). The unenhanced and enhanced studies of these patients were interpreted independently without surgical information. With contrast enhancement, only three CT studies were considered indeterminate, whereas 10 studies without contrast enhancement were indeterminate. The overall correct diagnosis with contrast enhancement was 17 (74%) of 23, while only 43% of the unenhanced studies yielded the correct diagnosis. Therefore, intravenous contrast enhancement significantly increased the diagnostic accuracy and level of confidence in making the differentiation between recurrent herniated disk and scar.

A significant number of patients will develop new or recurrent symptoms after surgery for lumbar disk disease. While these symptoms may have several causes, recurrent herniated nucleus pulposus (HNP) and postoperative scarring account for most cases. The clinical differentiation between these two entities is difficult, if not impossible [1]. In addition, it is well known that myelographic differentiation between recurrent HNP and scar is also unreliable [2-9]. The distinction between recurrent HNP and symptomatic scar is clinically important, as surgery is often advisable with recurrent HNP and conservative treatment is usually indicated in cases of postoperative scarring [10-14].

Despite numerous claims in the literature that this differentiation can usually be made using computed tomography (CT), there exists a paucity of surgically documented cases verifying these assertions [15-17]. Shubiger and Valavanis [18], in a retrospective study involving 36 patients, described the use of intravenous contrast-enhanced CT in making this differentiation. They found that in cases in which recurrent HNP was found surgically, no enhancement was seen, while in cases in which hypertrophic scar was found surgically, intraspinal contrast enhancement was perceived. More recently, Teplick and Haskin [19] used this technique in eight patients who had subsequent reexploration; the correct diagnosis was made in four of four cases of scar and in three of four with recurrent HNP.

In an attempt to objectively evaluate the utility and impact of intravenous contrast enhancement in the diagnosis of recurrent HNP versus scar, a prospective study was undertaken. Ninety-eight postoperative patients with recurrent symptoms thought clinically to be related to scar or HNP were studied with contrast-enhanced CT. Of these patients, 22 (23 levels) were subsequently reexplored. The unenhanced and enhanced CT scans of these patients were then interpreted in a blinded fashion, and these findings were compared with the surgical findings. This comparison provides the basis for our report.

This article appears in the July/August 1985 issue of *AJNR* and the October 1985 issue of *AJR*.

Received March 5, 1984; accepted after revision November 7, 1984.

¹ Department of Radiology, Section of Neuroradiology, Emory University School of Medicine, 1365 Clifton Rd., N.E., Atlanta, GA 30322. Address reprint requests to I. F. Braun.

² Department of Neurosurgery, Emory University School of Medicine, Atlanta, GA 30322.

AJNR 6:607-612, July/August 1985

0195-6108/85/0604-0607

© American Roentgen Ray Society

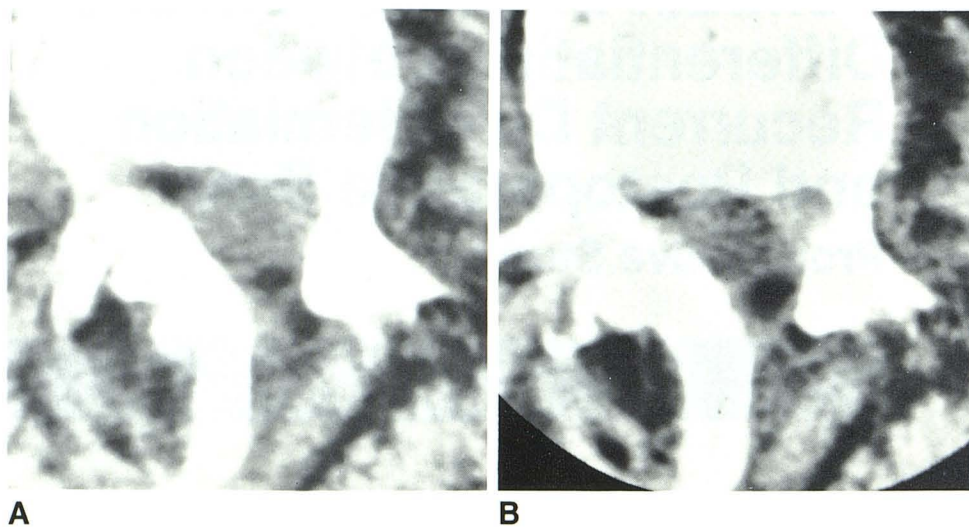


Fig. 1.—**A**, Precontrast CT scan. Density in left anterolateral aspect of canal. Reliable diagnosis of HNP vs. scar was not possible; therefore, this was called indeterminate. **B**, After enhancement. This region now enhances relatively homogeneously. Diagnosis of scar was corroborated at surgery.

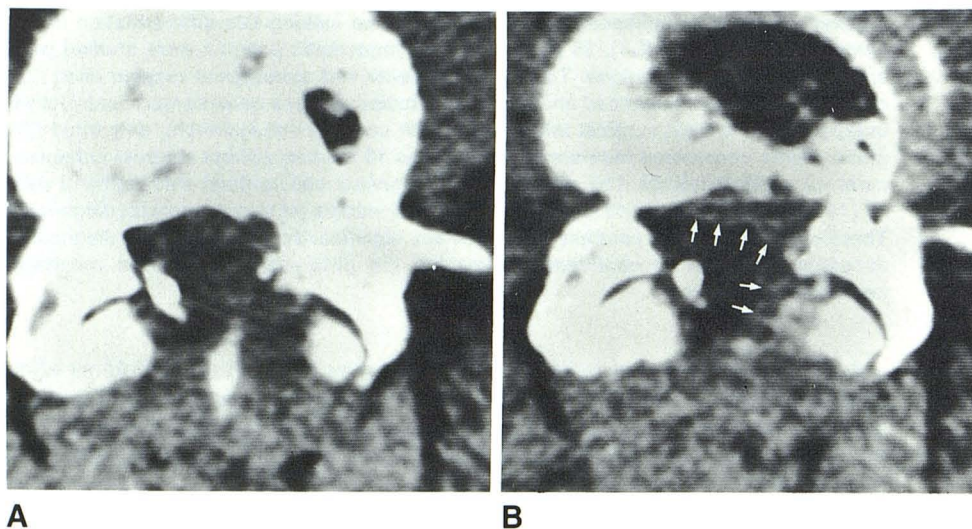


Fig. 2.—**A**, Precontrast CT scan. Relatively featureless canal with poor distinction of dural tube. Reliable diagnosis could not be made; study was considered indeterminate. **B**, After enhancement. Slight intraspinal enhancement (arrows) anteriorly and anterolaterally led to diagnosis of scar, which was confirmed surgically. Inhomogeneity of enhancement was considered consistent with relative "noise level" of entire image.

Subjects and Methods

CT was performed with and without contrast enhancement in 98 consecutive postoperative patients (from 6 weeks to 13 years after surgery) who had no sensitivity to contrast material. Unenhanced CT was performed through L3–L4, L4–L5, and L5–S1 in all patients using the angled gantry technique. Slices, either 5 mm (General Electric CT/T 8800) or 4 mm (Siemens DR-3) thick, were obtained from pedicle to pedicle with a 1 mm overlap. Contrast material was then administered using a bolus injection of 50 ml of MD-60 followed by a drip infusion of 300 ml of Conray-30 (Mallinckrodt) with only the level of previous surgery restudied.

Of these 98 patients, 23 levels were subsequently reexplored in 22 patients. The decision to reexplore was made primarily on clinical grounds. Most of the reexplorative surgery (17 of 22 patients) was performed by two neurosurgeons, thereby decreasing interobserver differences. Seventeen levels were noted to be involved with scar at surgery, while a recurrent HNP associated with scar was encountered at six levels. In all instances the inciting pathology was judged surgically to be primarily from either recurrent HNP or scar and not from a bony abnormality.

The unenhanced studies were interpreted separately in a blinded fashion by two experienced neuroradiologists (I. F. B. and J. C. H.) and were categorized into one of three diagnostic groups: (1) scar; (2) recurrent HNP; or (3) indeterminate. The criteria used for the diagnosis of scar on unenhanced CT scans included dural tube retraction and intraspinal soft-tissue accumulation with density greater than dural tube but less than disk, either within foramina or following the contour of the dural tube [20]. The criteria used for the diagnosis of recurrent HNP on unenhanced CT scans included mass effect caused by a soft-tissue density having an attenuation approximately similar to disk material and/or a focal mass related to the anulus. Studies were judged indeterminate for two reasons: (1) if the anterolateral border of the dural tube could not be separated visually from epidural soft tissue within the canal or (2) if a mass of soft-tissue density was perceived to be situated in the lateral recess or foramen, which, by virtue of its density or production of mass effect, was thought to have an equal likelihood of representing either disk or scar.

All 22 CT studies (23 levels) were then reevaluated in a blinded fashion by the same observers. This time the unenhanced and

Fig. 3.—**A**, Precontrast CT scan. Region of hyperdensity in lateral recess of canal on left. Definite diagnosis of HNP or scar could not be made; study was considered indeterminate. **B**, After enhancement. Lucency (arrowheads) within area of enhancement. Determination as to cause of finding could not be made (nerve root vs. fat vs. HNP); therefore, this also was considered indeterminate. Recurrent HNP imbedded in scar was found at surgery.

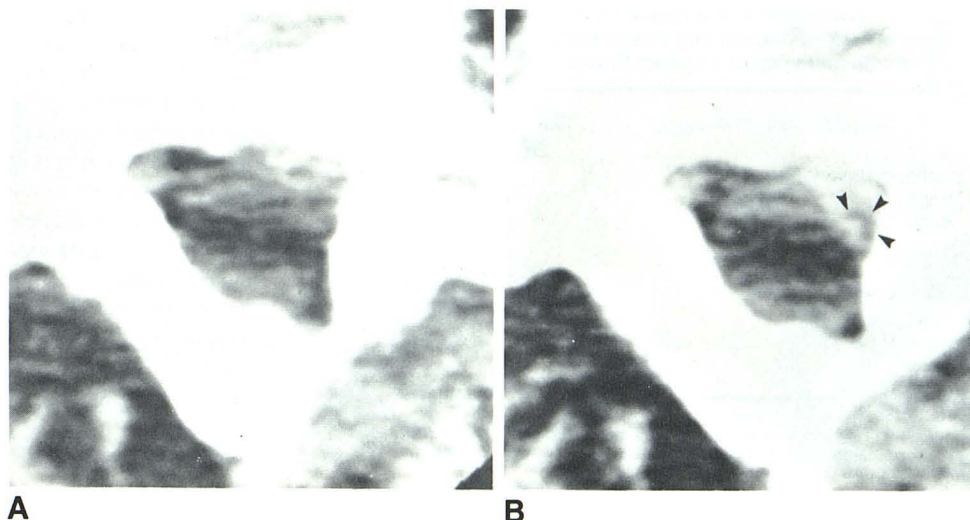
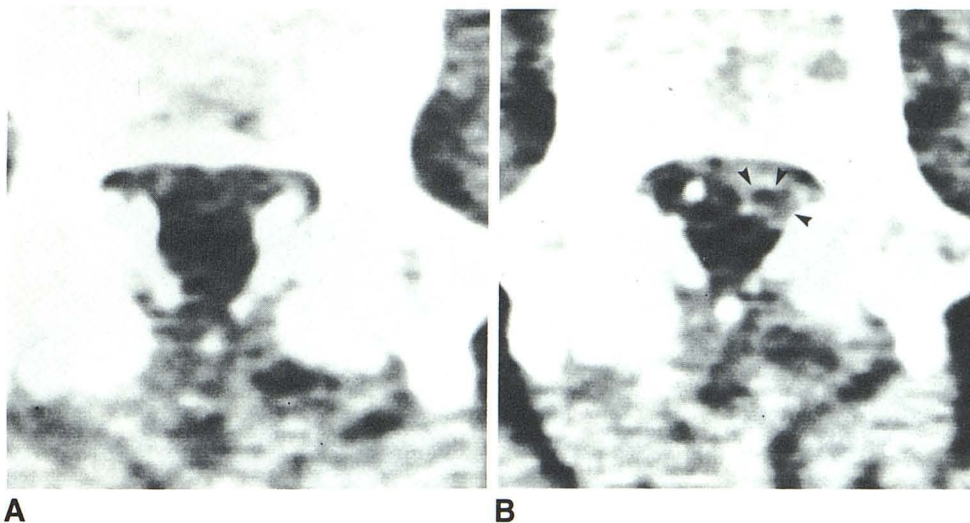


Fig. 4.—**A**, Precontrast CT scan. Relatively featureless canal without clear definition of dural tube was considered indeterminate. **B**, After enhancement. Fairly well circumscribed lucency (arrowheads) within region of enhancement in left anterolateral aspect of canal. For reasons similar to those in fig. 3B, this pattern was considered indeterminate. At surgery an HNP surrounded by scar was found.



enhanced CT scans were studied simultaneously and compared with each other to determine the effects, if any, of contrast administration. Again, cases were placed into one of the three categories mentioned above. Scar was diagnosed on contrast-enhanced scans if uniform enhancement of extradural soft tissue was seen. Enhancement around a nonenhancing circular structure adjacent to the foramen or lateral recess was considered to represent scar around a nerve root. HNP was diagnosed if a mass of nonenhancing soft tissue, which was believed not to represent nerve root, was seen either anterior, anterolateral, or lateral to the dural tube within the canal. Contrast-enhanced CT studies were considered *indeterminate* if a decision could not be made as to the cause of an area of relative lucency within an enhancing mass. Our diagnoses made on the basis of unenhanced studies alone and on the basis of unenhanced/enhanced studies combined were then compared with the operative findings to determine the effects of contrast enhancement on diagnostic accuracy.

Results

When CT was performed without contrast enhancement, the images from 10 of the 23 levels were judged to be

indeterminate, that is, a diagnosis of scar or HNP could not be made reliably with confidence using the criteria outlined previously (figs. 1A, 2A, 3A, and 4A). Of the other 13 levels, eight were surgically determined to have scar and five were found to have an HNP as the inciting pathology. Of the eight cases of scar, a correct diagnosis was made in five (the other three were called HNP). All five cases of surgically proven HNP were correctly called HNP on unenhanced CT, although three cases of scar were also judged to represent HNP (table I).

Of the same 23 levels evaluated on the basis of unenhanced and enhanced CT scans combined, three cases (figs. 3–5) were judged to be indeterminate. Of the other group of 20 levels, 13 of the 15 surgically documented levels involved with scar were correctly diagnosed as such. Of the seven cases of surgically proven HNP in this group, a correct diagnosis was made in four (figs. 6 and 7) using the combined studies. Of the 15 cases of surgically proven scar, 13 were correctly diagnosed (figs. 1 and 2). One case diagnosed as

TABLE 1: Radiologic and Surgical Differentiation between Recurrent Disk Herniation and Postoperative Scar in Patients Studied with and without Contrast Enhancement

Type of CT Study: CT Diagnosis	Surgical Findings	
	HNP	Scar
Unenhanced alone*:		
HNP	5	3
Scar	0	5
Total	5	8
Unenhanced + enhanced†:		
HNP	4	2
Scar	1	13
Total	5	15

Note.—HNP = herniated nucleus pulposus.

* Although 23 levels were studied, 10 were indeterminate as to scar or HNP. All five cases found to have HNP at surgery were correctly called HNP on CT, while five of eight cases of scar were correctly diagnosed as such.

† Although 23 levels were studied, three were indeterminate as to scar or HNP. Four of five cases of HNP were diagnosed correctly, while in 13 of 15 cases of scar a correct diagnosis was made.

scar turned out to be HNP, while two cases of surgically proven scar were called HNP on the basis of CT (table 1).

Because of our small number of patients, it is inappropriate to report statistics for accuracy, sensitivity, and specificity when unenhanced and enhanced CT studies are interpreted together; however, it is apparent that by using contrast material, our level of confidence in making a diagnosis has increased. This is reflected by a reduction in the number of studies judged to be indeterminate (from 10 to three) when the two studies are combined, while at the same time arriving at the correct diagnosis in 17 (74%) of 23 instances. This is compared with 43% when interpreting unenhanced studies separately if cases in the indeterminate category are considered incorrect diagnoses.

Discussion

The preoperative distinction between recurrent HNP and scar as the cause for symptoms in a patient with previous

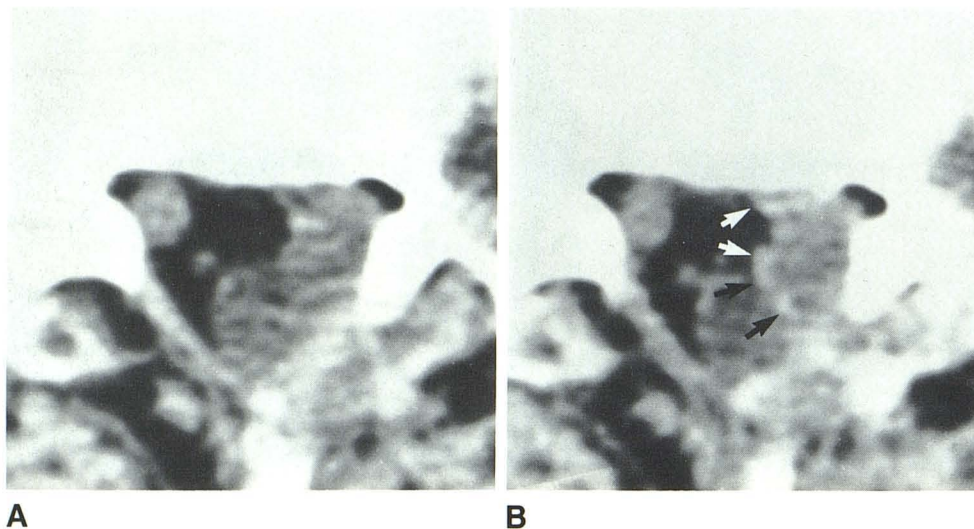


Fig. 5.—A, Precontrast CT scan. Mass of soft tissue in anterolateral aspect of canal abutting dural tube was believed to represent recurrent HNP. B, After enhancement. Well defined rim of circumferential enhancement (arrows) around mass. Since this lucency was believed to represent either swollen root or HNP surrounded by scar, study was judged indeterminate. At surgery an engorged root encased by scar was found.

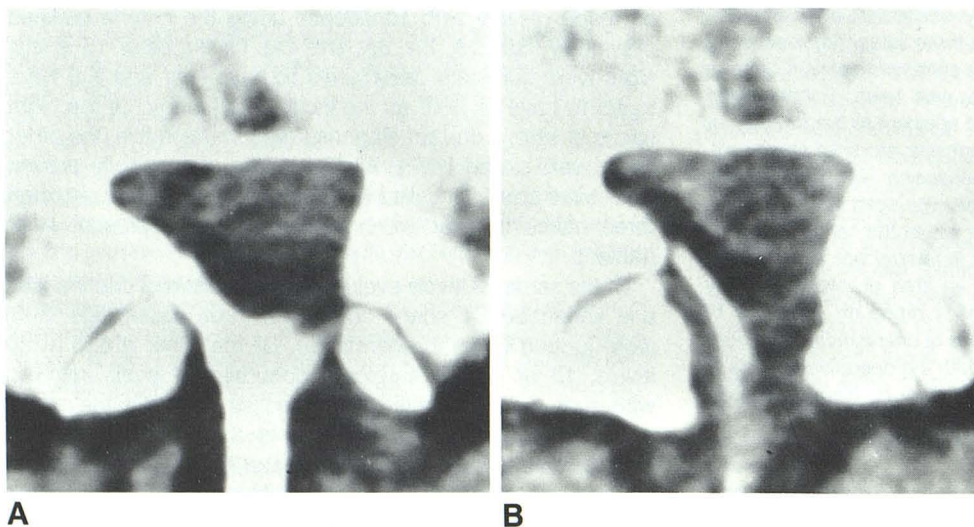


Fig. 6.—A, Precontrast CT scan. Mass of slightly hyperdense tissue in anterolateral aspect of canal was believed to represent HNP. B, After enhancement. Well defined rim of enhancement surrounding more lucent mass believed to represent scar surrounding an HNP was substantiated at surgery.

Fig. 7.—**A**, Precontrast CT scan. Mass of hyperdense soft tissue within right lateral recess extending to anterolateral aspect of canal was believed to represent HNP. **B**, After enhancement. Lack of significant enhancement raised our level of confidence in diagnosing HNP; this was substantiated at surgery.

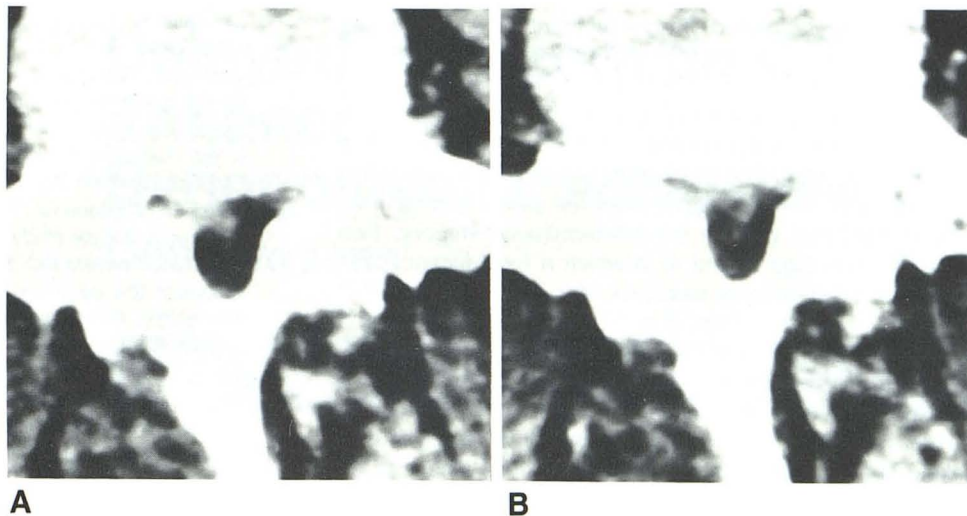
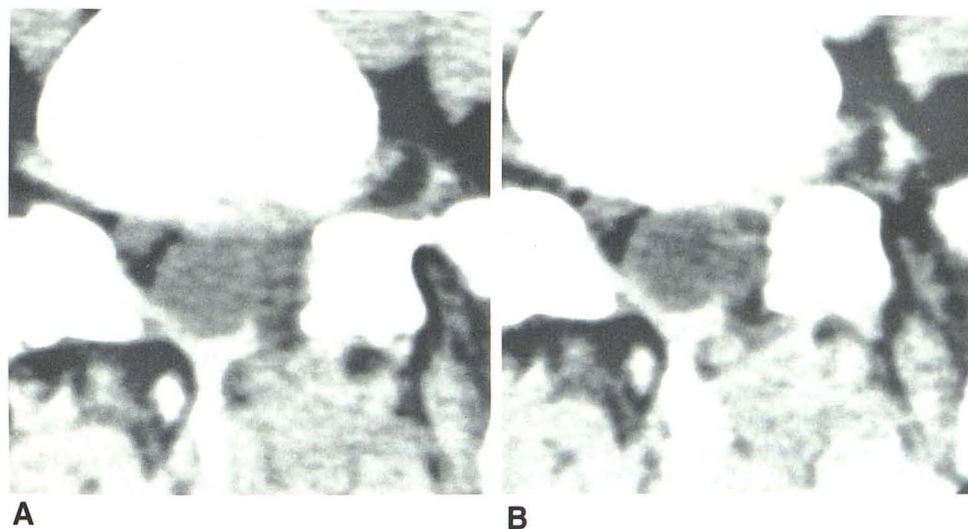


Fig. 8.—Pre- (**A**) and post- (**B**) contrast CT scans. Circumferential enhancement around well defined lucency in medial aspect of left intervertebral foramen was believed to represent root with surrounding scar; it was surgically corroborated.



surgery for lumbar disk disease is very important. In a study of 57 patients who were reexplored, Finnegan et al. [10] found that no patient with the postoperative diagnosis of fibrosis did well after reexploration, calling the operative results "dismal." They stated that "perhaps the most important implication of the results of this study is that the sternest test for the physician is the preoperative differentiation of patients who have a recurrent herniation of an intervertebral disk from those who have fibrosis from previous operations." [10]. Their feelings are echoed by Law et al. [12], who studied the results of reexploration in 53 patients and concluded that the finding of epidural scar was followed by a "bad" result in all but one case. Similar experiences and sentiments are voiced by other authors [11, 13, 14].

The results of our prospective study, which included blinded interpretations of 23 surgically verified levels, do not agree fully with other reported studies as to the ease with which the difference between recurrent HNP and scar can be made

using unenhanced CT [15–17]. For the most part, previous studies were performed without surgical verification. The discrepancy between our study and other studies is evident by the large number of levels (10 of 23) considered indeterminate. While we rely somewhat on visually perceived relative densities, we have found that the use of both absolute and relative density *measurements* is unreliable in distinguishing recurrent HNP from scar. In this regard, we agree with Helms et al. [21] that, while the use of relative density measurements may at times be helpful in the virgin spine, it is of no use in the postoperative study.

On contrast-enhanced CT scar could be diagnosed reliably when a smooth, homogeneous band of enhancing tissue encircled the dural tube either focally or throughout its full extent or if enhancing tissue was seen in the foramen or lateral recess (fig. 1). In this regard we concur with Teplick and Haskin [19]. If, however, an inhomogeneous enhancement pattern is seen with one or several focal lucencies,

closer scrutiny is advised. If enhancement around a circular lucency situated in the anterolateral aspect of the canal in or near the foramen or lateral recess was seen, then we were confident in calling this a root encircled by scar (fig. 8). A focal lucency or lucencies not related to the expected course of a root, however, should be much more suspect for representing disk fragments, which explains the three cases with contrast enhancement that were in the indeterminate category. Two of these cases (figs. 3 and 4) in which a focal lucency was seen within an enhancing mass proved to have recurrent HNP fragments at surgery. Thus, it is difficult for us to accept the conclusion of Teplick and Haskin [19] regarding this finding, whereby they stated that a lucency "should not be mistaken for disk or disk fragment within the enhanced scar" [19]. On the basis of our results, we urge the reader to be cautious in making such a diagnosis and to regard these lucencies as possibly representing disk fragments. Our third indeterminate case (fig. 5) after contrast enhancement involved a larger lucent mass within enhancing tissue that we believed could have represented either a swollen encased root (which it did) or an extruded fragment surrounded by scar.

We were, however, quite confident in making a diagnosis of HNP when a mass of unenhancing tissue surrounded by enhancement was seen situated anteriorly or anterolaterally in the canal related to the anulus, or alternatively when a mass of unenhancing soft tissue within the canal was seen distorting the dural tube (figs. 6 and 7). We suggest using contrast-enhanced CT even when a mass is seen indenting the dural tube on unenhanced CT so as to exclude a masslike scar, which should enhance.

On the basis of our limited series, we believe that contrast-enhanced CT increases the level of confidence and diagnostic accuracy when attempting to differentiate recurrent HNP from scar in the postoperative lumbar spine. However, larger prospective series from several institutions are necessary to define more fully the role of contrast-enhanced CT in making this differentiation.

ACKNOWLEDGMENTS

We thank Francine Hollowell for assistance in manuscript preparation and the CT technologists at Emory University Hospital for help in accumulating the data.

REFERENCES

1. Rothman RH. Lumbar disc disease—management of failures of lumbar disc surgery. In: Rothman RH, Simeone FA, eds. *The spine*. Philadelphia: Saunders, 1982:641
2. Knuttson F. The myelogram following operation for herniated disc. *Acta Radiol (Stockh)* 1949;32:60–65
3. Cronquist S. The post-operative myelogram. *Acta Radiol (Stockh)* 1959;52:45–51
4. Maltby GL, Predergrass RL. Pantopaque myelography: diagnostic errors and review of cases. *Radiology* 1946;47:35–46
5. Leader SA, Russell MJ. The value of Pantopaque myelography in the diagnosis of herniation of the nucleus pulposus in the lumbosacral spine. *AJR* 1953;69:231–241
6. Borelli FJ, Maglione AA. The importance of myelography in spinal pathology: analytic study of 150 cases. *AJR* 1956;76:273–289
7. Wright W, Sanders RC, Steel WM, O'Connor BT. Some observations in the value and techniques of myelography in lumbar disc lesions. *Clin Radiol* 1971;22:33–43
8. Shapiro R. *Myelography*, 3d ed. Chicago: Year Book Medical, 1975:203
9. Moseley I. The oil myelogram after operation for lumbar disc lesions. *Clin Radiol* 1977;28:267–276
10. Finnegan WJ, Fenlin JM, Marvel JP, Nardini RJ, Rothman RH. Results of surgical intervention in the symptomatic multiply operated back patient. *J Bone Joint Surg [Am]* 1979;61:1077–1081
11. Rothman RH. The operative treatment for lumbar disc disease. In: Rothman RH, Simeone FA, eds. *The spine*. Philadelphia: Saunders, 1982:601–629
12. Law JD, Lehman RAW, Kirsch WM. Reoperation after lumbar intervertebral disc surgery. *J Neurosurg* 1978;48:259–263
13. Hardy RW Jr. Repeat operation for lumbar disc. In: Hardy RW Jr, ed. *Seminars in neurological surgery—lumbar disc disease*. New York: Raven, 1982:193–202
14. Benoist M, Ficat C, Baraf P, Cauchoix J. Post-operative lumbar epiduro-archnoiditis—diagnostic and therapeutic aspects. *Spine* 1980;5:432–436
15. Mall JC, Kaiser JA. Computed tomography of the post-operative lumbar spine. In: Genant HK, Chafetz N, Helms CA, eds. *Computed tomography of the lumbar spine*. San Francisco: University of California, 1982:245–252
16. Teplick JG, Haskin ME. Computed tomography of the postoperative lumbar spine. *AJNR* 1983;4:1053–1072, *AJR* 1983;141:865–884
17. Teplick JG, Haskin ME. CT of the post-operative lumbar spine. *Radiol Clin North Am* 1983;21:395–420
18. Shubiger O, Valavanis A. CT differentiation between recurrent disc herniation and post-operative scar formation: the value of contrast enhancement. *Neuroradiology* 1982;22:251–254
19. Teplick JG, Haskin ME. Intravenous contrast-enhanced CT of the postoperative lumbar spine: improved identification of recurrent disc herniation, scar, arachnoiditis, and diskitis. *AJNR* 1984;5:373–383, *AJR* 1984;143:845–855
20. Braun IF, Lin JP, Benjamin MV, Kricheff II. Computed tomography of the lumbar spine in asymptomatic volunteers: an analysis of the physiologic scar. *AJNR* 1983;4:1213–1216, *AJR* 1984;142:149–152
21. Helms CA, Vogler JB, Wall SD. The utility of CT attenuation numbers in diagnosing lesions of the lumbar spine. Presented at the annual meeting of the Radiological Society of North America, Chicago, November 1983