



Discover Generics

Cost-Effective CT & MRI Contrast Agents



FRESENIUS
KABI

WATCH VIDEO

AJNR

Intraoperative Spinal Sonography in Thoracic and Lumbar Fractures: Evaluation of Harrington Rod Instrumentation

Robert M. Quencer, Berta M. Montalvo, Frank J. Eismont and Barth A. Green

This information is current as of June 3, 2025.

AJNR Am J Neuroradiol 1985, 6 (3) 353-359
<http://www.ajnr.org/content/6/3/353>

Intraoperative Spinal Sonography in Thoracic and Lumbar Fractures: Evaluation of Harrington Rod Instrumentation

Robert M. Quencer¹
Berta M. Montalvo¹
Frank J. Eismont²
Barth A. Green³

Thirty-seven patients with thoracic and lumbar spine fractures were treated with Harrington rod instrumentation (HRI), and the progress and results of that surgery were monitored with intraoperative spinal sonography (IOSS). Adequate neural tissue decompression and spinal column alignment was achieved in less than one-half (14/31, 45%) of the patients in whom HRI was performed as the first step of the surgical procedure. As a result of these findings, further surgical maneuvers were performed which, in most cases, resulted in adequate spinal realignment and neural tissue decompression. In six patients, direct surgical reduction of displaced bone fragments was performed before HRI. Since total decompression of neural tissue may be important in patients with spinal cord or cauda equina injuries, it is recommended that IOSS be used in all cases of HRI for thoracic and lumbar spine fractures. The need to perform additional surgical maneuvers to accomplish neural tissue decompression may be obviated if intraoperative sonography shows adequate decompression with HRI alone.

Harrington rod instrumentation (HRI) and spinal fusion in the treatment of fractures and fracture/dislocations of the thoracic and lumbar spine is performed in order to stabilize the spine and to eliminate bone impingement on adjacent neural structures. Until recently, intraoperative assessment of the effects of Harrington rod distraction on vertebral malalignment and compression of the spinal canal and its contents has been possible only with intraoperative myelography or plain radiographs taken during the surgical procedure. Direct visualization of the offending bone fragments is not possible without some resection of the posterior elements, since the fragments lie anterior to the thecal sac. We have found, however, that with intraoperative spinal sonography (IOSS) the efficacy of HRI can now be immediately and accurately assessed. If spinal decompression is shown to be inadequate and significant malalignment persists, further corrective surgical steps can then be taken.

We report the results of IOSS in 37 patients with unstable thoracic and lumbar fractures who underwent HRI. We demonstrate the importance of IOSS in monitoring this type of surgery and show how it aids in the surgical management of these patients.

Subjects and Methods

The diagnosis of a thoracic or lumbar spine fracture was established on the basis of plain radiographs in all 37 patients. Spine CT scans were obtained in 35 of the patients. When fractures occurred at more than one contiguous level, we designated the level of fracture as that level at which the major malalignment and canal compression occurred. All patients were candidates for Harrington rod distraction because the fractures were considered unstable and/or because of the presence of a bone fragment that had been retropulsed into the spinal canal.

IOSS, with instrumentation and techniques previously described [1], was used in all 37 cases. After a laminotomy at the injury site, baseline IOSS at that level was performed before

This article appears in the May/June 1985 issue of *AJNR* and the August 1985 issue of *AJR*.

Received July 18, 1984; accepted September 30, 1984.

Presented at the annual meeting of the American Society of Neuroradiology, Boston, June 1984.

¹ Department of Radiology, R 130, University of Miami School of Medicine, Jackson Memorial Medical Center, P.O. Box 016960, Miami, FL 33101. Address reprint requests to R. M. Quencer.

² Department of Orthopaedic Surgery and Rehabilitation, University of Miami School of Medicine, Jackson Memorial Medical Center, Miami, FL 33101.

³ Department of Neurological Surgery, University of Miami School of Medicine, Jackson Memorial Medical Center, Miami, FL 33101.

AJNR 6:353-359, May/June 1985
0195-6108/85/0603-0353
© American Roentgen Ray Society

TABLE 1: Results of Harrington Rod Instrumentation

	No. of Patients
Initial Harrington rod instrumentation, adequate decompression	14
Initial Harrington rod instrumentation, inadequate decompression	17
Subsequent procedures resulting in adequate decompression	11
Increased Harrington rod distraction	1
Bone fragment removal	4
Bone fragment impaction	3
Bone fragment impaction and increased Harrington rod distraction	3
Subsequent procedures resulting in inadequate decompression	4
Bone fragment impaction, but nothing further done because:	
Patient neurologically intact	2
Fragment could not be reduced	1
Increased Harrington distraction, but nothing further done because:	
Patient neurologically intact	1
But nothing further done because patient neurologically intact	2
Bone fragments removed or impacted before bilateral Harrington rod instrumentation	6
Harrington rod instrumentation, adequate decompression	5
Harrington rod instrumentation, inadequate decompression	1
Further bone fragment impaction, adequate decompression	1

HRI in 35 of the 37 cases. The size of the laminotomy needed to give a window for adequate sonography varied, but about 1.0×1.5 cm was the minimal size required. Because the amount of bone thus removed is minimal and because the associated ligaments have already been torn or injured, the laminotomy does not increase spinal instability. In the two cases where baseline sonograms were not obtained, Harrington rods were already in place when the sonographic equipment arrived in the operating room. Sonography was performed after each additional surgical maneuver, whether that maneuver was Harrington rod instrumentation, bone fragment removal/impaction, or increased Harrington rod distraction. At each stage of surgery, the sonogram was evaluated for vertebral alignment and compression of the spinal cord, nerve roots, or thecal sac. The use of sonography did not significantly prolong these surgical procedures.

Spinal decompression was considered adequate when there were no residual bone fragments or soft-tissue elements causing deviation of the spinal cord or displacement of the nerve roots of the cauda equina from their normal course. The visualization of CSF around the entire cord or cauda equina and the restoration of the canal to a normal or near-normal configuration were additional signs indicating adequate decompression. Decisions on whether to attempt additional surgical maneuvers were based mainly on these sonographic criteria but also depended on the patients' preoperative neurologic status.

Our case material was divided into three major categories: (1) patients in whom the original HRI adequately decompressed the canal, (2) patients in whom the original HRI failed to adequately decompress the canal, and (3) patients who had bone fragments removed or impacted before HRI (table 1).

Additional surgical procedures were performed in those patients whose canals had been inadequately decompressed by the Harrington rods, and the subsequent sonograms were analyzed in a manner

TABLE 2: Level and Incidence of Fracture

Level	No. of Patients
T4	1
T7	1
T10	2
T11	2
T12	9
L1	12
L2	4
L3	4
L4	2
Total	37

similar to that described above. Using these data, we were then able to determine the percentage of cases in which the routine application of Harrington rods resulted in either adequate or inadequate spine decompression and to show how IOSS influenced further surgical management when the initial Harrington rod placement inadequately decompressed the canal.

Results

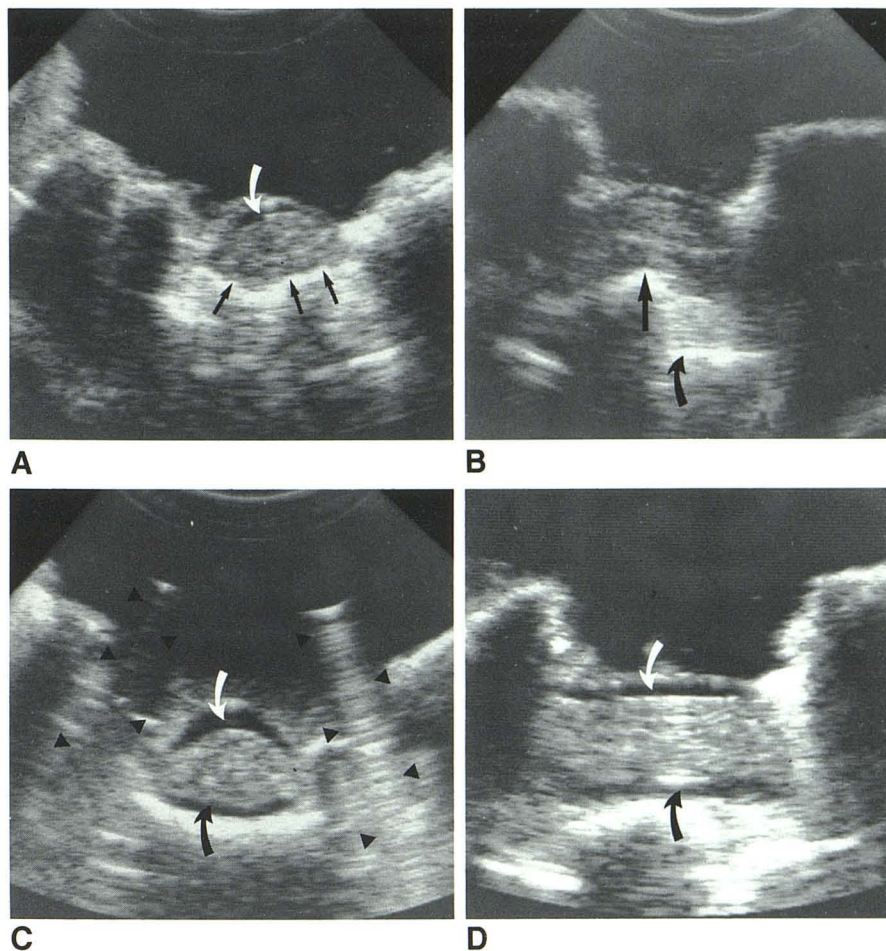
The incidence of fracture is shown in table 2, with fractures of the thoracolumbar junction (T12 and L1) constituting over half of our cases. All of the fractures were considered potentially unstable [2-6] and were associated with displaced bone fragments within the canal. Fifteen patients were neurologically intact or had minimal deficits at the time of surgery; 22 patients had significant neurologic deficits. Thirteen patients were operated on more than 48 hr after the injury. Baseline IOSS, in all patients but one, showed vertebral malalignment and bone fragments compressing the thecal sac. That one patient had a T10 fracture and was neurologically intact, and his baseline IOSS showed neither malalignment nor abnormal bone fragments.

Using the criteria described above, HRI resulted in adequate spine decompression in 14 patients (figs. 1 and 2). In 17 patients, however, inadequate decompression was observed on IOSS after initial Harrington rod insertion. In 15 of those 17 patients, additional surgical procedures or maneuvers were performed in hopes of reducing or removing the offending bone fragment. In 11 patients, the additional procedures resulted in adequate spinal decompression (figs. 3 and 4); in four patients, those procedures did not totally decompress the canal (fig. 5). In two cases, no attempts were made to improve the suboptimally decompressed canal because both patients were neurologically intact and it was decided to avoid any further surgical manipulations. In six patients bone fragments were either removed or impacted before HRI. Five then showed adequate decompression, while one patient required additional bone impaction (fig. 6) before decompression was considered adequate. Table 1 summarizes these data.

Discussion

Over the years, there have been different opinions on how best to manage patients with unstable thoracic and lumbar fractures due to closed spinal injuries. These have ranged

Fig. 1.—Adequate decompression of cauda equina after HRI. **A**, Transverse intraoperative sonogram before HRI. Compression of cauda equina, more marked on right, by displaced bone fragment (arrows). Small amount of cerebrospinal fluid (CSF) (curved arrow) is seen underneath dorsal dura. **B**, Longitudinal sonogram. Displaced bone fragment (straight arrow) from dorsal part of adjacent vertebral body (curved arrow). Transverse (**C**) and longitudinal (**D**) sonograms after bilateral HRI. Adequate decompression of spinal canal, with CSF (arrows) seen around entire cauda equina. In **C** and in following figures, typical sonographic appearance of Harrington rods (arrowheads) is seen.



from the conservative approach of postural reduction [2, 7–9] to the use of Harrington rods and bony fusion [6, 10–12]. The primary goals in the treatment of these injured patients is to improve spinal alignment, establish spinal stability so that progressive kyphotic deformity does not occur, and reduce the bone fragments that have been displaced into the canal. With stability, the chances of developing increasing back pain are lessened, while bone reduction may improve the patient's neurologic status. The trend in recent years has been to treat these patients via open reduction, Harrington rod instrumentation, and spinal fusion, because this method of establishing stability is associated with less pain and spine deformity and earlier patient mobilization and rehabilitation [11–13].

To provide proper stability, two intact vertebrae below the fracture and three vertebrae above the fracture are spanned by the Harrington rods. After distracting and securing the rods, adequate reduction of the fracture, which is located at the apex of the kyphos, is hoped to be achieved. A posterior bony fusion is commonly performed after HRI as a supplement to this stabilization/reduction procedure. Overdistraction of the spine is often avoided by the presence of an intact anterior longitudinal ligament; however, if overdistraction does occur,

it can be easily detected by plain intraoperative spine radiographs. On the other hand, it is difficult for the surgeon to be certain that, with these "blind" rod insertions, adequate distraction and reduction has occurred, because the displaced bone fragments are located anterior to the thecal sac and therefore are not visible. As a result, postoperative spine radiographs [10] or CT [14–16] often show persistent residual bony fragments within the spinal canal after HRI. This may necessitate reoperation in order to remove bone fragments at the site of canal compromise [14, 15]. We believe that most patients with unstable thoracic and lumbar fractures could benefit from an adequate realignment and stabilization of the spinal column and decompression of the neural elements. Clearly, this decompression would preferably be achieved at the time of the initial operation without having to subject the patient to additional surgical procedures.

Direct surgical reduction of displaced bone fragments back into the vertebral body following a posterolateral approach (i.e., partial laminectomy and resection of the medial one-third of the ipsilateral pedicle and parts of the facet joint) has been described [3, 6, 11, 14] as a useful procedure to be done before HRI. Monitoring the results of this procedure with intraoperative myelography has been advocated [6] as a

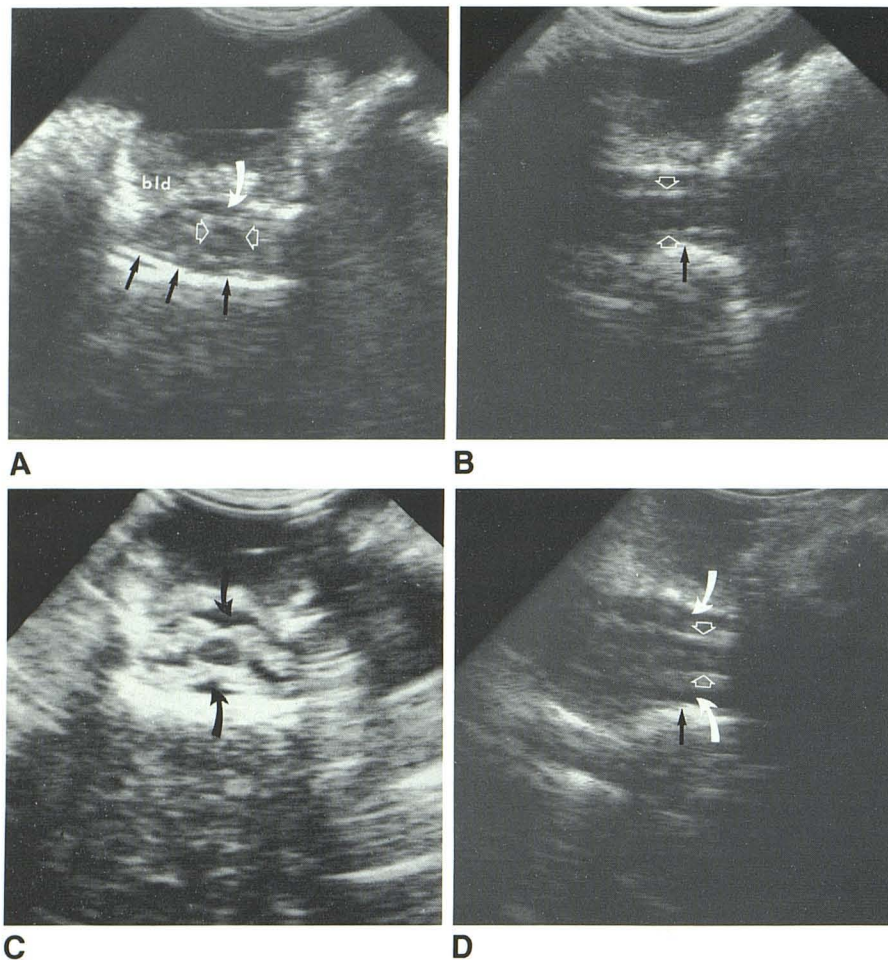


Fig. 2.—Adequate decompression at conus level after HRI. **A**, Transverse intraoperative sonogram before HRI. Compression of thecal sac at conus level by displaced bone fragment (*straight arrows*), which is greater on left. Conus (*between open arrows*) is seen as relative hypodensity in middle of thecal sac. Individual nerve roots surrounding conus can be seen. Small amount of CSF (*curved arrow*) is present underneath dorsal dura; no CSF is seen ventrally. Large amount of blood (*bld*) is seen layering on top of dura. **B**, Midline longitudinal sonogram. Displaced bone fragment (*arrow*) is close to but does not compress ventral surface of conus (*between open arrows*). Intact central echo in middle of conus is seen. Transverse (**C**) and midline longitudinal (**D**) sonograms after HRI. CSF (*curved arrows*) is seen around entire conus and adjacent roots. This is considered adequate decompression, even though some bone fragment displacement (*straight arrow*) and slight vertebral malalignment is still evident. Conus is clearly seen as hypoechoic structure in center of spinal canal in **C** and is outlined by *open arrows* in **D**. Improvement in alignment is best appreciated when distance between displaced bone fragment and ventral surface of conus is compared in pre- (**B**) vs. post-HRI (**D**) sonograms.

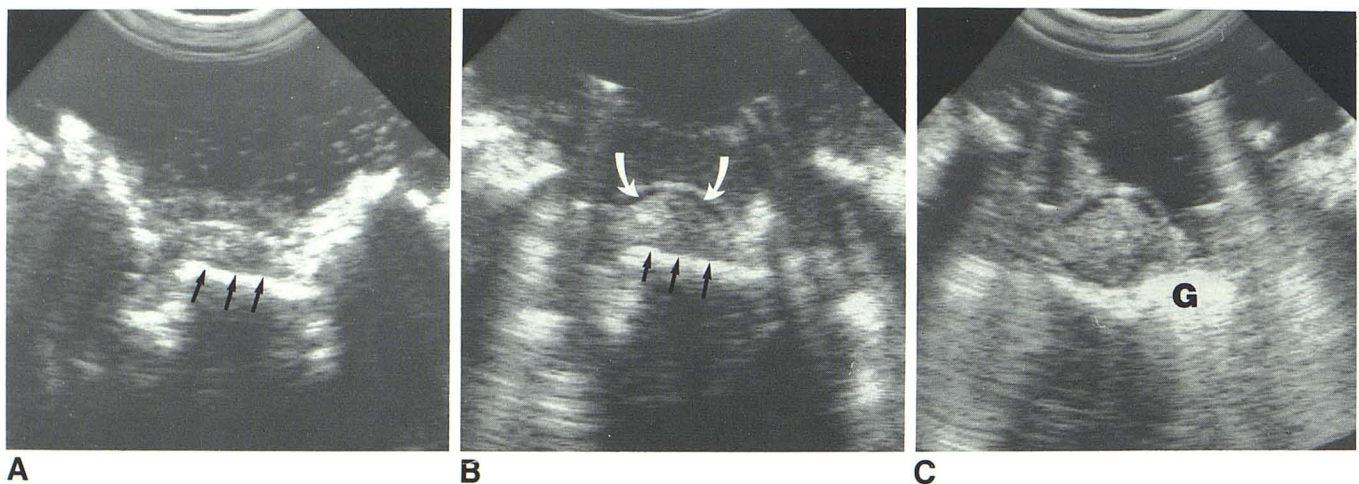
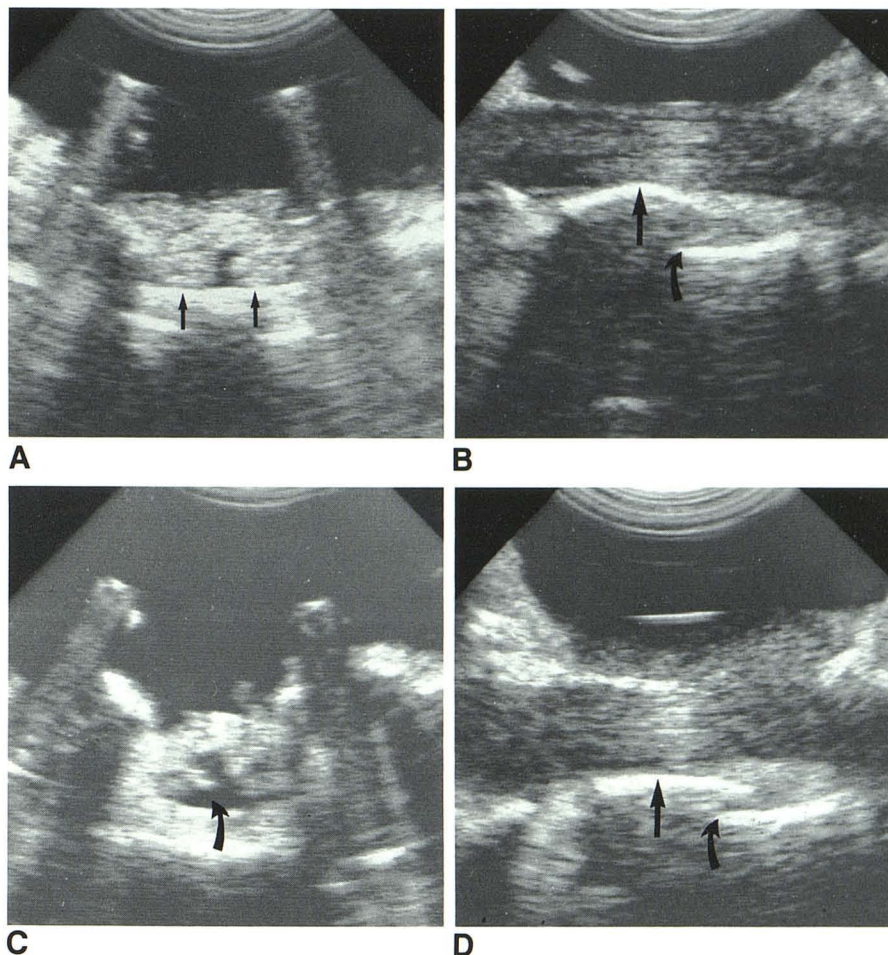


Fig. 3.—Inadequate decompression after HRI, requiring unilateral bone impaction to adequately decompress canal. **A**, Transverse intraoperative sonogram before HRI. Marked compression of cauda equina at L2 level by displaced bone fragment (*arrows*). **B**, Transverse sonogram after bilateral HRI. Lessening of sac compression by bone fragment (*straight arrows*), but significant compression persists. In comparing **A** and **B**, note that Harrington rod placement has resulted in some CSF (*curved arrows*) to now be seen under dorsal dura. Because of presence of persistent bone fragment, right Harrington

rod was removed, and via right posterolateral approach, bone fragment on right was impacted back into vertebral body and right Harrington rod was reinserted. **C**, Dense echogenic structure in right ventral part of canal is Gelfoam (G), not bone. Note that Gelfoam has hyperechoic appearance but, unlike bone, does not acoustically impede sound beam. Without intraoperative sonography, this patient would have been closed after initial HRI and would have been left with compressed cauda equina.

Fig. 4.—Inadequate decompression after HRI, requiring bilateral bone impaction and increased Harrington rod distraction. Initial transverse (A) and longitudinal (B) intraoperative sonograms after insertion of Harrington rods. Bilateral ventral compression of cauda equina at L3 level by displaced bone fragment (A, arrows). Amount of bony displacement is best appreciated as distance from straight arrow to curved arrow on longitudinal image (B). Because of these findings, both Harrington rods were removed, and bilateral bone impaction was performed; Harrington rods were reinserted. C, Final transverse sonogram. Increased amount of CSF (arrow) in thecal sac compared to pre-bony impaction sonogram (A). There is no longer compression of cauda equina. Markedly improved bony alignment is best appreciated when final longitudinal sonogram (D) is compared to amount of bone displacement seen in B (cf. straight and curved arrows). Without intraoperative sonography, patient would have been closed after initial HRI.



means of assuring adequate decompression of the subarachnoid space before HRI and bony fusion. Since most thoracic and lumbar fractures occur from T11 to L1, as shown by our data (23 of our 37 patients) and the data of others [11, 14, 15], retraction of the dura, conus, and adjacent nerve roots may be necessary in order to accomplish the type of bony reduction described above. Not only may such retraction be made difficult by the presence of tethering and scarring at the fracture site, but such maneuvers could have potentially deleterious effects on the spinal cord and roots and their subsequent function. It clearly would be valuable to know if the Harrington rods alone were capable of reducing the bone fragments, because then unnecessary retraction of the spinal cord and prolongation of the surgical procedure would be avoided.

IOSS has afforded us the opportunity to directly visualize the effects of HRI and to monitor and guide subsequent surgical maneuvers. This type of imaging is quicker and we believe more accurate in assessing reduction and alignment than is intraoperative cross-table radiography, a procedure that was recommended [11] before the availability of real-time portable sonographic equipment. In addition to demon-

strating the presence of displaced bone fragments and spinal malalignment, IOSS can rapidly identify and localize the conus medullaris; since occasionally the conus may be in an unexpectedly low position, knowledge of this fact can be extremely helpful to the surgeon when bone fragment removal or impaction is being attempted. Certainly sonography is simpler than performing a lateral hemilaminectomy and a costotransversectomy on the side opposite the initial Harrington rod and verifying visually the adequacy of the decompression [17].

As table 1 indicates, 31 of our patients had HRI as the initial step of the operative procedure performed in order to achieve canal decompression. Of these patients, only 14 (45%) had adequate canal decompression (figs. 1 and 2), while 17 patients (55%) were inadequately decompressed (figs. 3 and 4). In the remaining six patients, we do not know, had HRI rather than bone fragment impaction or removal been first procedure (table 1), whether the canal would have been adequately decompressed. In general, we believe that injuries more than 2 weeks old may not be reduced by HRI alone. The procedure of removing or impacting bone fragments before HRI (fig. 6) was done in the early phase of our experience with IOSS. However, now with increased confidence in

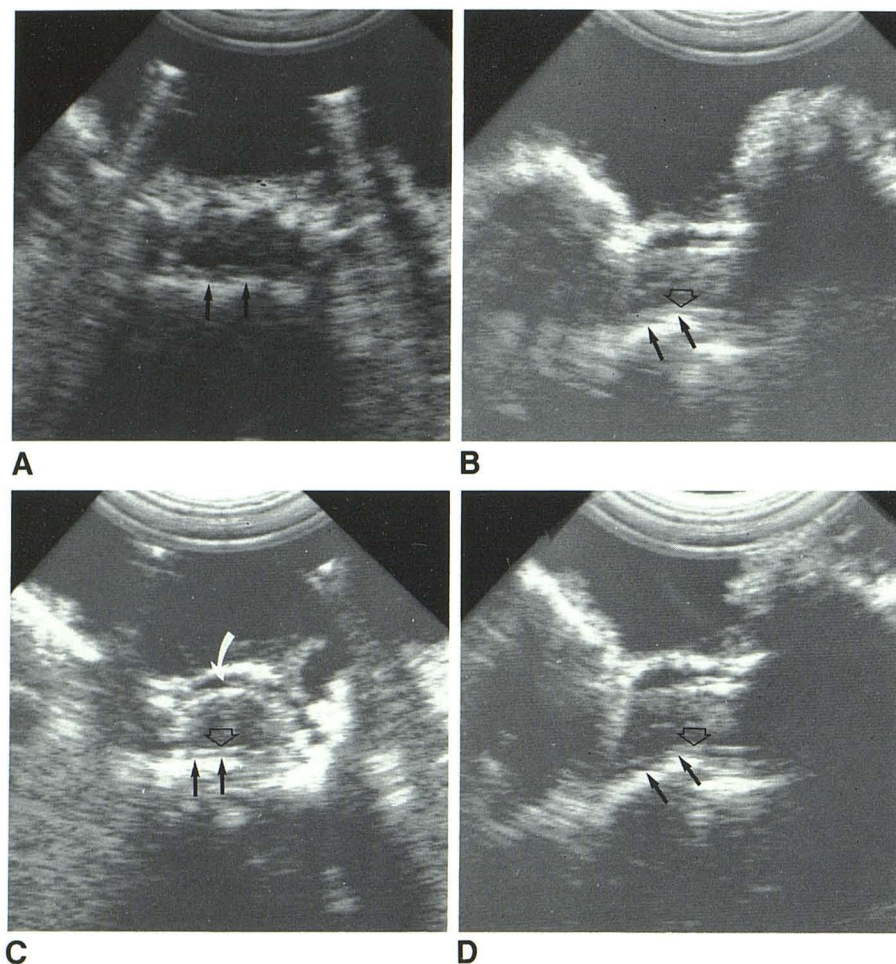


Fig. 5.—Inadequate decompression after HRI; increased Harrington rod distraction performed, but canal still not adequately decompressed; nothing further done because patient neurologically intact. Initial transverse (A) and longitudinal (B) intraoperative sonograms obtained after HRI for T12 fracture. Compression of distal spinal cord by displaced bone fragment (arrows). In B, bone can be seen reaching and distorting ventral surface of spinal cord (open arrow). Because of these findings, Harrington rods were distracted further, which resulted in only slight improvement in vertebral malalignment. Transverse (C) and longitudinal (D) sonograms. Some CSF (curved arrow) now seen dorsally, but distortion of ventral cord surface (open arrows) by displaced bone fragments (straight arrows) persists. Because patient was neurologically intact, it was decided not to attempt to further decompress canal, despite this demonstration of vertebral malalignment.

our interpretation of these images, we believe that Harrington rods can be applied first; then if IOSS shows inadequate decompression, Harrington rod removal followed by bone removal/impaction and/or increasing Harrington rod distraction may be performed. Of our 17 cases where the initial HRI was inadequate, 11 patients had subsequent procedures that resulted in adequate neural element decompression (table 1, fig. 5). The ability of IOSS to immediately detect the inadequacy of HRI is of paramount importance and deserves reemphasis, since immediate corrective surgical steps may be taken because of these sonographic findings and the patient can be spared reoperation.

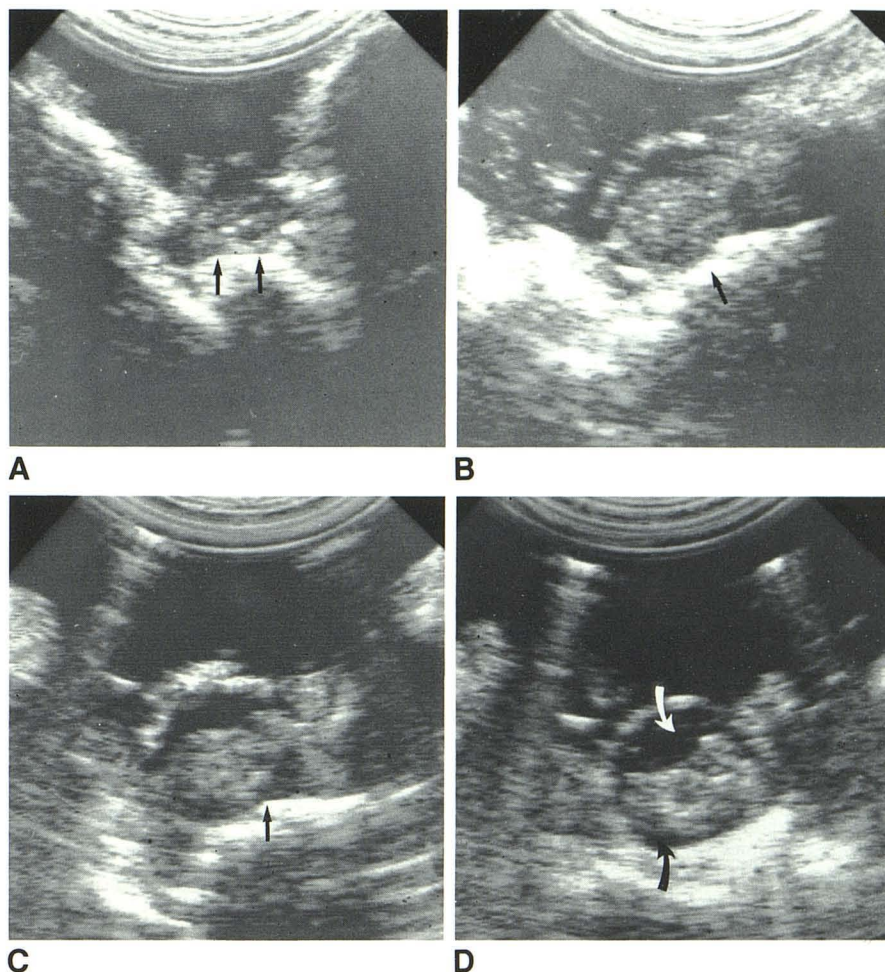
There were four cases where these additional procedures did not adequately decompress the canal (table 1). In one patient, despite attempts at bone impaction at the L3 level, the displaced bone fragment could not be completely reduced and the surgery was terminated after Harrington rod reinsertion. Three patients were neurologically intact, so even though there was sonographic evidence of improved but still suboptimal decompression, it was decided not to try any additional surgical maneuvers (fig. 5).

When all of our cases were considered together, final IOSS showed that spinal canal decompression was eventually adequate in 31 of 37 patients. Of the six patients who were

inadequately decompressed, five had minimal deficits or were neurologically intact on admission to the hospital. Because of the desire to limit the amount of surgery in this group of patients, either nothing further was done after the initial HRI (two patients) or if additional surgical procedures were performed (the three patients described above), the surgeons did not persist in attempting to achieve total canal decompression. If these five patients are recognized as patients in whom persistent efforts at decompression were not made, then there was only one patient in whom attempts to totally decompress the canal were truly unsuccessful.

The results of our study show that if IOSS is not used to monitor the results of HRI in patients with lumbar and thoracic fractures, there will be a significant percentage of cases in which the canal is inadequately decompressed. If, on the other hand, IOSS is used, continued spinal malalignment and displaced bone fragments can be immediately recognized. Surgical steps can then be taken in order to improve spinal alignment and to reduce the bone fragments from the canal. Since adequate neural tissue decompression may relate to the eventual postoperative neurologic outcome, particularly in patients with an incomplete neurologic deficit, we believe that IOSS is invaluable in the surgical management of unstable lumbar and thoracic spine fracture. We recommend the use

Fig. 6.—Bone fragment removal before HRI. **A**, Initial transverse intraoperative sonogram. Displaced bone fragment (arrows) compresses sac at L1 level. Bone fragment was removed after left posterolateral decompression. **B**, Follow-up transverse sonogram shows rounder-appearing sac, but bone fragment (arrow) persists on right side. HRI was then performed. **C**, Transverse sonogram. Bone fragment on right (arrow) still not completely reduced. As a result, Harrington rod was removed, and bone fragment was impacted back into adjacent vertebral body. **D**, Transverse sonogram after reinsertion of Harrington rod. More symmetric-appearing bony canal and more CSF (arrows) around roots of cauda equina.



of IOSS in all cases where HRI is used to stabilize and reduce thoracic and lumbar spine fractures.

REFERENCES

1. Quencer RM, Montalvo BM. Normal intraoperative spinal sonography. *AJNR* 1984;5: 501-505, *AJR* 1984;143:1301-1305
2. Bedrock GM. Stability of spinal fractures and fracture dislocations. *Paraplegia* 1971;9: 23-32
3. McAfee PC, Yuan HA, Lasada NA. The unstable burst fracture. *Spine* 1982;7: 365-373
4. Holdsworth FW. Fractures, dislocations and fractures of the spine. *J Bone Joint Surg [Br]* 1963;45: 6-20
5. Holdsworth FW. Fractures, dislocations and fractures/dislocation of the spine. *J Bone Joint Surg [Am]* 1970;52: 1534-1551
6. Schmidek HH, Gomes FB, Seligson D, McSherry JW. Management of acute, unstable thoracolumbar (T₁₁-T₁) fractures with and without neurological deficit. *Neurosurgery* 1980;7: 30-35
7. Burke DC, Murray DD. The management of thoracic and thoracolumbar injuries of the spine with neurological involvement. *J Bone Joint Surg [Br]* 1974;56: 603-612
8. Frankel HL, Hancock DO, Hyslop G, et al. The value of postural reduction in the initial management of closed injuries of the spine with paraplegia and tetraplegia. Part 1. *Paraplegia* 1969;7: 179-192
9. Guttman L. *Spinal cord injuries: comprehensive management and research*. Oxford: Blackwell Scientific, 1973: 122-156
10. Dickson JH, Harrington PR, Ervin WD. Results of reduction and stabilization of the severely fractured thoracic and lumbar spine. *J Bone Joint Surg [Am]* 1978;60: 799-805
11. Flesch JR, Leider LL, Erickson DL, Chou SN, Bradford DS. Harrington instrumentation and spinal fusion for unstable fractures and fracture/dislocations of the thoracic and lumbar spine. *J Bone Joint Surg [Am]* 1977;59: 143-153
12. Yosipovitch Z, Robin GC, Makin M. Open reduction of unstable thoracolumbar spinal injuries and fixation with Harrington rods. *J Bone Joint Surg [Am]* 1977;59: 1003-1015
13. Lewis J, McKibbin B. The treatment of unstable fracture dislocations of the thoraco-lumbar spine accompanied by paraplegia. *J Bone Joint Surg [Br]* 1974;56: 603-612
14. Durward QJ, Schweigel JF, Harrison P. Management of fractures of the thoracolumbar and lumbar spine. *Neurosurgery* 1981;8: 555-561
15. Golimbu C, Firooznia H, Rafii M, Engler G, Delman A. Computed tomography of thoracic and lumbar spine fractures that have been treated with Harrington instrumentation. *Radiology* 1984;151: 731-733
16. White RR, Newberg A, Seligson D. Computerized tomographic assessment of the traumatized dorsolumbar spine before and after Harrington instrumentation. *Clin Orthop* 1980;146: 150-156
17. Seljeskog EL. Comments. *Neurosurgery* 1981;8: 560-561