



Discover Generics

Cost-Effective CT & MRI Contrast Agents



FRESENIUS
KABI

WATCH VIDEO

AJNR

Proton imaging and phosphorus spectroscopy in a malignant glioma.

R A Zimmerman, P A Bottomley, W A Edelstein, H R Hart, R W Redington, L T Bilaniuk, R I Grossman, H I Goldberg, L Bruno and H Kressel

This information is current as
of June 21, 2025.

AJNR Am J Neuroradiol 1985, 6 (1) 109-110
<http://www.ajnr.org/content/6/1/109.citation>

Proton Imaging and Phosphorus Spectroscopy in a Malignant Glioma

Robert A. Zimmerman,¹ Paul A. Bottomley,² William A. Edelstein,² Howard R. Hart,² Rowland W. Redington,² Larissa T. Bilaniuk,¹ Robert I. Grossman,¹ Herbert I. Goldberg,¹ Leonard Bruno,³ and Herbert Kressel¹

Since 1980 several papers have detailed the value of ¹H magnetic resonance imaging (MRI) of the central nervous system as being clinically useful [1–8]. Recently, Cady et al. [9] used ³¹P MRI to study the cerebral metabolism of newborn infants suffering birth asphyxia, meningitis, congenital abnormalities, and cerebral edema. Bottomley et al. [10] described the first in vivo ³¹P spectra and high-field ¹H MR images in a normal adult volunteer. We now report both ¹H MR images and ³¹P MR chemical-shift spectroscopic studies in a patient with a malignant glioma of the left temporal parietal lobe undergoing radiation and chemotherapy. The ability to perform both ¹H imaging and in vivo phosphorus spectroscopy with the same instrument with only a 5–10 min changeover delay opens a new avenue in the investigation of neurologic diseases.

Case Report

A 59-year-old man had a 6-month history of grand mal seizures and slowly developing dyslexia with some dysphagia. Neurologic examination was normal. A computed tomographic (CT) scan showed a right peritrial contrast-enhanced mass surrounded by edema. A resistive ¹H MR examination performed at the Hospital of the University of Pennsylvania using a 0.12 T prototype MR system in the transverse and coronal planes showed both the mass and the surrounding edema. Surgical biopsy revealed a grade III astrocytoma. CT was repeated after biopsy and revealed the tumor to be essentially unchanged (fig. 1A). The patient was placed on Decadron and treated to a level of 5,000 rad (50 Gy) with parallel opposed portals. At the end of radiation therapy and 2 months after initial studies, the patient was evaluated with the 1.5 T imaging/spectroscopy system at the General Electric Research and Development Center in Schenectady, NY. Series of ¹H MR images and ³¹P MR chemical-shift spectra were recorded (figs. 1B and 1C).

General Electric 1.5 T Imaging/Spectroscopy System

A 1.5 T, 1-m-bore MR imaging/spectroscopy system was used to obtain proton MR images and ³¹P MR chemical shift spectra. The examinations were performed within 3/4 hr of each other. Examina-

tions were done at a 64 MHz ¹H resonance frequency and a 26 MHz ³¹P frequency. The image was a 256 × 256 point, 6 mm single slice obtained in 306 sec using a spin-echo (SE) spin-warp imaging method and partial saturation pulse sequence with a 600 msec repetition time (TR) and an echo time of 16 msec. ³¹P spectra were recorded from the left and right sides at the same level as the image using a 6.5-cm-diameter surface coil. Each spectrum represented the Fourier transform of 50 averaged free-induction decays obtained in 800 sec using a 16,000 msec pulse TR to avoid spectral distortion due to different MR relaxation times of the metabolic peaks. Free induction decays were multiplied by a 20 msec time constant exponential filter before Fourier transformation. Spectra contained contributions from both brain and surface tissue in the approximate ratio 2:1, respectively [11], and extending about 4 cm into the brain.

The proton image of the brain showed the area of tumor and edema within the left parietotemporal region (fig. 1B). ³¹P MR chemical-shift spectra showed peaks corresponding to shifts of sugar phosphates, inorganic phosphates, phosphodiesteres, phosphocreatine, and to the α -, β -, and γ -phosphates of adenosine triphosphate (ATP). Spectrum obtained from the normal side was comparable to spectra obtained from 10 normal subjects previously studied. Spectrum from the tumor-edema side showed a 40% decrease in the phosphocreatine to β -ATP ratio, compared with the normal-side spectrum, as calculated from the area under the baseline-deconvolved peaks. This was from a loss of phosphocreatine. Inorganic phosphate levels were unchanged and not accurately determinable in either these experiments or in the normal studies.

Discussion

Minimal effort is required to switch between phosphorus and hydrogen data acquisition. Indeed, data can be acquired with both MR coils present, since there is essentially no interaction between coils owing to their different MR frequencies. All that is required is appropriate adjustment of MR spectrometer operating frequencies and adjustment of the band-width filters for data acquisition.

An application of ³¹P spectroscopy to in vivo study of mice with subcutaneous implanted murine and human tumors and their response to therapy was reported by Ng et al. [12]. They

Received March 21, 1984; accepted after revision July 11, 1984.

¹ Department of Radiology, Hospital of the University of Pennsylvania, 3400 Spruce St., Philadelphia, PA 19104. Address reprint requests to R. A. Zimmerman.

² General Electric Research and Development Center, Schenectady, NY 12301.

³ Department of Neurosurgery, Hospital of the University of Pennsylvania, Philadelphia, PA 19104.

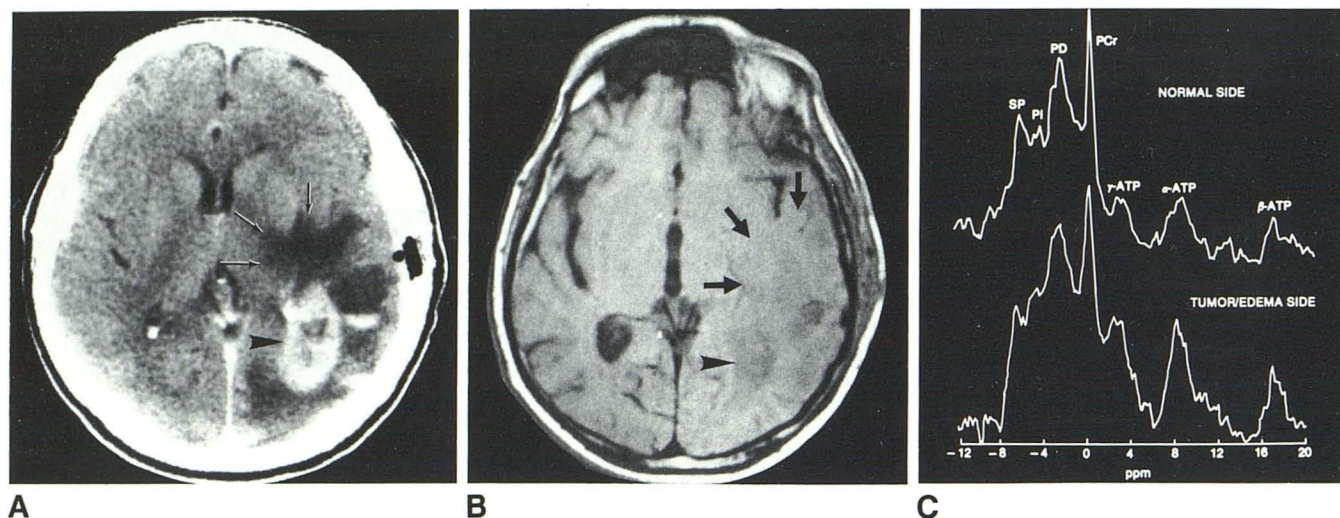


Fig. 1.—A, CT scan after biopsy. Contrast-enhanced peritumoral tumor (arrowhead) surrounded by edema (arrows). B, 1.5 T ^1H SE 600/16 image. Tumor (arrowhead) and surrounding mass effect from edema (arrows). C, ^{31}P MR chemical shift spectra for normal side (top) and tumor-edema side (bottom). Chemical shifts are in parts per million (ppm) relative to phosphocreatine (PCr). SP = sugar phosphates; Pi = inorganic phosphates; PD = phosphodiesteres.

noted considerable variability in the metabolic characteristics of tumors, even at the same stage of growth, suggestive of factors intrinsic to the host animal. However, both chemotherapy and radiation therapy produced substantial initial decreases in the phosphocreatine/ATP ratio of mouse tumor ^{31}P spectra. Given that sugar phosphate and inorganic phosphate levels are not elevated in our spectra, and that most of the brain tissue detected by the surface coil is edematous rather than tumorous, as is apparent from the CT and MR scans, radiation/chemotherapy effects may also be responsible for the reduced phosphocreatine/ATP ratio observed here. The metabolic information is augmented by ^1H MR scans, which add anatomic details of the region of interest.

REFERENCES

- Holland GN, Hawkes RC, Moore WS. Nuclear magnetic resonance (NMR) tomography of the brain: coronal and sagittal sections. *J Comput Assist Tomogr* 1980;4:429-433
- Bydder GM, Steiner RE. NMR imaging of the brain. *Neuroradiology* 1982;23:231-240
- Johnson MA, Pennock JM, Bydder GM, et al. Clinical NMR imaging of the brain in children: normal and neurologic disease. *AJNR* 1983;4:1013-1026, *AJR* 1983;141:1005-1018
- Randell CP, Collins AG, Young IR, et al. Nuclear magnetic resonance imaging of posterior fossa tumors. *AJNR* 1983;4:1027-1034, *AJR* 1983;141:489-496
- Sipponen JT, Kaste M, Ketonen L, Sepponen RE, Kätevuori K, Sivula A. Serial nuclear magnetic resonance (NMR) imaging in patients with cerebral infarction. *J Comput Assist Tomogr* 1983;7:585-589
- Vermess M, Bernstein RM, Bydder GM, Steiner RE, Young IR, Hughes GRV. Nuclear magnetic resonance (NMR) imaging of the brain in systemic lupus erythematosus. *J Comput Assist Tomogr* 1983;7:461-467
- Huk W, Heindel W, Deimling M, Stetter E. Nuclear magnetic resonance (NMR) tomography of the central nervous system: comparison of two imaging sequences. *J Comput Assist Tomogr* 1983;7:468-475
- Zimmerman RA, Bilaniuk LT, Goldberg HI, et al. Cerebral NMR imaging: early results with a 0.12 T resistive system. *AJNR* 1984;5:1-7, *AJR* 1983;141:1187-1193
- Cady EB, DelCostello AM, Dawson MJ, et al. Noninvasive investigation of cerebral metabolism in newborn infants by phosphorus nuclear magnetic resonance response spectroscopy. *Lancet* 1983;1:1059-1062
- Bottomley PA, Hart HR, Edelstein WA, et al. NMR imaging/spectroscopy system to study both anatomy and metabolism. *Lancet* 1983;2:273-274
- Bottomley PA, Edelstein WA, Hart HR, et al. Spatial localization in ^{31}P and ^{13}C spectroscopy in vivo using surface coils. *Magnetic Resonance Med* 1984;1:410-413
- Ng TC, Evanochko WT, Hiramoto RN, et al. ^{31}P NMR spectroscopy in vivo tumors. *J Magnetic Resonance* 1982;49:271-286