



## Discover Generics

Cost-Effective CT & MRI Contrast Agents



FRESENIUS  
KABI

WATCH VIDEO

# AJNR

## Percutaneous biopsy of a metastatic spinal nerve root nodule in a child.

P Stanley and M O Senac, Jr

*AJNR Am J Neuroradiol* 1984, 5 (4) 427-428

<http://www.ajnr.org/content/5/4/427.citation>

This information is current as  
of June 23, 2025.

## Percutaneous Biopsy of a Metastatic Spinal Nerve Root Nodule in a Child

Philip Stanley<sup>1</sup> and Melvin O. Senac, Jr.<sup>1</sup>

Nodular deposits on lumbar nerve roots are a well recognized manifestation of metastatic spread of certain intracranial tumors, particularly medulloblastoma and ependymoma, via the subarachnoid pathway. The histologic diagnosis usually is established at the time of posterior fossa exploration. However, obtaining a diagnosis at surgery can be hazardous in some intraaxial masses that do not have an exophytic component. If subarachnoid nodular implants are present, a percutaneous biopsy may be performed to establish the exact diagnosis.

### Case Report

A 6-year-old boy was admitted to Childrens Hospital with a 4-week history of ataxia, drooling, spastic gait, and personality change. Physical examination revealed a wide-based gait and truncal ataxia. Computed tomography (CT) demonstrated an expanded brainstem with a hypodense circumference. After administration of intravenous contrast material, there was some enhancement of the center of the brainstem mass. The basilar artery appeared to be engulfed by the

mass, and the prepontine cisterns were compressed. The fourth ventricle was displaced posteriorly and flattened. The confident diagnosis of a brainstem astrocytoma was made. On this basis, a decision was made against surgery, and no histologic diagnosis was obtained at this time.

The patient was treated on a study-group protocol with chemotherapy and radiation therapy to the posterior fossa. There was some improvement for 4 months, but then he had headache and vomiting. A lumbar puncture revealed protein of 400 mg/dl, but no malignant cells were seen. A myelogram demonstrated multiple subarachnoid nodules in the lumbar region with irregular attenuation of the thecal sac due to metastatic disease (fig. 1A). Because a histologic diagnosis had never been obtained and because nodular implants in the subarachnoid space are very uncommon with brainstem gliomas, it was decided to perform a percutaneous biopsy.

Under basal sedation (Phenobarbitone 50 mg/kg intravenously), a lumbar puncture using a 22-gauge needle was first performed at the L2-L3 interspace and 7 ml of metrizamide (220 mg I/ml) was injected. To prevent blunting of the biopsy needle and to give better maneuverability, an 18-gauge needle 3½ inches (8.9 cm) long was introduced into the subarachnoid space at the level of the L4-L5 interspace. Using fluoroscopic control, a 21-gauge aspiration biopsy

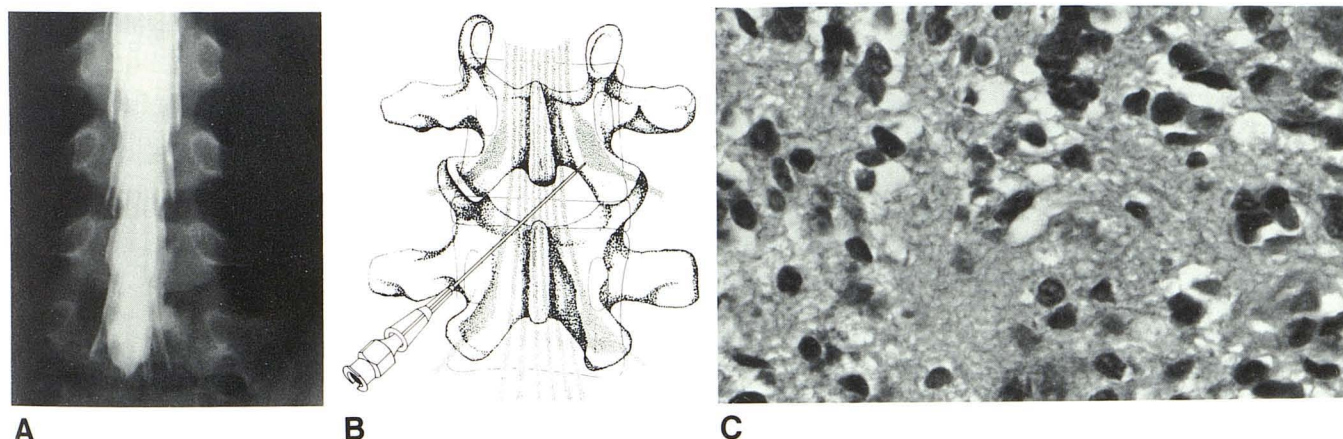


Fig. 1.—A, Metrizamide myelogram. Multiple nodules on lumbar nerve roots with irregularity of distal lumbosacral sac. B, Percutaneous biopsy technique: passage of 21-gauge biopsy needle through previously placed 18-gauge spinal needle. C, Photomicrograph of biopsy specimen. Moderately cellular astrocytoma. (H and E; original magnification  $\times 250$ .)

Received January 31, 1983; accepted April 4, 1983.

<sup>1</sup> Department of Radiology, University of Southern California School of Medicine, Los Angeles, CA 90033, and Childrens Hospital of Los Angeles, P.O. Box 54700, Los Angeles, CA 90054. Address reprint requests to P. Stanley at Childrens Hospital.

AJNR 5:427-428, July/August 1984 0195-6108/84/0504-0427 \$2.00 © American Roentgen Ray Society

needle (Surecut; Surgimed, Summerville, SC) was then guided through the 18-gauge needle, and suction biopsies of the nodules on the right L4 and L5 nerve roots were obtained (fig. 1B). After removal of the 21-gauge needle, a final aspiration biopsy of the L4 nerve root was performed with the 18-gauge needle before it was withdrawn. Histologic examination of all the biopsies showed a similar pattern: that of a moderately cellular astrocytoma or possibly a tumor undergoing astrocytic differentiation (fig. 1C) (Gilles FH, personal communication).

### Discussion

There have been several reports of metastatic seeding along cerebrospinal fluid from intracranial tumors. Of the tumors that spread in this manner, medulloblastomas and ependymomas are among the most common [1-4]. On the basis of the myelographic study, our patient was believed to have one of these two tumors, both of which are treated differently from a brainstem astrocytoma (the initial diagnosis).

Percutaneous biopsy of small lesions in the chest and abdomen is a well established procedure, and Quencer [5]

reported needle aspiration of intradural extramedullary masses in two adults. We believed that by modifying this technique, a pathologic specimen from a nerve root nodule could be obtained. The percutaneous biopsy established a histologic diagnosis of astrocytoma, thus enabling the best specific therapy to be given.

### REFERENCES

1. Wood EH, Taveras JM, Pool JL. Myelographic demonstration of spinal cord metastases from primary brain tumors. *AJR* **1953**;69:221-230
2. Enzmann DR, Norman D, Levin V, Wilson C, Newton TH. Computed tomography in the follow-up of medulloblastomas and ependymomas. *Radiology* **1978**;128:57-63
3. Guyer PB, Westbury H. The myelographic appearances of spinal cord metastases. *Br J Radiol* **1968**;41:615-619
4. Bryan P. CSF seeding of intracranial tumors: a study of 96 cases. *Clin Radiol* **1974**;25:355-360
5. Quencer RM. Needle aspiration of intramedullary and intradural extramedullary masses of the spinal canal. *Radiology* **1980**;134:115-126