



Providing Choice & Value
Generic CT and MRI Contrast Agents

**FRESENIUS
KABI**

CONTACT REP

AJNR

**Long-Term Follow-up of Multinodular and
Vacuolating Neuronal Tumors and
Implications for Surveillance Imaging**

S. Dogra, D. Zagzag, M. Young, J. Golfinos, D. Orringer and
R. Jain

This information is current as
of July 22, 2025.

AJNR Am J Neuroradiol 2023, 44 (9) 1032-1038

doi: <https://doi.org/10.3174/ajnr.A7946>

<http://www.ajnr.org/content/44/9/1032>

Long-Term Follow-up of Multinodular and Vacuolating Neuronal Tumors and Implications for Surveillance Imaging

 S. Dogra,  D. Zagzag,  M. Young,  J. Golfinos,  D. Orringer, and  R. Jain



ABSTRACT

BACKGROUND AND PURPOSE: Most multinodular and vacuolating neuronal tumors (MVNTs) are diagnosed and followed radiologically without any change across time. There are no surveillance guidelines or quantitative volumetric assessments of these tumors. We evaluated MVNT volumes during long follow-up periods using segmentation tools with the aim of quantitative assessment.

MATERIALS AND METHODS: All patients with MVNTs in a brain MR imaging report in our system were reviewed. Patients with only 1 brain MR imaging or in whom MVNT was not clearly the most likely diagnosis were excluded. All MVNTs were manually segmented. For all follow-up examinations, absolute and percentage volume change from immediately prior and initial examinations were calculated.

RESULTS: Forty-eight patients (32 women; median age, 50.5 years at first scanning) underwent 158 brain MRIs. The median duration between the first and last scan was 15.6 months (interquartile range, 5.7–29.6 months; maximum, 6.4 years) and between consecutive scans, it was 6.7 months (interquartile range, 3.3–12.4 months; maximum, 4.9 years). Pearson correlation coefficients between days since immediately prior scan versus absolute and percentage volume change from immediately prior scan were $r = 0.05$ ($P = .60$) and $r = 0.07$ ($P = .45$), respectively. For the relationship between days since the first scan versus absolute and percentage volume change from the first scan, values were $r = -0.06$ ($P = .53$) and $r = -0.04$ ($P = .67$), respectively.

CONCLUSIONS: MVNT segmentation across follow-up brain MR imaging examinations did not demonstrate significant volume differences, suggesting that these tumors do not enlarge with time. Hence, frequent surveillance imaging of newly diagnosed MVNTs may not be necessary.

ABBREVIATIONS: DNET = dysembryoplastic neuroepithelial tumor; IQR = interquartile range; MVNT = multinodular and vacuolating neuronal tumor

Multinodular and vacuolating neuronal tumors (MVNTs) are relatively newly described entities, having been introduced in the literature first in 2013, included as an architectural pattern in the World Health Organization (WHO) Classification of CNS tumors in 2016, and officially admitted as a grade 1 tumor in the 2021 Classification.^{1–3} Although the number of reported cases in the literature overall remains low, most patients appear to be middle-aged at the time of presentation. Three of the largest studies and reviews of MVNTs report median ages at presentation of 44 and 45 years and a mean age of 39, though diagnoses verified by histopathology have been made in ages as young as 10 years.^{4–7}

The most common presenting symptoms in patients found to have MVNTs are headaches and seizures, but a significant portion of lesions are discovered incidentally.^{5,8–11} Histopathology typically demonstrates neuroepithelial cells with stromal vacuolation and nodular arrangement located principally in the deep cortical ribbon and superficial subcortical white matter (Fig 1).^{7,12,13} On MR imaging, these lesions typically present as a cluster of juxtacortical nodules that are iso- to mildly hypointense on T1 with rare post-contrast enhancement and hyperintense on T2 and FLAIR and do not demonstrate diffusion restriction.^{5,7} Alternative diagnoses most often include enlarged perivascular spaces, low-grade gliomas, focal cortical dysplasia, or dysembryoplastic neuroepithelial tumors (DNETs), and indeed, many MVNTs were initially misdiagnosed as one of these entities before the 2016 description of MVNTs in the WHO Classification.⁷

On the basis of numerous case reports and series with stable clinical and radiologic follow-up, MVNTs have been suggested to be benign lesions and have consequently been described as “do not touch” and “leave me alone,” despite being a grade 1 tumor

Received May 2, 2023; accepted after revision June 16.

From the Departments of Radiology (S.D., M.Y., R.J.), Pathology (D.Z.), and Neurosurgery (J.G., D.O., R.J.), New York University Grossman School of Medicine, New York, New York.

Please address correspondence to Rajan Jain, MD, Department of Radiology, New York University Grossman School of Medicine, 660 First Ave, New York, NY 10016; e-mail: Rajan.Jain@nyulangone.org; @siddograMD

<http://dx.doi.org/10.3174/ajnr.A7946>

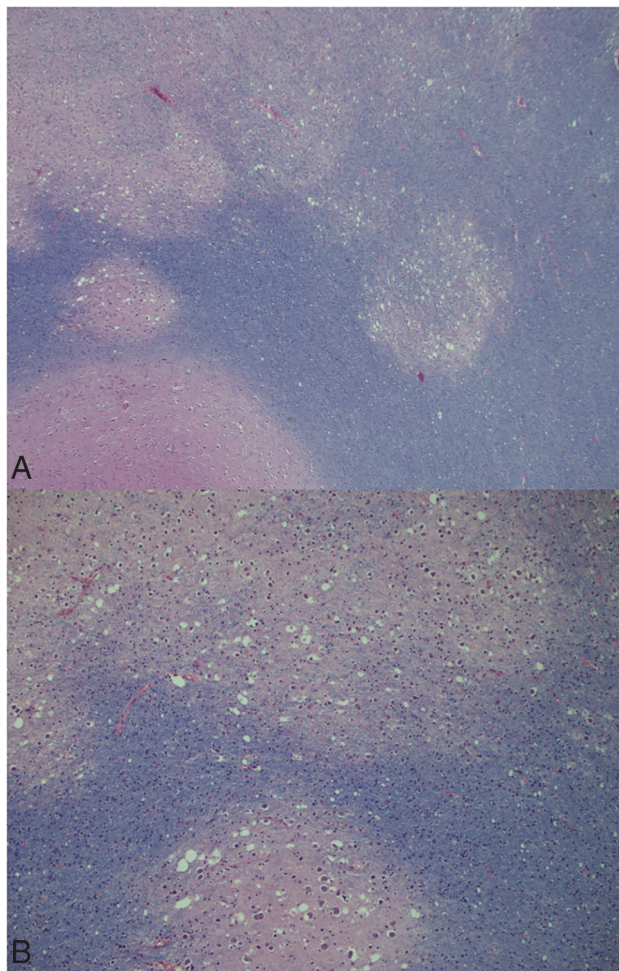


FIG 1. A, Low-power view shows multiple discrete nodules and the typical multinodular and vacuolating features of the tumor. The Luxol fast blue stain helps delineate the nodules of various sizes, and the pale staining indicates the variable loss of myelin in tumor nodules present in the white matter. Mitotic figures, necrosis, or microvascular proliferation are not seen (Luxol fast blue stain, $\times 50$). B, A higher power reveals variously shaped vacuoles and variably sized cellular elements within the nodules. A few larger pleomorphic cellular elements are more evident in the lower nodule. Some tumor cells show an ambiguous neuronlike appearance (Luxol fast blue stain, $\times 100$).

by WHO classification.^{7,8,14} In particular, 1 study reported that 6.7% of lesions categorized as MVNT showed progression on follow-up MR imaging, while the others were stable for up to 93 months, and another followed patients up to 144 months (using MVNT diagnoses made retrospectively on older cases that previously had alternative diagnoses) with a mean follow-up of 36.8 months and did not find any significant interval change.^{5,7} Given the reassuring course of patients with MVNTs, consensus holds that these lesions do not require biopsy or resection and can be safely followed with MR imaging surveillance; however, no uniform guidelines exist regarding the frequency of these surveillance scans. Moreover, these studies relied on qualitative evaluation of MVNT size to document stability, and no MVNT studies have included tumor segmentation and volumetric assessment.

The purpose of this study was to analyze serial imaging of patients with MVNTs using manual segmentation to quantitatively

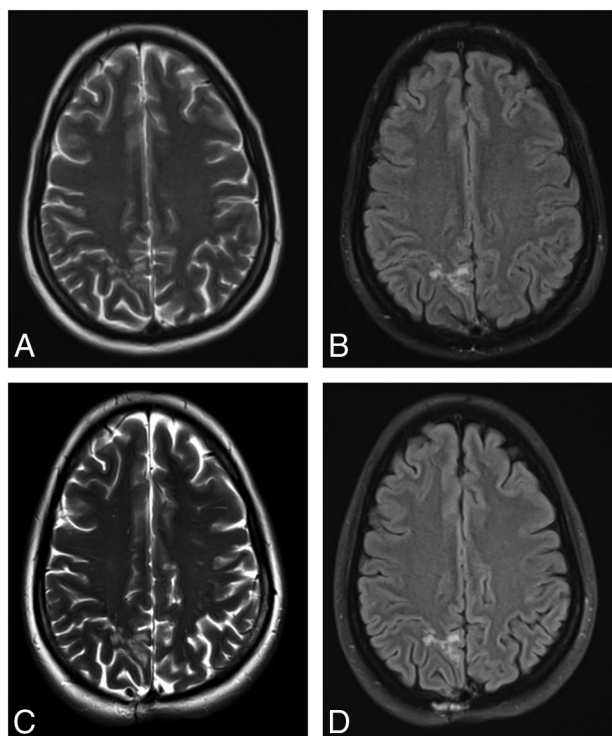


FIG 2. T2-weighted and FLAIR images from the baseline (A and B) and 6.4-year follow-up (C and D) MR imaging of a representative patient with a right superior parietal lobule MVNT.

evaluate tumor volume changes with time and to suggest guidelines regarding optimal MR imaging surveillance, with the hope that such guidelines reduce unnecessary imaging and stress in these patients.

MATERIALS AND METHODS

This single-institutional retrospective study was approved by the institutional review board. A waiver of consent was obtained due to the anonymized and retrospective nature of the study.

Subject Selection

We used the search function on our PACS to select all brain MR imaging reports through November 4, 2022, that mentioned “multinodular and vacuolating neuronal tumor” or “MVNT” in the report body. All reports were evaluated by fellowship-trained neuroradiologists at the original time of dictation. Search results were manually reviewed, and if MVNT was thought by the original reading neuroradiologist to be the most likely diagnosis for a particular patient, that patient was considered for inclusion. Exclusion criteria included having only 1 brain MR imaging examination available, lack of T2 and/or FLAIR sequences, and the presence of other structural lesions precluding MVNT segmentation.

One hundred twenty-eight patients had a mention of “multinodular and vacuolating neuronal tumor” or “MVNT” in at least 1 brain MR imaging report on our PACS. Of these patients, 39 patients had only 1 brain MR imaging and were excluded. Of the remainder, 41 patients were excluded because MVNT was not the clear top differential diagnosis, resulting in the final cohort of 48 patients.

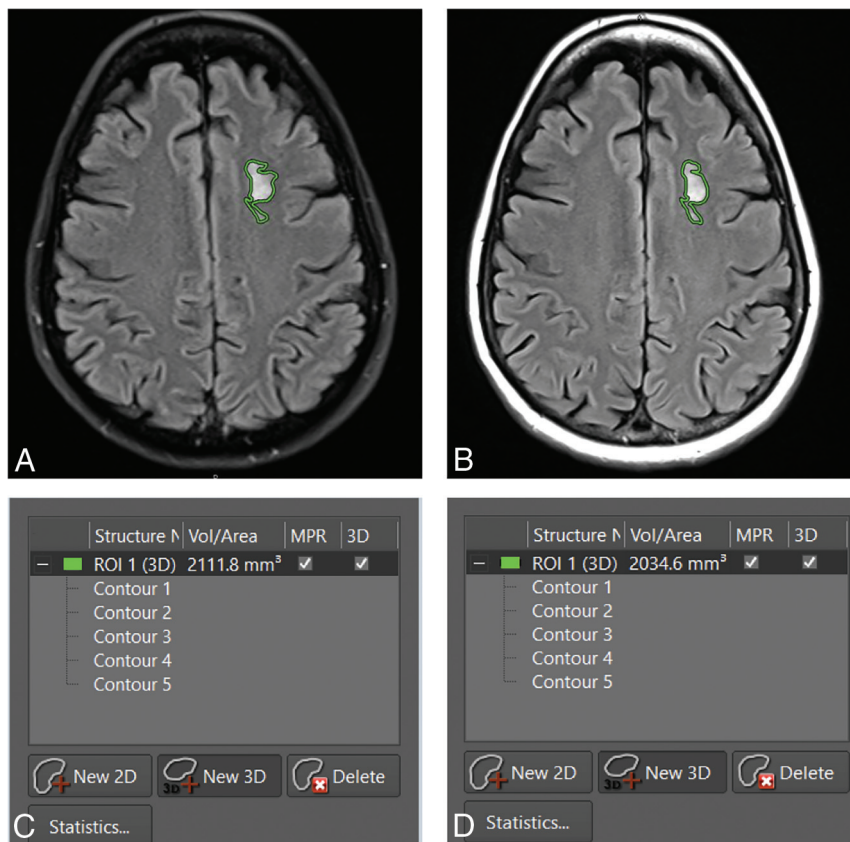


FIG 3. Representative FLAIR images from the baseline (A) and the second (B) MR imaging of a patient with a left-frontal MVNT (segmented in green). C and D, Images corresponding to the MR imaging examinations shown in A and B, respectively, show what the segmentation volume window looks like in our PACS.

Clinical Data

The electronic health record for every included patient was reviewed. Demographic and clinical data were collected, including the indication for initial imaging, age at time of the initial examination, and any histopathologic data.

MR Imaging and Analysis

MR imaging was performed on a variety of 1.5T or 3T scanners at our institution, with exact scanning parameters varying among scanners.

The MVNT location was noted. MVNT signal characteristics were recorded for T1 pre- and postcontrast, T2, FLAIR, DWI, and ADC sequences across all examinations. All MVNTs were manually segmented on the FLAIR sequence from every MR imaging using a free-form segmentation tool on our PACS. Segmentation was performed on a randomized order of examination accession numbers so that consecutive segmentations were not necessarily performed on imaging even from the same subject, to minimize the risk of subconscious bias. Because many examinations, for example generally the initial examination, had 2D FLAIR sequences but not 3D FLAIR sequences, segmentation was preferentially performed on the FLAIR sequences (section thickness ranging from 3 to 5 mm) to allow optimal comparison. A small number of examinations had only 3D FLAIR sequences (1-mm section thickness), which were consequently used for segmentation.

Following segmentation, 3D volume was automatically generated for every MVNT.

For every follow-up MR imaging examination, we calculated the following: number of days since the immediately prior and original examinations, absolute MVNT volume change (in cubic centimeters) since the immediately prior and original examinations, and percentage MVNT volume change since the immediately prior and original examinations.

Statistical Analysis

All statistical analyses were performed by using R statistical and computing software (Version 4.0.5; <http://www.r-project.org/>). All *P* values were calculated as 2-tailed with significance set at a level of *P* < .05.

Pearson correlation coefficients and 2-tailed *P* values were calculated between the number of days since the immediately prior examinations and both absolute and percentage volume changes since the immediately prior examinations. They were also calculated between the number of days since the original examination and the absolute and percentage volume changes since the original examination. The Wilcoxon

signed-rank test was used to compare median MVNT volumes at the original and terminal scans.

RESULTS

Forty-eight patients (32 women; median age, 50.5 years at the time of first scan with a range of 10–76 years) underwent a total of 158 brain MRIs between June 28, 2014, and November 4, 2022. The median duration between the first and last scan was 15.6 months (interquartile range [IQR], 5.7–29.6 months; maximum, 6.4 years). The median duration between consecutive scans was 6.7 months (IQR, 3.3–12.4 months; maximum, 4.9 years). Two patients had confirmed MVNT on histopathology.

Clinically, 1 patient has had new migraines since sustaining a concussion, and another patient has developed suspected autoimmune encephalitis, but neither symptom is suspected to be related to their MVNT. Otherwise, all patients with initial neurologic symptoms are stable or improving.

All MVNTs were T2- and FLAIR-hyperintense on every examination (Fig 2). None were intrinsically T1-hyperintense, and none demonstrated enhancement after contrast administration on both baseline and follow-up studies. None exhibited true restricted diffusion (ADC hypointense and DWI hyperintense), but 77% (37/48) exhibited T2 shintthrough (ADC and DWI both hyperintense) on the baseline MR imaging. The most common location was the frontal lobe (35.4%, 17/48), closely followed by

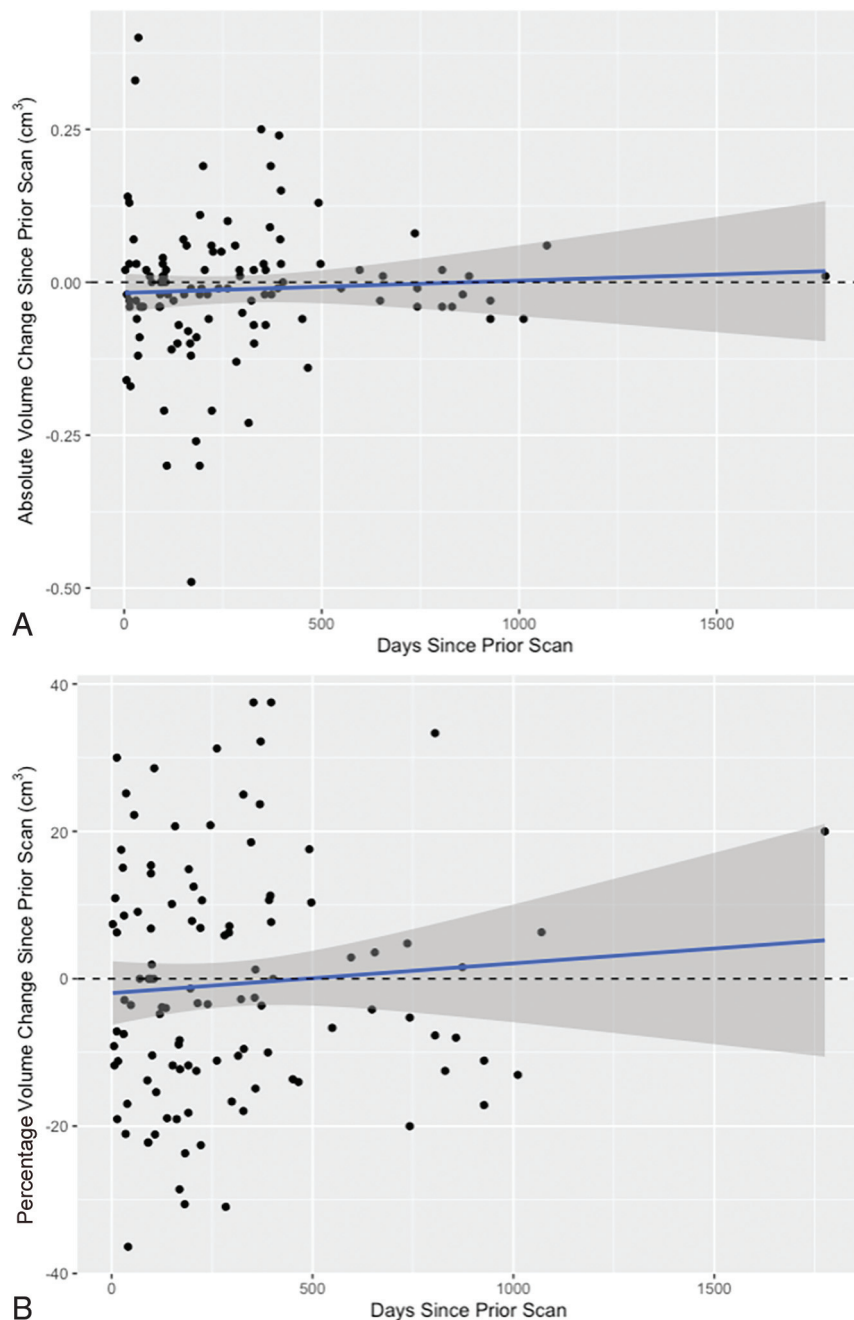


FIG 4. Days since prior scan versus absolute (A) and percentage (B) volume changes since the prior scan across 110 follow-up scans. Note the trendline (blue) with the 95% confidence interval (gray areas).

the parietal lobe (33.3%, 16/48). Other locations were the temporal lobe (10.4%, 5/48), cerebellum (8.3%, 4/48), and occipital lobe (6.3%, 3/48). Three MVNTs were in both the frontal and parietal lobes. No lesion had any mass effect. The most common indications for the original examination were headache (33.3%, 16/48), seizures (10.4%, 5/48), and dizziness (10.4%, 5/48).

All MVNTs were read as stable by the neuroradiologists interpreting the scan. For every follow-up brain MR imaging ($n = 110$) for all subjects ($n = 48$), the MVNTs were manually segmented (Fig 3) and the absolute and percentage changes in volume from the immediately prior scan as well as from the original scan were

calculated. Across all 48 individual patients, the median MVNT volume on the original scan was 0.40 cm^3 (IQR, $0.16\text{--}0.77 \text{ cm}^3$), while the median MVNT volume on the last scan was 0.34 cm^3 (IQR, $0.14\text{--}0.75 \text{ cm}^3$; $P = .94$).

In comparison with the immediately prior scan, the median absolute change in volume across every follow-up scan was -0.02 cm^3 (IQR, $-0.06\text{--}0.02 \text{ cm}^3$), while the median percentage change in volume was -5.0% (IQR, $-13.7\%\text{--}7.9\%$) (Fig 4). Pearson correlation coefficients and P values for the relationship between days since the immediately prior scan versus absolute and percentage changes in volumes from the immediately prior scan were $r = 0.05$, $P = .60$ and $r = 0.07$, $P = .45$ respectively.

In comparison with the original scan, the median absolute change in volume across every follow-up scan was -0.01 cm^3 (IQR, $-0.06\text{--}0.03 \text{ cm}^3$), while the median percentage change in volume was -3.1% (IQR, $-12.3\%\text{--}10.2\%$) (Fig 5). Pearson correlation coefficients and P values for the relationship between days since the first scan versus absolute and percentage changes in volumes from the first scan were $r = -0.06$, $P = .53$, and $r = -0.04$, $P = .67$, respectively.

DISCUSSION

Multiple case series have now suggested the long-term stability of the MVNT based on qualitative evaluation of serial imaging. However, there remain no publicly available guidelines regarding surveillance imaging of a newly diagnosed MVNT. As of 2021, MVNT is officially classified as a WHO grade 1 tumor, which only increases the need for consensus follow-up guidelines to avoid exposing patients to unnecessary imaging examinations and stress regarding

their new diagnosis. We provide quantitative evidence, based on volumetric segmentation across all follow-up examinations of patients with MVNT, that there is no significant change in tumor volume between consecutive examinations or between any individual follow-up examination and the initial examination.

In addition to volumetric stability, our other results agree with the larger retrospective studies in the existing literature, most of which are based on only qualitative assessment. By far, the single most common symptom in our cohort was headache, as in Alsufayan et al⁵ and Nunes et al,⁷ though like those analyses, we also had multiple patients initially imaged for seizures. Although 7

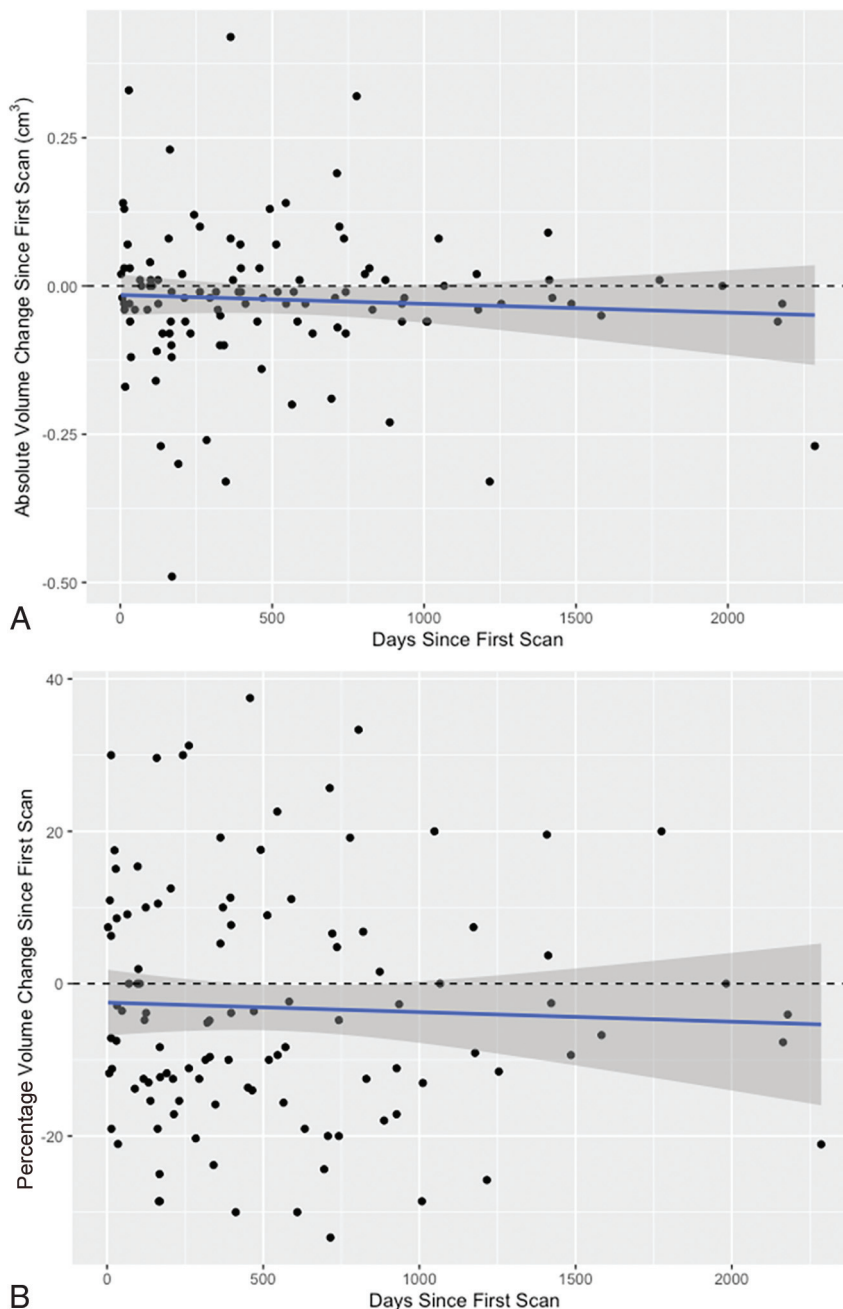


FIG 5. Days since first scan versus absolute (A) and percentage (B) volume changes since the first scan, across 110 follow-up scans. Note the trendline (blue) with the 95% confidence interval (gray areas).

of the initial 10 cases of MVNT were found in the temporal lobes,¹ the literature suggests that these lesions are most commonly found in the frontal and parietal lobes, as in our study.^{5,7,8} MVNT signal characteristics in our cohort also are in consensus with the literature: All of our MVNT cases showed T2 and FLAIR hyperintensity and T1 iso- or hypointensity. None of our lesions demonstrated contrast enhancement, though there are very scant reports of contrast enhancement in existing studies.⁷ Finally, none of our cases showed true restricted diffusion, though most showed T2 shinthrough, highlighting the need to scrutinize ADC maps in these cases.

With respect to surveillance imaging suggestions, because MVNTs themselves are benign and, as we have shown, do not change in volume, follow-up imaging should be targeted to rule out other entities in the differential diagnosis. In the literature, other considered diagnoses most commonly have included DNET,⁵ focal cortical dysplasia, low-grade glioma,⁴ and enlarged perivascular spaces.⁵

Many of these lesions should be distinguishable on a single study alone and do not necessarily merit follow-up solely to differentiate them from an MVNT. Perivascular spaces should not be hyperintense on FLAIR and are typically found in areas of perforator vessels. DNETs are located in the cortex, demonstrate a relatively brighter rim of FLAIR signal, often have calcifications, and present symptomatically with seizures at a young age.¹⁵ Focal cortical dysplasia type IIb often has a characteristic transmantle sign of T2 FLAIR hyperintensity extending linearly between the ventricle and cortex and has cortical thickening not seen in MVNT.¹⁶ Most low-grade gliomas should be distinguishable from MVNT on imaging, but there may be diagnostic confusion in cases of large-sized MVNTs or small gliomas. In this case, differentiating low-grade gliomas from MVNTs even with serial imaging may be difficult or require extensive follow-up because certain subgroups of WHO grade 1 or 2 gliomas show very slow progression across several years. In this specific scenario, consultation with neurosurgery colleagues is appropriate.

For incidentally discovered MVNT, we propose a follow-up MR imaging with contrast at approximately 6 months to 1 year. Further follow-up can be performed with annual MR imaging with-

out contrast for an additional 2–3 years, and, after that, imaging intervals can be increased to 3–5 years based on patient comfort level. Of course, individual clinical circumstances may merit more frequent imaging.

We believe no further contrast is needed after a stable follow-up contrast-enhanced examination. The primary utility of surveillance imaging then becomes recognizing slow increases in size; contrast is unnecessary and introduces needless risk. Although the nephrogenic systemic fibrosis incidence has decreased due to a switch to macrocyclic gadolinium-based contrast agents,¹⁷ there is now increased attention given to gadolinium deposition in the

brain.¹⁸ While studies suggest that macrocyclic agents are less likely to cause noticeable MR imaging changes even in patients with moderate renal dysfunction,¹⁹ postmortem studies show deposition in the brain even with macrocyclic agents.²⁰ Although the clinical significance of gadolinium deposition remains unclear, administering unnecessary contrast should be avoided.

The psychological effects of a delayed diagnosis of benign-versus-malignant tumors should not be underestimated, particularly now that MVNT is officially a WHO grade 1 tumor. Patients with malignant brain tumors are significantly more likely to report posttraumatic stress disorder symptoms than patients with benign tumors.²¹ In women with a breast mass awaiting biopsy, all patients exhibited elevated stress-related biomarkers and anxiety symptoms, but women diagnosed with a benign tumor returned to a normal baseline while women with a malignant diagnosis did not.²² A stable first follow-up scan at 7–12 months should reassure the patient about a benign MVNT diagnosis.

Limitations of our study include the lack of histopathologic confirmation of MVNT cases, because only 2 subjects underwent biopsy. Unfortunately, lack of pathology is a problem common to all large MVNT analyses,^{5,7,8} because the lesions have now been recognized as “touch me not” and, therefore, do not undergo biopsy unless there is considerable doubt regarding the diagnosis. Second, natural limits on the precision of manual segmentation provide another source of error, particularly given the small volume of many of our lesions. For example, an increase from 0.05 to 0.06 cm³ is a 20% increase in volume, but it, more than likely, is within segmentation error. Similarly, differences in scanners may provide heterogeneity across scans of the same lesion, producing small changes affecting segmentation volume. Although our quantitative results align with qualitative observations of other studies, we did not test intra- or interobserver agreement for the manual segmentations. In a similar vein, the single-institution nature of this study is another inherent limitation, and a multi-institution quantitative analysis would add even more strength to our conclusion.

CONCLUSIONS

Volumetric assessment of MVNTs across serial follow-up brain MR imaging examinations did not demonstrate any significant difference in absolute or percentage volume changes from either immediately prior or baseline scans. Uniform recommendations regarding surveillance imaging of newly diagnosed MVNTs are needed, particularly considering the new classification of MVNT as a WHO grade 1 tumor. However, most of these patients with a definitive imaging diagnosis can be reassured of a very benign course, can avoid surgery, and, more important, can be followed up with less frequent imaging. Moreover, MR imaging follow-up studies could skip or avoid gadolinium contrast injections.

Disclosure forms provided by the authors are available with the full text and PDF of this article at www.ajnr.org.

REFERENCES

- Huse JT, Edgar M, Halliday J, et al. **Multinodular and vacuolating neuronal tumors of the cerebrum: 10 cases of a distinctive seizure-associated lesion.** *Brain Pathol* 2013;23:515–24 [CrossRef Medline](#)
- Louis DN, Perry A, Reifenberger G, et al. **The 2016 World Health Organization Classification of Tumors of the Central Nervous System: a summary.** *Acta Neuropathol* 2016;131:803–20 [CrossRef Medline](#)
- Louis DN, Perry A, Wesseling P, et al. **The 2021 WHO Classification of Tumors of the Central Nervous System: a summary.** *Neuro Oncol* 2021;23:1231–51 [CrossRef Medline](#)
- Alizada O, Ayman T, Akgun MY, et al. **Multinodular and vacuolating neuronal tumor of the cerebrum: two cases and review of the literature.** *Clin Neurol Neurosurg* 2020;197:106149 [CrossRef Medline](#)
- Alsufayan R, Alcaide-Leon P, de Tilly LN, et al. **Natural history of lesions with the MR imaging appearance of multinodular and vacuolating neuronal tumor.** *Neuroradiology* 2017;59:873–83 [CrossRef Medline](#)
- Nunes Dias L, Candela-Cantó S, Jou C, et al. **Multinodular and vacuolating neuronal tumor associated with focal cortical dysplasia in a child with refractory epilepsy: a case report and brief review of literature.** *Childs Nerv Syst* 2020;36:1557–61 [CrossRef Medline](#)
- Nunes RH, Hsu CC, da Rocha AJ, et al. **Multinodular and vacuolating neuronal tumor of the cerebrum: a new “leave me alone” lesion with a characteristic imaging pattern.** *AJNR Am J Neuroradiol* 2017;38:1899–904 [CrossRef Medline](#)
- Buffa GB, Chaves H, Serra MM, et al. **Multinodular and vacuolating neuronal tumor of the cerebrum (MVNT): a case series and review of the literature.** *J Neuroradiol* 2020;47:216–20 [CrossRef Medline](#)
- Makrakis D, Veneris S, Papadaki E. **Multinodular and vacuolating neuronal tumor incidentally discovered in a young man: conventional and advanced MRI features.** *Radiol Case Rep* 2018;13:960–64 [CrossRef Medline](#)
- Hongo T, Nakajima H, Kishizaki H, et al. **Multinodular and vacuolating neuronal tumor (MVNT) diagnosed asymptotically by characteristic MRI findings [in Japanese].** *Brain Nerve* 2022;74:817–18 [CrossRef Medline](#)
- Arbujo S, Roster K, Gill A, et al. **Multinodular and vacuolating neuronal tumor: incidental diagnosis of a rare brain lesion.** *Cureus* 2021;13:e20674 [CrossRef Medline](#)
- Lecler A, Broquet V, Bailleux J, et al. **Advanced multiparametric magnetic resonance imaging of multinodular and vacuolating neuronal tumor.** *Eur J Neurol* 2020;27:1561–69 [CrossRef Medline](#)
- Choi E, Kim SI, Won JK, et al. **Clinicopathological and molecular analysis of multinodular and vacuolating neuronal tumors of the cerebrum.** *Hum Pathol* 2019;86:203–12 [CrossRef Medline](#)
- De Wandeler T, De Brucker Y, Jansen A, et al. **Multinodular and vacuolating neuronal tumor of the cerebrum (MVNT): do not touch.** *Acta Neurol Belg* 2020;120:747–48 [CrossRef Medline](#)
- Parmar HA, Hawkins C, Ozelame R, et al. **Fluid-attenuated inversion recovery ring sign as a marker of dysembryoplastic neuroepithelial tumors.** *J Comput Assist Tomogr* 2007;31:348–53 [CrossRef Medline](#)
- Kimura Y, Shioya A, Saito Y, et al. **Radiologic and pathologic features of the transmantle sign in focal cortical dysplasia: the T1 signal is useful for differentiating subtypes.** *AJNR Am J Neuroradiol* 2019;40:1060–66 [CrossRef Medline](#)
- Mathur M, Jones JR, Weinreb JC. **Gadolinium deposition and nephrogenic systemic fibrosis: a radiologist’s primer.** *Radiographics* 2020;40:153–62 [CrossRef Medline](#)
- Radbruch A, Weberling LD, Kieslich PJ, et al. **Gadolinium retention in the dentate nucleus and globus pallidus is dependent on the class of contrast agent.** *Radiology* 2015;275:783–91 [CrossRef Medline](#)
- Dogra S, Borja MJ, Lui YW. **Impact of kidney function on CNS gadolinium deposition in patients receiving repeated doses of gadobutrol.** *AJNR Am J Neuroradiol* 2021;42:824–30 [CrossRef Medline](#)

20. Murata N, Gonzalez-Cuyar LF, Murata K, et al. **Macrocyclic and other non-group 1 gadolinium contrast agents deposit low levels of gadolinium in brain and bone tissue: preliminary results from 9 patients with normal renal function.** *Invest Radiol* 2016;51:447–53 [CrossRef Medline](#)
21. Fehrenbach MK, Brock H, Mehnert-Theuerkauf A, et al. **Psychological distress in intracranial neoplasia: a comparison of patients with benign and malignant brain tumours.** *Front Psychol* 2021;12:664235 [CrossRef Medline](#)
22. Bai LJ, Liu Q, Wang M, et al. **Evaluation of the psychological and biological changes of patients diagnosed with benign and malignant breast tumors.** *Int J Biol Markers* 2012;27:e322v30 [CrossRef Medline](#)