



Discover Generics

Cost-Effective CT & MRI Contrast Agents

**FRESENIUS
KABI**

[WATCH VIDEO](#)

AJNR

High-Resolution T2-Weighted Imaging for Surveillance in Postoperative Vestibular Schwannoma: Equivalence with Contrast-Enhanced T1WI for Measurement and Surveillance of Residual Tumor

This information is current as of June 22, 2025.







S.B. Strauss, S. Stern, J.E. Lantos, E. Lin, J. Shin, P. Yao, S.H. Selesnick and C.D. Phillips

AJNR Am J Neuroradiol 2022, 43 (12) 1792-1796

doi: <https://doi.org/10.3174/ajnr.A7685>

<http://www.ajnr.org/content/43/12/1792>

High-Resolution T2-Weighted Imaging for Surveillance in Postoperative Vestibular Schwannoma: Equivalence with Contrast-Enhanced T1WI for Measurement and Surveillance of Residual Tumor

 S.B. Strauss,  S. Stern,  J.E. Lantos,  E. Lin, J. Shin,  P. Yao, S.H. Selesnick, and  C.D. Phillips

ABSTRACT

BACKGROUND AND PURPOSE: Patients with surgically resected vestibular schwannoma will undergo multiple postoperative surveillance examinations, typically including postcontrast sequences. The purpose of this study was to compare high-resolution T2WI with gadolinium T1WI in the postoperative assessment of vestibular schwannoma.

MATERIALS AND METHODS: This was a retrospective study of patients with a history of resected vestibular schwannoma at a single institution. High-resolution T2WI and gadolinium T1WI were independently evaluated for residual disease. In addition, 3D and 2D measurements were performed in the group of patients with residual tumor. Statistical analysis was performed to evaluate the agreement between sequences on the binary assessment (presence/absence of tumor on initial postoperative examination) and to evaluate the equivalence of measurements for the 2 sequences on 3D and 2D quantitative assessment in individuals with residual disease.

RESULTS: One hundred forty-eight patients with retrosigmoid-approach resection of vestibular schwannomas were included in the final analysis. There was moderate-to-substantial agreement between the 2 sequences for the evaluation of the presence versus absence of tumor (Cohen κ coefficient = 0.78; 95% CI, 0.68–0.88). The 2 sequences were significantly equivalent for 2D and 3D quantitative assessments (short-axis P value = .021; long-axis P value = .015; 3D P value = .039).

CONCLUSIONS: In this retrospective study, we demonstrate moderate-to-substantial agreement in the categoric assessment for the presence versus absence of tumor and equivalence between the 2 sequences for both 2D and volumetric tumor measurements as performed in the subset of patients with measurable residual. On the basis of these results, high-resolution T2WI alone may be sufficient for early postoperative imaging surveillance in this patient population.

ABBREVIATIONS: Gd-T1WI = gadolinium T1-weighted imaging; HR-T2WI = high-resolution T2-weighted MRI; SSFP = steady-state free precession

Vestibular schwannoma is a benign neoplasm (World Health Organization I) arising from Schwann cells enveloping the eighth cranial nerve, usually in the internal auditory canal and cerebellopontine angle, and is the most common benign neoplasm at these locations. The average rate of growth for vestibular schwannoma is 1.2 mm/year,¹ but a subset may progress more rapidly. Management recommendations include observation, stereotactic

radiosurgery, and complete, subtotal, or near-total microsurgical resection.^{2,3} In the postoperative setting, imaging surveillance is necessary for at least 10 years postprocedure,⁴ because reported recurrence/residual rates range from 0.17% to 7.7%, depending, in large part, on the completeness of the initial resection.⁵ Moreover, as subtotal resection strategies have been increasingly applied for the purpose of facial nerve and hearing preservation,³ long-term imaging surveillance has become more integral. In practice, the criterion standard for imaging surveillance remains serial, postoperative, gadolinium T1WI (Gd-T1WI) of the internal auditory canal.⁴ However, there are concerns within the medical and lay literature regarding the use of gadolinium-based contrast, particularly linear and nonionic agents, due to both gadolinium accumulation in brain tissue and the development of nephrogenic systemic fibrosis,^{6–8} particularly in a population undergoing multiple surveillance examinations. Moreover, an abbreviated, noncontrast examination is a more cost-effective approach for posttreatment surveillance.⁹

Received May 9, 2022; accepted after revision September 26.

From the Departments of Radiology (S.B.S., J.E.L., E.L., J.S., C.D.P.) and Otolaryngology-Head and Neck Surgery (S.H.S.), New York Presbyterian/Weill Cornell Medical Center, New York, New York; Department of Otolaryngology, Head and Neck Surgery, (S.S.), Hadassah Medical Center, Hebrew University, Jerusalem, Israel; Weill Cornell Medical College (P.Y.), New York, New York; and Department of Neurological Surgery (S.H.S.), Memorial Sloan Kettering Cancer Center, New York, New York.

Sara Strauss and Sagit Stern contributed equally to this article as co-first authors.

Please address correspondence to C. Douglas Phillips, MD, New York Presbyterian/Weill Cornell Medical Center, 525 East 68th St, New York, NY 10065; e-mail: cdp2001@med.cornell.edu; @CDP_Rad

<http://dx.doi.org/10.3174/ajnr.A7685>

The current recommendations of the American College of Radiology for screening in patients with asymmetric sensorineural hearing loss include both MR imaging of the head and internal auditory canal without and with IV contrast and MR imaging of the head and internal auditory canal without IV contrast, with the latter being an acceptable route when there is a contraindication to contrast administration. There are no existing American College of Radiology recommendations regarding imaging surveillance in the postoperative setting in patients with vestibular schwannoma; however, contrast-enhanced sequences are typically included.^{10,11} Prior studies have demonstrated the accuracy¹²⁻¹⁴ and cost effectiveness^{9,15,16} of T2WI steady-state free precession (SSFP) alone, without contrast-enhanced T1WI, for vestibular schwannoma screening in patients presenting with asymmetric sensorineural hearing loss. Studies have also shown noncontrast T2WI to be accurate in the detection of interval growth in patients with known, surgically-naïve vestibular schwannoma.^{17,18} To our knowledge, no studies exist examining the use of noncontrast T2WI for postoperative surveillance.

Steady-state sequences (eg, CISS, driven equilibrium radiofrequency reset pulse [DRIVE], and FIESTA-C) confers high spatial resolution using both T2 and T1 contrast, allowing excellent distinction between CSF and adjacent soft tissue, thereby optimizing tumor conspicuity above standard T2-weighted sequences. The purpose of this study was to compare high-resolution T2-weighted MR imaging (HR-T2WI) with Gd T1WI in the postoperative assessment of vestibular schwannoma. We hypothesized that HR-T2WI will be equivalent to contrast-enhanced T1WI in the postoperative surveillance of vestibular schwannoma. This equivalence might ultimately present a cost- and time-effective option to a population undergoing long-term imaging surveillance.

MATERIALS AND METHODS

Patient Selection

This was a Weill Cornell Medicine institutional review board-approved, Health Insurance Portability and Accountability Act-compliant retrospective study of patients with a history of vestibular schwannoma who had undergone surgical resection and postoperative surveillance imaging. Adult patients 18 years of age and older with a history of vestibular schwannoma treated with surgical management between September 1, 2007, and April 17, 2018, with an examination performed within 1 year after surgery were eligible for inclusion in the study. Subjects were excluded if postoperative imaging was not available on the PACS (ie, performed at an outside institution and not uploaded to the hospital's systems), if examinations were nondiagnostic due to motion degradation or other technical factors, or if either SSFP and postcontrast T1WI was not performed. Basic demographic information (age and sex at birth) was documented.

Imaging Acquisition and Postprocessing

For each subject, Gd-T1WI and HR-T2WI were performed. Gd-T1WI studies were performed on GE Healthcare (1.5T, 3T) and Siemens (1.5T, 3T) scanners (TR = 354–973 ms, TE = 7.5–22.02 ms, percentage of phase FOV = 75%–100%, number of excitations = 0.5–3, matrix = 256 × 168–320 × 256). HR-T2WI studies were performed on GE Healthcare (GE LX Excited HDxt 1.5T,

Signa Architect 3T) and Siemens (Aera 1.5T, Skyra 3T, Biograph MMR 3T) scanners (TR = 5.08–9570 ms, TE = 1.7–269 ms, percentage of phase FOV = 75%–100%, number of excitations = 0.6–7, matrix = 256 × 128–512 × 312). N4 bias field correction was applied to images to remove low-frequency intensity and nonuniformity. High-resolution T2-weighted images were compared with and, when applicable, resampled to match the contrast-enhanced T1-weighted image voxel size, to mitigate section-selection bias. Gd-T1WI and resampled HR-T2WI were segmented using a combination of manual contouring and signal-intensity thresholding.

Imaging Assessment

Two coauthors (J.E.L. and E.L.), both Certificate of Added Qualification-certified neuroradiologists with 10 years of imaging experience, reviewed Gd-T1WI and HR-T2WI sequences from 1-year postoperative examinations and classified subjects according to the presence or absence of residual tumor (dichotomous) on each of the 2 sequences during separate sessions, blinded to the original radiology report. In addition, 3D and 2D (short- and long-axis) measurements were performed on the group of patients determined to have residual tumor on the basis of the 1-year radiology report. A team of 4 technologists were trained in identification and segmentation of tumor volume by 3 of the authors (J.S., S.B.S., C.D.P.) for HR-T2WI and Gd-T1WI separately using the Segment Editor Module in 3D Slicer (<http://www.slicer.org>). After the initial segmentation, tumor volumes were reviewed by 2 coauthors (S.B.S., S.S.) for accuracy (correct tumor identification and appropriate exclusion of postoperative changes) and edited as necessary. Long- and short-axis measurements were performed by 2 neuroradiologists (J.E.L. and E.L.) on HR-T2WI and Gd-T1WI separately using 3D Slicer; the maximal long-axis axial measurement was identified and measured, and the short-axis measurement, designated as perpendicular to the long-axis, was thereby defined.

Statistical Analysis

Statistical analysis was performed in R Version 4.0.2 (<http://www.r-project.org/>) and NCSS 2020, (Version 20.0.7; <https://www.ncss.com/download/ncss/updates/ncss-2020/>). The Cohen κ coefficient for agreement between sequences was calculated for binary assessment (presence versus absence of tumor on the first postoperative examination). The Wilcoxon signed-rank test for equivalence was performed as a test for equivalence between Gd-T1WI and HR-T2WI for the 2D data, given that the data were not normally distributed, with an equivalence margin of 1.5 mm for short-axis measurements and 4.5 for long-axis measurements. Paired tests for equivalence (TOST; <https://gist.github.com/josefpkt/3900314>) were performed to test for equivalence between Gd-T1WI and HR-T2WI for the volumetric measurements, given that these were normally distributed, with an equivalence margin of 20 mm³. A paired-sample *t* test was performed to determine the significance of the difference in change with time based on HR-T2WI and Gd-T1WI using both 3D and 2D measurements.

RESULTS

Patient Characteristics

One hundred eighty-four patients were initially identified on the basis of chart review, of whom 36 were excluded due to the

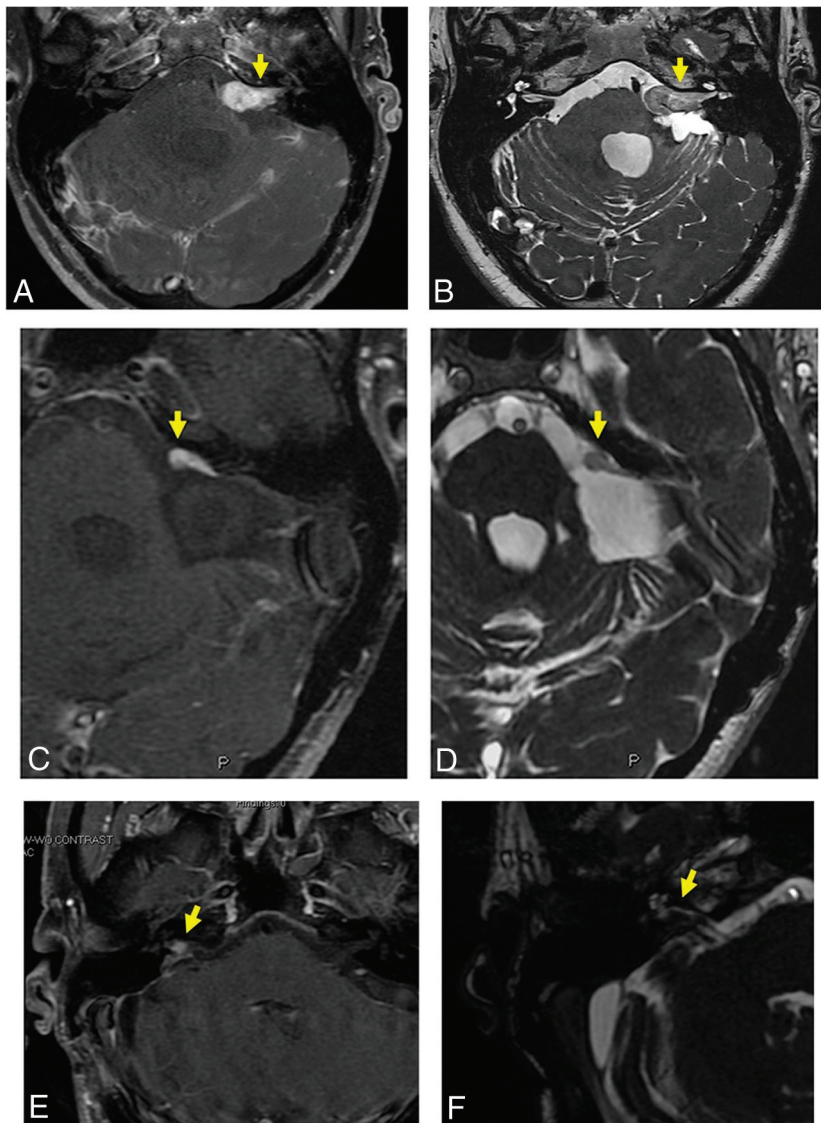


FIGURE. A and B, A 66-year-old-man with a history of retrosigmoid-approach resection of a left vestibular schwannoma. Axial Gd-T1WI (A) and HR-T2WI (B) demonstrate postprocedural changes, including encephalomalacia and gliosis in the left brachium pontis and lateral cerebellar hemisphere. A large-volume tumor is detectable on both the Gd-T1WI and HR-T2WI, as indicated by the yellow arrow. C and D, A 51-year-old woman with a history of retrosigmoid-approach resection of a left vestibular schwannoma. Axial Gd-T1WI (C) and HR-T2WI (D) demonstrate residual disease within the left cerebellopontine angle cistern, detectable on both Gd-T1WI and HR-T2WI, as indicated by the yellow arrow. E and F, A 60-year-old man with a history of retrosigmoid-approach resection of a right vestibular schwannoma. Axial Gd-T1WI (E) and HR-T2WI (F) demonstrate residual disease in the right internal auditory canal, as indicated by the yellow arrow.

aforementioned study criteria. One hundred forty-eight patients consisting of 75 men and 73 women with mean age of 48.9 years (range, 13–78 years) were included in the study. The average time interval between tumor resection and postoperative examination was 595 days (range, 51–2254 days). None of the included patients had a diagnosis of type 2 neurofibromatosis, and all subjects underwent surgical resection via a retrosigmoid approach.

Binary Assessment

At 1 year after the operation, 93 patients were classified as having residual tumor on the basis of HR-T2WI alone, and 90 patients

were classified as having residual tumor on the basis of Gd-T1WI alone. The Cohen κ coefficient for agreement (presence versus absence of tumor) between the 2 sequences was 0.78 (95% CI, 0.68–0.88), indicating moderate-to-substantial agreement. The Figure shows examples of patients with prior vestibular schwannoma resection and representative Gd-T1WI and HR-T2WI demonstrating residual/recurrent disease.

2D Assessment

Long- and short-axis measurements were performed in 81 subjects with residual tumor on the basis of the radiology report from the early postoperative examination performed at 1 year post-surgery. Measurements were performed for the Gd-T1WI and HR-T2WI, separately. The mean short-axis measurement was 7.3 mm (range, 1.3–24.5 mm) on HR-T2WI and 7.3 mm (range, 1.2–24.3 mm) on Gd-T1WI. The mean long-axis measurement was 13.0 mm (range, 2.3–34.8 mm) on SSFP and 13.3 mm (range, 2.2–35.9) on postcontrast T1WI. The Wilcoxon signed-rank test for equivalence using TOST showed that the short-axis measurements for the 2 sequences were significantly equivalent ($P = .021$) and the long-axis measurements for the 2 sequences were significantly equivalent ($P = .015$).

Volumetric Assessment

Volumetric calculation was performed in the 81 subjects with residual tumor on the early postoperative examination performed at 1 year postsurgery. Tumor was segmented using the Segmentation Editor Module in 3D Slicer 4.10.2, and tumor volumes (cubic millimeters) were extracted. The mean tumor volume was 1096.7 mm³ (range, 19.7–11,502.1 mm³)

on HR-T2WI and 1106.0 mm³ (range, 24.1–11,578.5 mm³) on Gd-T1WI. The paired t test for equivalence using TOST showed that the 2 sequences were significantly equivalent ($P = .039$).

Change with Time

Of the 81 subjects with residual tumor on the early postoperative examination performed at 1 year postsurgery, residual disease was measured on a single subsequent follow-up examination in 39 subjects. The mean time interval between the 2 postoperative examinations was 865.6 days (range, 75–2720 days). The mean tumor growth with time was 265.7 mm³ (3D: range, 0–1802.16 mm³),

1.3 mm (long-axis: range, 0.1–5.8 mm), and 1.1 mm (short-axis: range, 0–6 mm) on HR-T2WI and 247.6 mm³ (3D: range, 0–1897.45 mm³), 1.3 mm (long-axis: range, 0–7.3 mm), and 1.2 mm (short-axis: range, 0–4.4 mm) on Gd-T1WI, measured in this group of patients. The paired-sample *t* test demonstrated no significant difference between HR-T2WI and Gd-T1WI in measured change with time for the 3D (*P* = .264), short-axis (*P* = .521), and long-axis (*P* = .362) measurements.

DISCUSSION

Imaging evaluation of the postoperative vestibular schwannoma is more complex as compared to untreated vestibular schwannoma, as postsurgical changes such as scar tissue formation and anatomic distortion can make evaluation for residual or recurrent disease more difficult. This study demonstrates that HR-T2WI is equivalent to Gd-T1WI in the evaluation of residual vestibular schwannoma in patients with prior tumor resection. We demonstrate moderate-to-substantial agreement in the categorical assessment for the presence versus absence of tumor and equivalence between the 2 sequences for both 2D and volumetric tumor measurements. On the basis of these results, HR-T2WI alone may be sufficient for early imaging surveillance in this patient population.

These findings are consistent with those of previous studies in patients with surgically-naïve vestibular schwannoma. For instance, Buch et al¹⁹ found no significant difference in the measurement of vestibular schwannoma performed on Gd-T1WI and HR-T2WI. In a meta-analysis including 10 studies, Kim et al¹⁸ found that T2WI was as accurate as Gd-T1WI in tumor and showed high inter- and intrarater agreement for HR-T2WI measurements. The current study demonstrates similar findings in a large sample of postoperative vestibular schwannomas.

We chose to study both 3D assessment in addition to 2D assessment. Volumetric analysis has been shown to detect changes in tumor size earlier than linear assessment alone and is more sensitive to the detection of growth in the craniocaudal dimension, growth of multilobulated tumor, and growth difficult to detect because of differences in the scan angle between examinations.²⁰ We found both measurement approaches to be statistically equivalent between the HR-T2WI and Gd-T1WI examinations. Future studies exploring automated approaches to 3D segmentation on the basis of HR-T2WI might further improve the efficiency of examination performance and interpretation.

There are several limitations to this study. First, the patient sample was derived from a single institution and neurotology practice; therefore, a more diverse sample would be required to increase generalizability. All subjects in this study underwent resection via a retrosigmoid approach; thus, it is conceivable that HR-T2WI alone might be less effective in subjects with resection via middle cranial fossa (with a potentially larger cerebellopontine angle residual) or translabrynthine (in which the postoperative examination is further complicated by placement of fat graft material) approaches. Additionally, we did not specifically explore potential factors such as cystic vestibular schwannoma, the presence of hemosiderin deposition, or a purely intrameatal remnant in the successful detection of residual on the noncontrast HR-T2WI examination.

In this study, evaluation for the presence versus absence of residual tumor was performed by highly experienced neuroradiologists, and external validation by less-experienced readers might yield worse results. Finally, the average time interval between the operation and the initial postoperative imaging examination was 1.6 years; however, imaging surveillance typically continues until at least 10 years postsurgery. Thus, additional longitudinal imaging demonstrating equivalence between HR-T2WI and Gd-T1WI is warranted to support the abbreviated noncontrast examination at longer-interval follow-up.

CONCLUSIONS

In this retrospective study, we demonstrate HR-T2WI to be equivalent to Gd-T1WI in the evaluation of residual vestibular schwannoma in patients with prior tumor resection. These findings suggest that HR-T2WI alone may be sufficient for early imaging surveillance in this patient population, thereby reducing examination time and obviating need for multiple contrast doses with time.

Disclosure forms provided by the authors are available with the full text and PDF of this article at www.ajnr.org.

REFERENCES

1. Yoshimoto Y. **Systematic review of the natural history of vestibular schwannoma.** *J Neurosurg* 2005;103:59–63 [CrossRef Medline](#)
2. Chen Z, Prasad SC, Di Lella F, et al. **The behavior of residual tumors and facial nerve outcomes after incomplete excision of vestibular schwannomas.** *J Neurosurg* 2014;120:1278–87 [CrossRef Medline](#)
3. Tang S, Griffin AS, Waksal JA, et al. **Surveillance after resection of vestibular schwannoma: measurement techniques and predictors of growth.** *Otol Neurotol* 2014;35:1271–76 [CrossRef Medline](#)
4. Miller ME, Lin H, Mastrodimos B, et al. **Long-term MRI surveillance after microsurgery for vestibular schwannoma.** *Laryngoscope* 2017;127:2132–38 [CrossRef Medline](#)
5. Ahmad RARL, Sivalingam S, Topsakal V, et al. **Rate of recurrent vestibular schwannoma after total removal via different surgical approaches.** *Ann Otol Rhinol Laryngol* 2012;121:156–61 [CrossRef Medline](#)
6. Mathur M, Jones JR, Weinreb JC. **Gadolinium deposition and nephrogenic systemic fibrosis: a radiologist's primer.** *Radiographics* 2020;40:153–62 [CrossRef Medline](#)
7. Robert P, Fingerhut S, Factor C, et al. **One-year retention of gadolinium in the brain: comparison of gadodiamide and gadoterate meglumine in a rodent model.** *Radiology* 2018;288:424–33 [CrossRef Medline](#)
8. Radbruch A, Weberling LD, Kieslich PJ, et al. **Gadolinium retention in the dentate nucleus and globus pallidus is dependent on the class of contrast agent.** *Radiology* 2015;275:783–91 [CrossRef Medline](#)
9. Crowson MG, Rocke DJ, Hoang JK, et al. **Cost-effectiveness analysis of a non-contrast screening MRI protocol for vestibular schwannoma in patients with asymmetric sensorineural hearing loss.** *Neuroradiology* 2017;59:727–36 [CrossRef Medline](#)
10. Dunn IF, Bi WL, Mukundan S, et al. **Congress of Neurological Surgeons systematic review and evidence-based guidelines on the role of imaging in the diagnosis and management of patients with vestibular schwannomas.** *Neurosurgery* 2018;82:E32–34 [CrossRef Medline](#)
11. Dang L, Tu NC-Y, Chan EY. **Current imaging tools for vestibular schwannoma.** *Curr Opin Otolaryngol Head Neck Surg* 2020;28:302–07 [CrossRef Medline](#)
12. Schmalbrock P, Chakeres DW, Monroe JW, et al. **Assessment of internal auditory canal tumors: a comparison of contrast-enhanced T1-**

- weighted and steady-state T2-weighted gradient-echo MR imaging. *AJNR Am J Neuroradiol* 1999;20:1207–13 [Medline](#)
13. Annesley-Williams D, Laitt R, Jenkins J, et al. Magnetic resonance imaging in the investigation of sensorineural hearing loss: is contrast enhancement still necessary? *J Laryngol Otol* 2001;115:14–21 [CrossRef Medline](#)
 14. Fukui MB, Weissman JL, Curtin HD, et al. T2-weighted MR characteristics of internal auditory canal masses. *AJNR Am J Neuroradiol* 1996;17:1211–18 [Medline](#)
 15. Shelton C, Harnsberger HR, Allen R, et al. Fast spin echo magnetic resonance imaging: clinical application in screening for acoustic neuroma. *Otolaryngol Head Neck Surg* 1996;114:71–76 [CrossRef Medline](#)
 16. Verret D, Adelson RT, Defatta RJ. Asymmetric sensorineural hearing loss evaluation with T2 FSE-MRI in a public hospital. *Acta Otolaryngol* 2006;126:705–07 [CrossRef Medline](#)
 17. Currie S, Saunders D, Macmullen-Price J, et al. Should we be moving to a national standardized non-gadolinium MR imaging protocol for the surveillance of vestibular schwannomas? *Br J Radiol* 2019;92:20180833 [CrossRef Medline](#)
 18. Kim DH, Lee S, Hwang SH. Non-contrast magnetic resonance imaging for diagnosis and monitoring of vestibular schwannomas: a systematic review and meta-analysis. *Otol Neurotol* 2019;40:1126–33 [CrossRef Medline](#)
 19. Buch K, Juliano A, Stankovic KM, et al. Noncontrast vestibular schwannoma surveillance imaging including an MR cisternographic sequence: is there a need for postcontrast imaging? *J Neurosurg* 2018;131:549–54 [CrossRef Medline](#)
 20. Lees KA, Tombers NM, Link MJ, et al. Natural history of sporadic vestibular schwannoma: a volumetric study of tumor growth. *Otolaryngol Head Neck Surg* 2018;159:535–42 [CrossRef Medline](#)