



## Discover Generics

Cost-Effective CT & MRI Contrast Agents



WATCH VIDEO

# AJNR

### **Detection and quantitation of intermittent CSF rhinorrhea during prolonged cisternography with $^{111}\text{In}$ -DTPA.**

D Glaubitt, J Haubrich and M Cordoni-Voutsas

*AJNR Am J Neuroradiol* 1983, 4 (3) 560-563

<http://www.ajnr.org/content/4/3/560>

This information is current as of June 23, 2025.

# Detection and Quantitation of Intermittent CSF Rhinorrhea during Prolonged Cisternography with $^{111}\text{In}$ -DTPA

Dieter Glaubitt,<sup>1</sup> Jörg Haubrich,<sup>2</sup> and Maria Cordoni-Voutsas<sup>1</sup>

In an attempt to improve the diagnosis and to assess the intensity of intermittent cerebrospinal fluid rhinorrhea, indium-111 uptake by nasal pledgets during prolonged cisternography using  $^{111}\text{In}$ -DTPA was determined. In 12 patients having suspected cerebrospinal fluid rhinorrhea, cisternograms with calculation of counts/pixel in regions of interest were obtained, blood samples drawn, and nasal pledgets placed several times during 48 or 72 hr after lumbar intrathecal administration of  $^{111}\text{In}$ -DTPA. In three patients intermittent cerebrospinal fluid rhinorrhea was thus revealed; study by computed tomography was negative in each case. This procedure of extended radionuclide cisternography helped to detect, localize, and quantify intermittent cerebrospinal fluid rhinorrhea so that therapeutic decisions were facilitated and surgical intervention was minimized.

Cerebrospinal fluid (CSF) rhinorrhea may be caused by a fistula from the intracranial subarachnoid space into the nasal cavity or a paranasal sinus. Traversing the dura and skull, such a fistula breaches the anterior cranial fossa, predominantly in the area of the cribriform plate and ethmoid air cells, less frequently a frontal sinus. CSF rhinorrhea is rare and in most cases occurs posttraumatically, sometimes resolving spontaneously within several days to months [1]. Continuous or distinct intermittent CSF leakage may pose considerable diagnostic problems. As dural fistulae, especially those of traumatic etiology, may be complicated by meningitis, their early detection is mandatory in order to decide whether surgical treatment will be necessary. In patients with intermittent CSF rhinorrhea, radionuclide cisternography [2-4] sometimes misses small leaks if limited to short-term observations. Transmission computed tomography (CT) does not always offer substantial diagnostic help [5]. In an attempt to improve the diagnosis of intermittent CSF rhinorrhea, we determined the uptake of  $^{111}\text{In}$  by nasal pledgets in comparison with the serum level of  $^{111}\text{In}$  [6] during extended cisternography using  $^{111}\text{In}$ -DTPA and lasting 48 or 72 hr.

## Subjects and Methods

The study comprised 12 patients aged 18-55 years who were suspected of having CSF leakage. After lumbar intrathecal injection of 18.5 MBq  $^{111}\text{In}$ -DTPA in a sterile, pyrogen-free, isotonic solution (specific radioactivity 370 MBq/mg DTPA; Byk-Mallinckrodt, Dietzenbach, W. Germany), cisternography was performed in anterior, right lateral, left lateral, and posterior views. The patient was kept recumbent prior to the first scintigram but sat upright with the head

bent forward during imaging [7]. We did not attempt to promote the migration of radioindium from the lumbar site of injection of  $^{111}\text{In}$ -DTPA to the cerebral CSF spaces by using unphysiologic maneuvers because we feared that spontaneous healing of dural fistulae might be disturbed. After about 3, 6, 24, 48, and in some patients 72 hr, scintigrams were obtained with a scintillation camera ON Sigma 410 equipped with a video image processor VIP-450 (Technicare GmbH, Wiesbaden, W. Germany), and a system to produce colored scintigrams (Sicograph; Siemens AG, Erlangen, W. Ger-

TABLE 1: Case 1: Intermittent CSF Leaks Shown by  $^{111}\text{In}$  in Nasal Pledgets and Serum after Lumbar Intrathecal Injection

Time (hr)	$^{111}\text{In}$ (cpm)		
	Nasal Pledgets		Serum
	Right Nostril	Left Nostril	
0-4	403	2	...
4-8	13,865	5	208
22-26	245	1	...
26-30	3,543	1	24
46-50	13	3	...
50-54	838	2	5

TABLE 2: Case 2: Localization of Intermittent CSF Leak by  $^{111}\text{In}$  in Nasal Pledgets and Serum after Intrathecal Injection

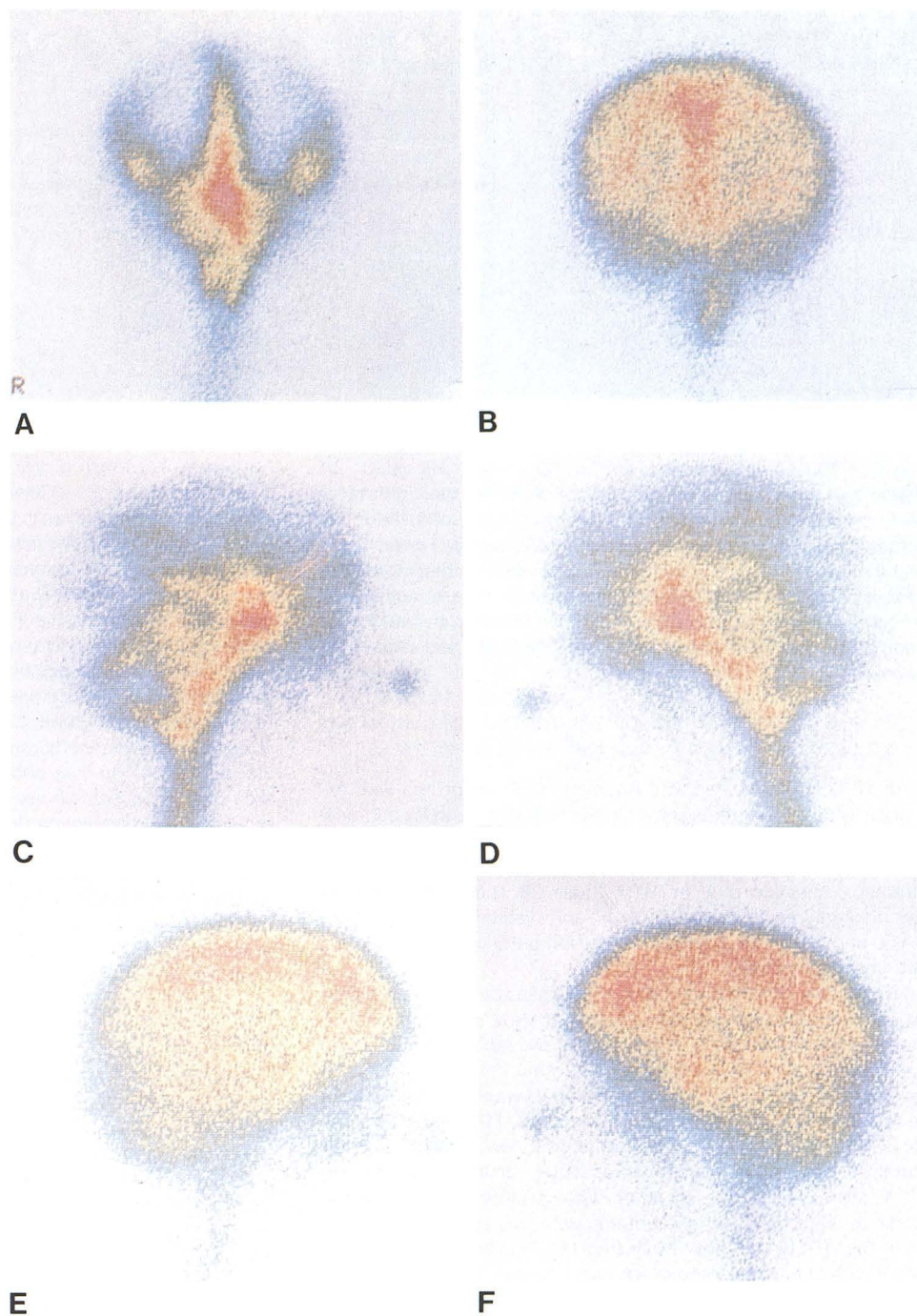
Time (hr)	<sup>111</sup> In (cpm)		
	Nasal Pledgets		Serum
	Right Nostril	Left Nostril	
First cisternogram:			
0-4	26	20	2,079
4-8	1,105	75,205	1,206
22-26	219	6,540	...
26-30	47	16,047	224
46-50	33	2,246	...
50-54	42	2,322	113
Second cisternogram:			
0-4	164	27	2,380
4-8	47,540	83,592	2,180
22-26	2,549	27,357	...
26-30	116	72,970	392
46-50	216	1,070	...
50-54	24	8,250	163

<sup>1</sup>Department of Nuclear Medicine, Academic Teaching Hospital, D-4150 Krefeld, West Germany. Address reprint requests to D. Glaubitt.

<sup>2</sup>Department of Otorhinolaryngology, Academic Teaching Hospital, D-4150 Krefeld, West Germany.



Fig. 1.—Case 2. Radionuclide cisternogram faintly demonstrates and localizes CSF rhinorrhea. Anterior views after 5.5 (A) and 29 (B) hr show excess nasal cavity activity. Right (C and E) and left (D and F) hr lateral views after 6 (C), 6.5 (D), 29.5 (E), and 30 (F) hr show nasal tip activity.



many). When possible, 500,000 counts were collected for each scintigram. Scintigrams were quantified by calculating counts/pixel within the regions of interest allocated to noteworthy areas. Cellulose pledgets with an absorbent capacity of about 2.0 ml water were placed into each nostril for 4 hr twice daily and blood samples were drawn immediately after removal of the pledgets. The radioactivity of the nasal pledgets was compared with aliquots of 2.0 ml of serum using a well scintillation counter.

## Results

Three of 12 patients had CSF rhinorrhea, which varied considerably and was discovered only by extended observation. In two of

these patients a dural fistula was disclosed. Transmission CT was negative in each case.

## Case Reports

### Case 1

A 22-year-old man with recurrent traumatic CSF rhinorrhea had suffered from meningococcal meningitis five times and underwent surgical closure of a dural fistula into the right nasal cavity 3 years before. Intermittent CSF leakage was suspected. Radionuclide cisternography supplemented by determination of radioindium in nasal



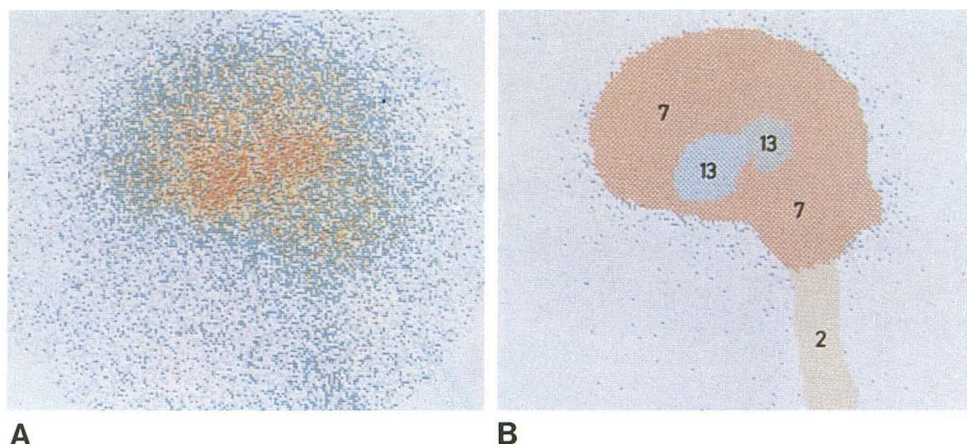


Fig. 2.—Case 3. Quantitative cisternography fails to confirm clinical suspicion of CSF rhinorrhea. Radionuclide cisternogram in left lateral view after 22 hr. A, Without quantitation. Suggestive left ventricle concentration. B, Quantitation stating counts/pixel within four regions of interest does not support hyperconcentration.

pledgets revealed great changes of CSF flow into the right nasal cavity from a CSF leak in the right cribriform plate or in the right frontal sinus. The  $^{111}\text{In}$  concentration of the pledget in the right nostril reached the maximum during 4–8 hr after lumbar intrathecal administration of  $^{111}\text{In}$ -DTPA, fell steeply, and rose transiently at 26–30 and 50–54 hr (table 1). With these findings a dural fistula leading into the right nasal cavity was detected and closed by surgery.

#### Case 2

An 18-year-old woman with traumatic CSF rhinorrhea was examined twice by cisternography. On her first admission for bacterial meningitis, a CSF leakage into the left nasal cavity was detected by an extremely high  $^{111}\text{In}$  level in the nasal pledget 4–8 hr after lumbar intrathecal injection of  $^{111}\text{In}$ -DTPA (table 2). The pledget activity was markedly elevated at 26–30 hr and distinctly augmented at 46–50 and 50–54 hr. A fistula into the left anterior cribriform plate was closed surgically.

Five months later recurrent CSF rhinorrhea was suspected. During radionuclide cisternography in anterior view, more radioindium than was imaged normally in the area of the left nasal cavity was found after 5.5 hr (fig. 1A) as well as after 29 hr (fig. 1B). An accumulation of  $^{111}\text{In}$  at the tip of the nose was detected in right lateral view (fig. 1C) and left lateral view (fig. 1D) on the first day and with a smaller intensity in right lateral view (fig. 1E) and left lateral view (fig. 1F) on the second day after administration of  $^{111}\text{In}$ -DTPA. Moreover, in the left lateral view a moderate radioindium uptake in the region of the cribriform plate was recognizable after 6.5 hr (fig. 1D) but not after 30 hr (fig. 1F). This finding backed the assumption of a fistula into the left nasal cavity.

The comparative determination of the  $^{111}\text{In}$  concentration of nasal pledgets and serum aliquots demonstrated a marked, almost continuous CSF leakage (with the exception of the first 4 hr) into the left nasal cavity (table 2). The radioindium accumulation by the pledgets in the left nostril was highest at 4–8 hr, fell distinctly afterward, and transiently rose strongly at 26–30 hr, and moderately at 50–54 hr. In addition, during the first day an intermittent CSF rhinorrhea into the right nasal cavity was disclosed. The patient is to undergo surgical treatment again.

#### Case 3

A 69-year-old man had traumatic lesions of the skull and brain, and a CSF leakage was suspected. Transmission CT rendered no

information about the existence of a dural fistula. Owing to a low radioindium accumulation in the cisterns, ventricles, and intracranial subarachnoid space, the cisternograms did not delineate anatomic details appropriately; another examination after suboccipital injection [5, 8] of  $^{111}\text{In}$ -DTPA was not acceptable. Therefore the scintigrams obtained during the first and second day after administration of the radiopharmaceutical were quantified.

On the first day the number of counts in six regions of interest in the anterior and posterior views did not show parasagittal radioactivity during the cerebral convexity flow of CSF [9, 10] and the radiotracer movement did not display a side difference or an irregular ascent of  $^{111}\text{In}$  over both cerebral convexities. After 22 hr the area of the left ventricle seemed to present a moderately elevated radioindium accumulation (fig. 2A), but, after quantification of this scintigram in left lateral view (fig. 2B), the suspicion decreased that there might be a slight communicating hydrocephalus. The comparative determination of the radioindium level of nasal pledgets and serum aliquots did not reveal a CSF leakage. Follow-up studies are necessary. With current information, CSF leakage has not been demonstrated in this patient.

#### Discussion

Prolonged cisternography using  $^{111}\text{In}$ -DTPA, combined with the measurement of  $^{111}\text{In}$  in nasal pledgets compared with serum, may disclose, localize, and assess the intensity of CSF rhinorrhea, especially if it occurs transiently. As short-time examinations may miss temporary CSF leakage, the low half-life of  $^{99\text{m}}\text{Tc}$  (6.04 hr) in  $^{99\text{m}}\text{Tc}$ -DTPA obviated the use of this radiopharmaceutical. In experimental studies,  $^{97}\text{Ru}$ -DTPA presented good imaging qualities for cisternography and in identical activities exerted only about one-half of the radiation dose as did  $^{111}\text{In}$ -DTPA [11] so that it might replace  $^{111}\text{In}$ -DTPA later as an agent for cisternography. At present, however,  $^{111}\text{In}$ -DTPA appears to be the most suitable radiopharmaceutical for prolonged radionuclide cisternography [12]; its half-life of 2.81 days is sufficiently long for this type of investigation.

There is disagreement regarding the extent to which the passage of radioindium through the CSF spaces during cisternography with  $^{111}\text{In}$ -DTPA directly reflects the circulation of CSF. The kinetics of  $^{111}\text{In}$  in the cisterns, ventricles, and subarachnoid space were defined in humans [13, 14], and an eight-compartment model was described [14]. We did not observe a hyperdynamic movement of radioindium during cisternography [15].

The diagnostic role of water-soluble contrast media such as metrizamide during transmission CT remains to be compared with radionuclide cisternography, especially in patients with intermittent



CSF rhinorrhea. Single-photon emission CT and positron emission tomography are also potentially useful, although the clinical efficacy of both methods has to be corroborated for prolonged cisternography.

To conclude, extended radionuclide cisternography may be useful in patients with intermittent CSF rhinorrhea. It may reveal a CSF leakage as well as providing information about variations in CSF rhinorrhea that occur within several hours. Thus, therapeutic decisions are facilitated, especially surgical treatment, which is based in part on the extent of CSF leakage. In three patients the intensity of intermittent CSF rhinorrhea was appropriately assessed only by this procedure. Further, the procedure causes only negligible discomfort; adverse reactions to  $^{111}\text{In}$ -DTPA were not observed.

#### REFERENCES

- Collins WF Jr. Dural fistulae and their repair. In: Youmans JR, ed. *Neurological surgery*, vol 2. Philadelphia: Saunders, 1973:981-992
- DiChiro G, Reames PM, Matthews WB Jr. RISA-ventriculography and RISA-cisternography. *Neurology* (NY) 1964;14:185-191
- Ommaya AK, DiChiro G, Baldwin M, Pennybacker JB. Non-traumatic cerebrospinal fluid rhinorrhoea. *J Neurol Neurosurg Psychiatry* 1968;31:214-225
- DiChiro G, Reames PM. Isotope localization of cranionasal cerebrospinal fluid leaks. *J Nucl Med* 1964;5:376
- Glaubitt D, Reckel K, Zachariah S. Radionuclide cisternography and computed tomography in the assessment of impaired cerebrospinal fluid circulation. In: Schmidt HAE, Woldring M, eds. *Nuclearmedizin. State of the art and future*. Stuttgart: Schattauer, 1978:851-858
- McKusick KA, Malmud LS, Kordela PA, Wagner HN Jr. Radionuclide cisternography: normal values for nasal secretion of intrathecally injected  $^{111}\text{In}$ -DTPA. *J Nucl Med* 1973;14:933-934
- Ashburn WL, Harbert JC, Briner WH, DiChiro G. Cerebrospinal fluid rhinorrhea studied with the gamma scintillation camera. *J Nucl Med* 1968;9:523-529
- Oberson R. Radioisotopic diagnosis of rhinorrhea. *Radiol Clin* (Basel) 1972;41:28-35
- Gado M, Coleman RE, Alderson PO. Clinical comparison of radionuclide brain imaging and computerized transmission tomography. I. In: DeBlanc HJ Jr, Sorenson JA, eds. *Noninvasive brain imaging: computed tomography and radionuclides*. New York: Society of Nuclear Medicine, 1975:147-171
- James AE Jr, New PFJ, Heinz ER, Hodges FJ, DeLand FH. A cisternographic classification of hydrocephalus. *AJR* 1972;115:39-49
- Oster ZH, Som P, Gil MC, et al. Ruthenium-97 DTPA: a new radiopharmaceutical for cisternography. *J Nucl Med* 1981;22:269-273
- Hosain F, Som P. Chelated  $^{111}\text{In}$ : an ideal radiopharmaceutical for cisternography. *Br J Radiol* 1972;45:677-679
- Schossberger PF, Touya JJ. Dynamic cisternography in normal dogs and in human beings. *Neurology* (NY) 1976;26:254-260
- Partain CL, Wu HP, Staab EV, Johnston RE. A multiregional kinetics model for cerebrospinal fluid. *Radiology* 1978;127:705-711
- Bladwin RD, Gouldin JA, Spencer RP. Hyperdynamic radionuclide cerebrospinal fluid study. *Clin Nucl Med* 1982;7:82