

Generic Contrast Agents

Our portfolio is growing to serve you better. Now you have a *choice*.



FRESENIUS
KABI

[VIEW CATALOG](#)

AJNR

False-positive CT gas cisternogram.

H J Robertson, H P Hatten, Jr and J W Keating

AJNR Am J Neuroradiol 1983, 4 (3) 474-477

<http://www.ajnr.org/content/4/3/474>

This information is current as
of May 30, 2025.

False-Positive CT Gas Cisternogram

Hugh J. Robertson,¹ H. Paul Hatten, Jr.,² and James W. Keating³

Nonfilling of the normal internal auditory canal on computed tomographic (CT) gas cisternography was observed in seven (11%) of 62 cases in a retrospective study of three series of gas cisternograms. The meatal surface of the fluid-filled canal was convex and pointed, simulating a small acoustic neuroma. A meniscus effect at the gas-cerebrospinal fluid interface was considered the probable cause of nonfilling of the canal with gas. Shaking the patient's head briskly after injection of gas into the spinal fluid will facilitate filling of the internal auditory canal with gas. Bone erosion in the canal or meatus suggests the presence of acoustic neuroma. In the absence of conclusive findings of neuroma, persistent nonfilling of the canal is an indication for repeat cisternography with an alternate contrast medium.

The acoustic neuroma less than 1.5 cm in diameter frequently escapes detection by the standard computed tomographic (CT) brain scan even after intravenous injection of contrast medium [1, 2]. The technique of CT gas cisternography has facilitated the diagnosis of the small acoustic neuroma. High-resolution CT can now demonstrate even the very small neuroma confined to the internal auditory canal [2, 3]. The technique is simple, safe, and in some cases has been performed on an outpatient basis [3].

Previous reports on CT gas cisternography have noted a risk of false-negative study for acoustic neuroma for the small intracanalicular tumor [2]. The same reports have noted no false-positive diagnoses of acoustic neuroma on CT gas cisternography [2-4]. This paper reviews the causes of nonfilling of the internal auditory canal on CT gas cisternography and points out a frequent possible cause of false-positive diagnosis of acoustic neuroma.

Materials and Methods

Three series of CT gas cisternograms totalling 62 cases were studied retrospectively for nonfilling of the internal auditory canal with gas. Cases involving pathologic causes for nonfilling and cases in which the internal auditory canal was subsequently proven normal were respectively noted.

All patients studied had symptoms and signs of sensorineural hearing loss, tinnitus, and dizziness. Preliminary CT brain scans were obtained before and after intravenous injection of contrast medium. If the scans were normal or equivocal, a CT gas cisternogram was obtained to exclude or confirm the presence of acoustic neuroma. All cisternographies were done by the techniques of

Sortland [4] or Kricheff et al. [5], with injection of 5-6 cm³ of room air into the lumbar subarachnoid space. The CT scanners used were the GE 8800, Picker Synerview 600, and EMI 5005 with high-resolution component.

Results

There was nonfilling of the internal auditory canal on either the symptomatic or nonsymptomatic side in 13 of the 62 cases studied. Acoustic neuroma was correctly diagnosed in two cases. There was nonfilling of a canal subsequently proven normal by repeat gas or Pantopaque cisternography in seven cases (11%) in the three series.

Representative Case Reports

Case 1

The CT gas cisternogram in a 54-year-old man showed nonfilling of the internal auditory canal (fig. 1). A translabyrinthine operation revealed meatal arachnoidal adhesions.

Case 2

A 30-year-old man with nonfilling of the internal auditory canal on CT gas cisternography had an apparent soft-tissue mass protruding from the meatus and continuous with the neurovascular bundle (fig. 2). The clinical diagnosis was end-stage Ménière disease. Translabyrinthine operation was performed in order to section the vestibular nerve for intractable tinnitus. The internal auditory canal, meatus, and eighth nerve were normal in appearance, and surgery revealed no tumor or other abnormality.

Case 3

A 56-year-old man had nonfilling of the internal auditory canal on CT gas cisternography (fig. 3A). The scan was repeated after the patient's head was gently shaken, tapped, and rocked back and forth. Air then filled a normal internal auditory canal (fig. 3B).

Case 4

A 45-year-old woman who had CT gas cisternography on an EMI scanner with range highlight facility showed nonfilling of the internal

¹ Department of Radiology, Louisiana State University Medical Center, 1542 Tulane Ave., New Orleans, LA 70112. Address reprint requests to H. J. Robertson.

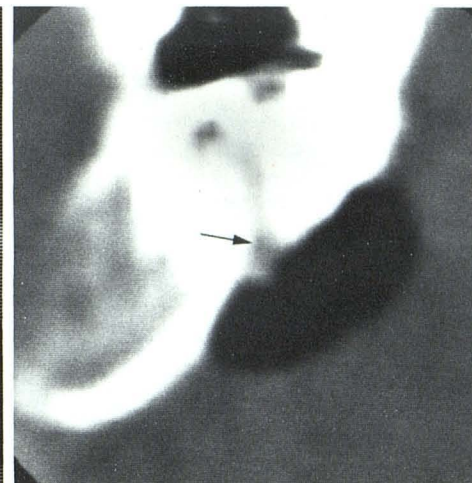
² Department of Radiology, Presbyterian Hospital, Charlotte, NC 28233.

³ Department of Radiology, Tulane University Medical School, New Orleans, LA 70112. Present address: 3625 Houma Blvd., Metairie, LA 70002.

Fig. 1.—Case 1. CT gas cisternogram with nonfilling of internal auditory canal (arrows) due to meatal arachnoidal adhesions.

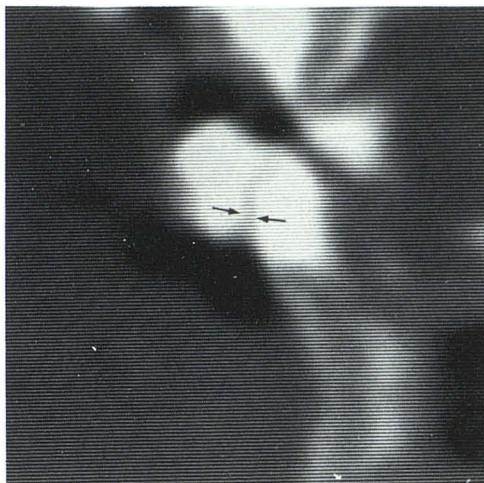

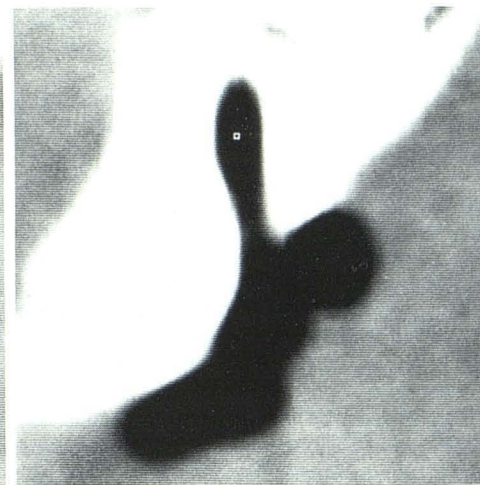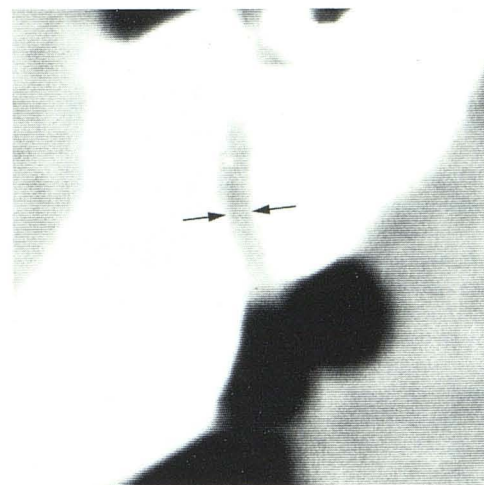Fig. 2.—Case 2. CT gas cisternogram with nonfilling of internal auditory canal due to cerebrospinal fluid meniscus effect. Partial filling of meatus and false appearance of meatal mass (arrow).



1

2

Fig. 3.—Case 3. **A**, CT gas cisternogram with nonfilling of internal auditory canal (arrows). **B**, Repeat scan after shaking patient's head. Normal canal fills with gas.



A

B

auditory canal (fig. 4A). Subsequent Pantopaque cisternography demonstrated a normal internal auditory canal and meatus (fig. 4B).

Discussion

The typical small symptomatic neuroma occludes the internal auditory canal, erodes bone at the margin of the canal or meatus, and presents a variably convex surface protruding into the cerebellopontine angle cistern [6]. The tumor is continuous with the neurovascular bundle. Occasionally neuroma arises from the cisternal segment of the eighth nerve and presents entirely within the cerebellopontine angle cistern. A review by Anderson et al. [2] notes bone erosion in the internal auditory meatus or canal in 80%–90% of acoustic neuromas. Skull radiography, complex motion tomography, and CT are approximately equal in diagnostic accuracy of detection of bone erosion in such cases [7–9].

False-positive diagnosis of acoustic neuroma on Pantopaque cisternography occurs in 1%–10% of suspected cases. The tumor characteristically prevents filling of the internal auditory canal on cisternography. Various causes of this phenomenon have been

noted in the literature, including: (1) any cerebellopontine angle mass (e.g., extraaxial tumor, acoustic neuroma, meningioma, cholesteatoma, metastasis, arachnoid cyst, aneurysm, intraaxial tumor); (2) normal canal with small diameter entirely filled by the neurovascular bundle [6, 8]; (3) neuritis with neurovascular bundle edema filling normal canal [8, 11]; (4) meatal obstruction caused by arterial loop or vein [8, 10, 11]; (5) minimal or absent reflection of meninges into the canal, occurring as a developmental variant [8]; (6) arachnoidal adhesions occluding the internal auditory meatus [8, 12]; and (7) contrast medium of high viscosity, such as Pantopaque, used in a patient with a small canal [8, 13]. Two additional rare causes of false-positive diagnosis of acoustic neuroma on Pantopaque cisternography are Arnold-Chiari malformation [11] and contralateral arachnoidal meatal adhesions [14].

It is likely that the causes of nonfilling noted in the literature for Pantopaque cisternography, except those relating to viscosity, are similar for gas cisternography. Incomplete filling of the cerebellopontine angle cistern through faulty positioning of the patient is another possible cause of nonfilling of the canal on gas cisternography. We suggest also that certain factors inherent in CT gas cisternography can lead to nonfilling of the internal auditory canal.

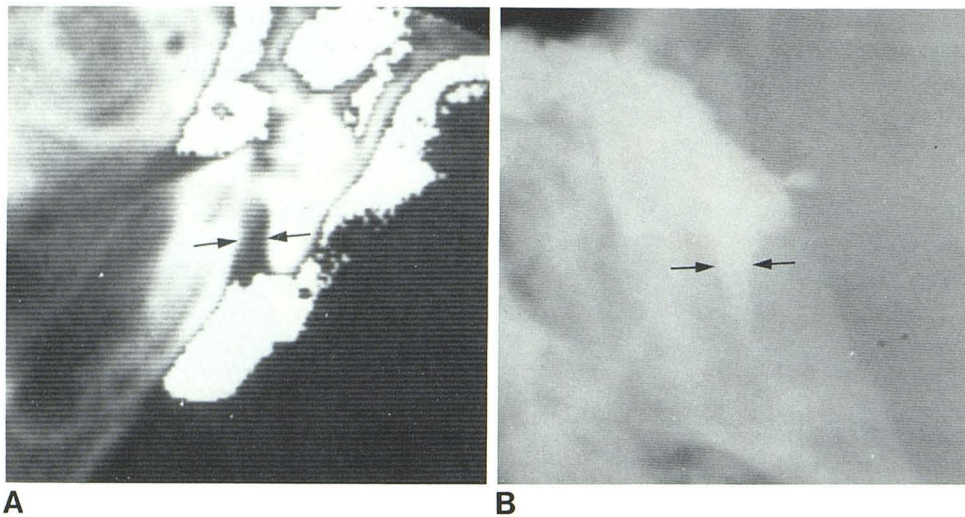


Fig. 4.—Case 4. **A**, CT gas cisternogram from positive-image scanner with range highlight facility. Nonfilling of internal auditory canal (arrows) with gas (shown in white). **B**, Pantopaque cisternogram. Normal filling of canal (arrows).

A meniscus effect at the gas–cerebrospinal fluid interface is probably the most common cause. The fluid meniscus at the meatus can simulate the appearance of a small acoustic neuroma, as in our cases 2–4.

A simple experiment was devised to illustrate this phenomenon. One ml of normal cerebrospinal fluid was drawn up into a vertically positioned glass tube open at both ends. The effect of gravity on the fluid and its meniscus was observed. The spinal fluid drained from the tube until only a small amount remained. It then ceased to drip. The small amount of residual fluid showed a concave upper meniscus and convex lower meniscus protruding from the tube as a result of gravity (fig. 5A). A string was then suspended in the tube to simulate the neurovascular bundle traversing the internal auditory meatus and canal. The resulting change in the shape of the lower meniscus where it was broken by the string is shown in figure 5B. Its appearance was similar to that of a small acoustic neuroma protruding from the internal auditory meatus with the pointed part of the meniscus continuous with the neurovascular bundle. This pointed meniscus was also identical to the pointed-convex surface at the meatus of the normal internal auditory canal which failed to fill on the first attempt of CT gas cisternography. Finally, an eccentric CT section through the normal gas-filled canal can give a false appearance of acoustic neuroma with pointed-convex surface at the meatus, probably as a result of volume-averaging of attenuation values of cerebrospinal fluid, the neurovascular bundle, adjacent bone, and cisternal gas. Multiple thin CT sections through the internal auditory meatus and canal are essential to show the true dimensions and configuration of the canal.

The original paper of Sortland [4] describing CT gas cisternography noted the absence of gas filling in one-third of asymptomatic normal internal auditory canals. Pinto and Kricheff et al. [3, 5], in the largest series reported, noted no instance of false-positive CT gas cisternogram. Anderson et al. [2] reported bilateral nonfilling of internal auditory canals on gas cisternography with subsequent filling on the symptomatic side by Pantopaque cisternography. Downey et al. [15] reported one case of false-positive CT gas cisternography attributable to arachnoiditis. The 11% incidence of false-positive CT gas cisternogram in our study suggests a potentially serious risk of false diagnosis of acoustic neuroma. Awareness of the possible causes of nonfilling of the internal auditory meatus and canal with gas on CT cisternography and the use of appropriate remedial measures will result in a very high rate of accuracy of diagnosis of acoustic neuroma. The routine technique of shaking the patient's head after injection of gas into the spinal fluid is likely to eliminate some potential cases of nonfilling of the canal with gas.

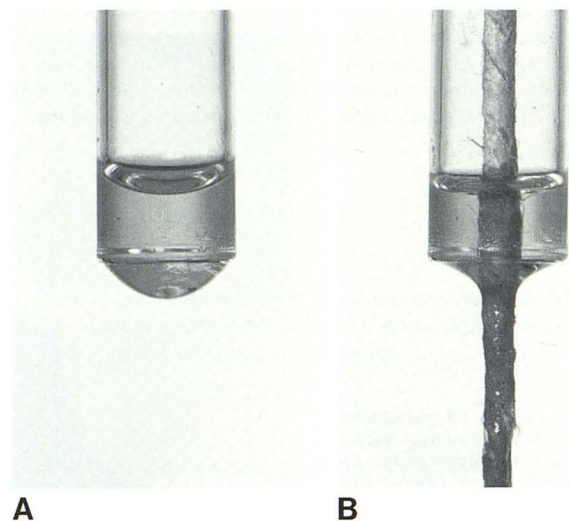


Fig. 5.—**A**, Residual cerebrospinal fluid in vertical glass tube has concave upper meniscus and convex lower meniscus. **B**, String simulating neurovascular bundle in internal auditory meatus and canal causes change in shape of lower meniscus.

Moreover, when the canal does not fill with gas on the first attempt, it may fill on a repeat scan obtained after shaking the patient's head. Noting the presence or absence of bone erosion in the margins of the canal and meatus is important in diagnosis, since most acoustic neuromas are accompanied by some bone erosion [2]. High-resolution algorithms and edge-enhancement techniques for visualization of the neurovascular bundle within the gas-containing canal will aid in detecting the small intracanalicular neuroma [3, 16]. Finally, in cases of persistent nonfilling of the canal with gas, cisternography with another contrast medium is indicated. Metrizamide has the disadvantage of density-averaging with the bone of the canal with resultant poor visualization of the canal and its contents [17]. Pantopaque is therefore considered the contrast medium of choice for repeat cisternography.

REFERENCES

1. Davis KR, Parker SW, New PFJ, et al. Computed tomography of acoustic neuroma. *Radiology* 1977;124:81–86

2. Anderson R, Diehl J, Maravilla K, Fancher J, Schaefer S. Computerized axial tomography with air contrast of the cerebellopontine angle and internal auditory canal. *Laryngoscope* **1981**;91:1083-1097
3. Pinto RS, Kricheff II, Bergeron RT, Cohen N. Small acoustic neuromas: detection by high resolution gas CT cisternography. *AJNR* **1982**;3:283-286, *AJR* **1982**;139:129-132
4. Sortland O. Computed tomography combined with gas cisternography for the diagnosis of expanding lesions in the cerebellopontine angle. *Neuroradiology* **1979**;18:19-22.
5. Kricheff II, Pinto RS, Bergeron TB, Cohen N. Air-CT cisternography and canalography for small acoustic neuromas. *AJNR* **1980**;1:57-63
6. Baker HL Jr. Cerebellopontine angle myelography. *J Neurosurg* **1972**;36:614-624
7. Etter LE. Plain film demonstration of acoustic nerve tumors. *Arch Otolaryngol* **1973**;98:414-416
8. Valvasorri GE. The abnormal auditory canal: the diagnosis of acoustic neuroma. *Radiology* **1969**;92:449-459
9. Hatam A, Moller HA, Olivecrona H. Evaluation of the internal auditory meatus with acoustic neuromas using computed tomography. *Neuroradiology* **1979**;17:197-200
10. Novy S, Jensen KM. Filling defects and non-filling of the internal auditory canal in posterior fossa myelography. *AJR* **1975**;124:265-270
11. Wright RE, Turner JS Jr. Positive angle myelograms without acoustic neuroma. *Laryngoscope* **1973**;83:733-746
12. Wilner HJ, Rammat K. Unilateral arachnoidal cysts and adhesions involving the eighth nerve. *AJR* **1972**;115:126-136
13. Valvasorri GE. Myelography of the internal auditory canal. *AJR* **1972**;115:578-586
14. Scanlan RL. Positive contrast medium (iopendylate) in diagnosis of acoustic neuroma. *Arch Otolaryngol* **1964**;80:698-706
15. Downey EF Jr, Buck DR, Ray JW. Arachnoiditis simulating acoustic neuroma on air-CT cisternography. *AJNR* **1981**;2:470-471
16. Bentson JR, Mancuso AA, Winter J, Hanafey WN. Combined gas cisternography and edge-enhanced computed tomography of the internal auditory canal. *Radiology* **1980**;136:777-779
17. Naidich TP. Air CT canalography for the evaluation of the internal canals. *Laryngoscope* **1980**;90:526-530