



Discover Generics

Cost-Effective CT & MRI Contrast Agents

 FRESENIUS
KABI

[WATCH VIDEO](#)

AJNR

CT appearance of the adolescent and preadolescent pituitary gland.

R G Peyster, E D Hoover, R R Viscarello, T Moshang and M E Haskin

AJNR Am J Neuroradiol 1983, 4 (3) 411-414

<http://www.ajnr.org/content/4/3/411>

This information is current as
of June 24, 2025.

CT Appearance of the Adolescent and Preadolescent Pituitary Gland

Robert G. Peyster,¹ Eric D. Hoover,¹ Richard R. Viscarello,¹ Thomas Moshang,² and Marvin E. Haskin¹

Coronal computed tomographic scans of the pituitary gland in 27 normal children, adolescents, and young adults (ages, 8–21 years) and in a comparison group of adults (ages, 24–91 years) were evaluated retrospectively to test the applicability of published criteria for size and configuration of normal adult pituitary glands to younger patients. Statistically significant differences were found between the two groups, indicating that the pituitary gland in adolescents, particularly girls, is larger than in younger or older patients. The authors suggest that pubertal pituitary hyperplasia accounts for these findings. They conclude that standards for normal pituitary glands are probably inappropriate for adolescents.

Thin coronal-section computed tomography (CT) is the most accurate radiologic modality for evaluation of the pituitary gland [1–4] and is the only current radiologic technique for imaging the gland's morphology. The CT appearance of the normal pituitary gland has been studied in adult patients without clinical evidence of pituitary dysfunction [4, 5], providing standards of normality for gland height and shape [4]. These criteria have been widely employed for CT identification of enlarged glands containing microadenomas [1–5]. We know of no CT or autopsy study that has specifically examined the appearance of the pituitary gland in children or adolescents without pituitary dysfunction. We noted several cases of pituitary glands with abnormal height and/or shape, according to the previously mentioned standards, in young patients in whom there was no clinical suspicion of pituitary adenoma. Uncertain of the applicability of these standards to younger patients, we undertook a study to determine the CT appearance of the normal pituitary gland in children and adolescents.

Materials and Methods

Review of our files yielded 27 coronal CT scans that included adequate visualization of the pituitary gland in patients between 8 and 21 years of age who had no reasonable suspicion of harboring pituitary pathology (group 1). A comparison group (group 2) of 27 adult scans was assembled from the files. Criteria for selection were adequate coronal visualization of the pituitary gland and lack of any clinical suspicion of pituitary pathology. The age range for subjects in group 2 was 24–91 years. Most patients in both groups had been examined initially because of clinical suspicion of pathology involving the orbits, optic chiasm, cavernous sinuses, or nasopharynx.

All studies were performed on a GE C/T 8800 scanner with 1.5

or 5 mm coronal sections through the sella turcica following intravenous contrast infusion (Conray 60%, 150 ml; Mallinckrodt).

The pituitary glands in both groups were evaluated for height and superior contour. Gland height was measured at the midline, except in convex glands, where it was taken at the highest point. The superior contour was described as upwardly concave, convex, or flat. Also noted were any cases of unusually narrow glands (in transverse diameter). Pituitary glands in both groups were categorized as normal, questionable, or abnormal according to the criteria provided by Syvertsen et al. [4]. "Normal" glands had flat (fig. 1A) or concave (fig. 1B) superior margins and measured less than or equal to 6 mm in height for males and 7 mm for females. "Abnormal" glands (Fig. 1C) all had convex superior margins and heights exceeding 6 mm for males and 7 mm for females. Glands categorized as "questionable" (fig. 1D) all had convex superior margins and heights near the upper limits of normal (for males, 5.5–6 mm; for females, 6.5–7 mm).

Results

The results for children and adolescents (group 1) are shown in table 1 and results for adults (group 2) are shown in table 2.

Mean gland height for group 1 females was significantly greater than for group 2 females ($p < 0.02$). Mean gland height for group 1 males was greater than for group 2 males. These differences are amplified when group 1 is subdivided into age groups. In boys and girls 8–12 years of age, gland heights were similar to those in adults of each gender. In girls 13–17 years of age, a dramatic increase in mean gland height is noted, with a subsequent small decrease in mean gland height among young women 18–21 years of age. A highly significant overall difference in gland height is found among girls 13–21 years of age compared with adult females in group 2 ($p < .001$). For boys in group 1, a small increase in mean gland height is noted in ages 13–17 years compared with ages 8–12 years. The mean gland height continues to increase among young men 18–21 years of age. The mean gland height for boys 13–21 years of age is significantly greater than for adult males in group 2 ($p < 0.05$).

Differences between groups 1 and 2 are also noted in the contour of the superior margin of the gland. A convex superior margin was much more common in group 1 (42%) than in group 2 (12%). A concave superior margin was relatively uncommon in children (16%) compared with adults (52%). All glands with convex superior margins in group 1 were found in patients 13–21 years of age and were more common in females than in males.

The CT ratings of glands also revealed major dissimilarities

¹ Department of Diagnostic Radiology, Hahnemann University Medical College and Hospital, 230 N. Broad St., Philadelphia, PA 19102. Address reprint requests to R. G. Peyster.

² Department of Pediatrics, Hahnemann University Medical College and Hospital, Philadelphia, PA 19102.

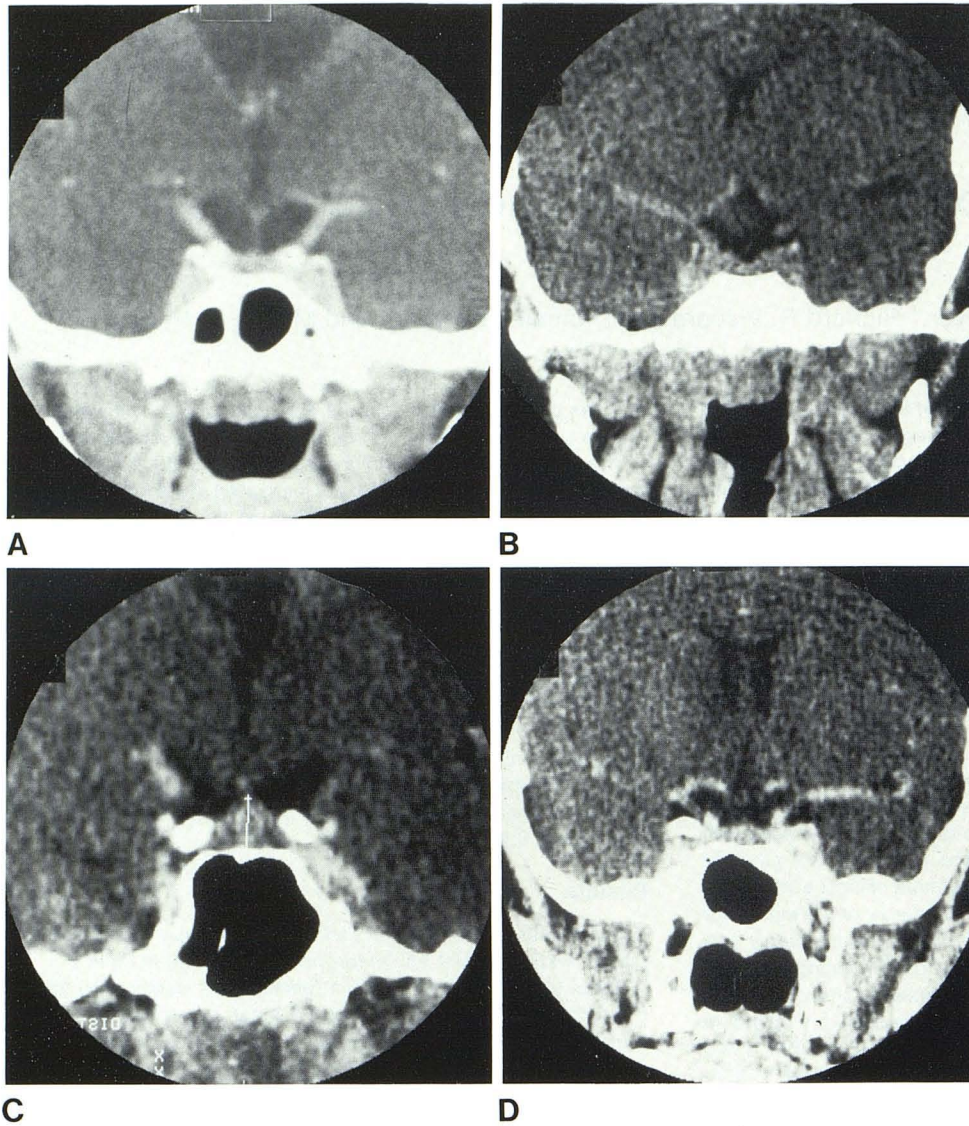


Fig. 1.—CT scans of pituitary gland. A, "Normal" gland with flat superior margin. Gland height, 4 mm. 5 mm coronal section, magnification $\times 2.3$. B, "Normal" gland with concave superior margin. Gland height 3.5 mm. 1.5 mm coronal section, magnification $\times 2$. C, "Abnormal" gland in 21-year-old man. Convex superior margin. Gland height, 8 mm. 1.5 mm coronal section, magnification $\times 3$. (Note cursor used for gland height measurement.) D, "Questionable" gland in 14-year-old boy. Slightly convex superior margin. Gland height, 6 mm. 1.5 mm coronal section, magnification $\times 2$.

TABLE 1: CT Appearance of Adolescent and Preadolescent Pituitary Gland

Gender: Age Group (Years)	No. Cases	Mean Height \pm SD (mm)	Appearance of Gland					
			Shape: No. (%)			CT Rating: No. (%)		
			Convex	Flat	Concave	Normal	Questionable	Abnormal
Female:								
8-12	3	4.0 \pm 1.7	0	3	0	3	0	0
13-17	3	8.2 \pm 1.4	3	0	0	0	1	2
18-21	5	7.3 \pm 0.6	4	0	1	1	1	3
Subtotals	11	6.6 \pm 2.0	7	3	1	4	2	5
Male:								
8-12	4	3.0 \pm 0.8	0	2	2	4	0	0
13-17	6*	4.3 \pm 1.2	1	3	1	4	1	0
18-21	6	5.7 \pm 1.3	3	3	0	3	1	2
Subtotals	16*	4.5 \pm 2.1	4	8	3	11	2	2
Totals	27*	5.4 \pm 2.1	11 (42)	11 (42)	4 (16)	15 (58)	4 (15)	7 (27)

* A 15-year-old boy with an 18 mm sellar-suprasellar mass was excluded from all calculations.

TABLE 2: CT Appearance of Adult Pituitary Gland

Gender, Mean Age (Years) ± SD	No. Cases*	Appearance of Gland						
		Mean Height ± SD (mm)	Shape: No. (%)			CT Rating: No. (%)		
			Convex	Flat	Concave	Normal	Questionable	Abnormal
Females, 51 ± 22	15	4.8 ± 1.7	2	6	6	13	1	1
Male, 55 ± 19	12	3.5 ± 2.0	1	3	7	11	0	1
Totals	27	4.3 ± 2.0	3 (12)	9 (36)	13 (52)	24 (89)	1 (4)	2 (7)

* Two cases (one female, one male) of empty sella were excluded from statistics involving gland height and shape.

between groups 1 and 2 ($p < 0.02$). There were eight cases (30%) in group 1 with abnormal gland height and 12 with convex superior margins, including a 15-year-old boy who had an 18 mm high sellar-suprasellar mass and was excluded from all further calculations. The corrected incidence of abnormal cases (i.e., cases suspect for the presence of microadenomas, based on accepted criteria) in group 1 was 27%, compared with 7% in group 2. There was also a greater incidence of questionable or borderline cases in group 1 (15%) than in group 2 (4%). As would be expected from the analysis of gland height and shape, all the abnormal and questionable cases in group 1 occurred in patients 13–21 years of age and were more common in females. The incidence of abnormal and questionable cases in males 18–21 years of age was greater than in younger male subjects.

Unusually narrow sella turcica and pituitary glands were noted in eight subjects in group 1. Five of these subjects were rated normal, two questionable, and one abnormal. In group 2, one subject had a narrow sella and pituitary gland and was rated normal. Clinical and laboratory follow-up evaluation of two of the abnormal and three of the questionable cases in group 1 failed to demonstrate any evidence of pituitary dysfunction.

Discussion

In 1979, Syvertsen et al. [4] reported their findings on CT examination of the pituitary gland in 20 patients 6–74 years of age who had no clinical suspicion of harboring a pituitary adenoma. All 20 patients had flat or concave superior gland margins. The mean gland heights were 4.8 mm (range, 2.7–6.7 mm) for females and 3.5 mm (range, 1.4–5.9 mm) for males. In four surgically proven cases of microadenoma, two had convex upper gland margins and all four had gland heights exceeding 8.8 mm. On the basis of these findings, the authors proposed that glands exceeding 7 mm in height for females and 6 mm for males be considered abnormal. They also concluded that a convex contour of the superior margin of the gland is an abnormal finding. They did not elaborate on the age distribution of their 20 patients, nor did they mention the number of children included. In 1982, Chambers et al. [5] studied by CT the pituitary glands of 50 subjects who had orbital complaints but were without clinical symptoms of pituitary disease. The age range of these patients was not given. The authors found the superior gland margin to be flat or concave in 96% and the mean gland height to be 5.3 mm ± 1.7 mm. In the same study, 100 autopsy specimens of pituitary glands from patients without known clinical pituitary abnormalities were evaluated. The subjects were 9–82 years of age (38 females and 42 males). The superior margins of these glands were flat or concave in 94% and the mean gland height was 5.2 mm ± 2 mm. Again, the age range of the patients was not mentioned. In general, the findings of Chambers et al. are in agreement with those of Syvertsen et al. Muhr et al. [6], in an autopsy series of 205 pituitary glands, found a mean gland height

of 6 mm ± 1 mm for females and 5 mm ± 1 mm for males. Glands with convex upper margins were noted in 4% of specimens that did not contain sizable lesions. Only two or three patients under 21 years of age appeared to have been included in this study and the ages of those with convex glands were not provided. McLachlan et al. [7] found the upper gland margin to be concave in most specimens in an autopsy series of 50 cases with no history of pituitary dysfunction.

We know of no previous studies, either by CT or autopsy, of the appearance of the normal pituitary gland in childhood or adolescence. Although the process of selection of the 27 patients included in group 1 cannot be considered random, our subjects were selected in a manner similar to that employed by Syvertsen et al. [4] and Chambers et al. [5]. The comparison group of adult patients (group 2) was included to nullify the effect of any idiosyncrasies in our interpretation of CT scans or in our scanning technique. The findings regarding gland height and superior margin contour in our adult group were similar to those of other researchers [4, 5], thus minimizing the possibility that differences between our group 1 and group 2 reflect an atypical adult sample. The 7% incidence of abnormal glands in group 2 falls within the reported range for incidental microadenomas (2.7%–27%) [8].

The 4× higher incidence of abnormal cases in group 1 compared with group 2 is striking and statistically significant ($p < 0.02$). The dissimilarity between groups 1 and 2 is even more noticeable when group 1 is subdivided into age groups, whereby it is demonstrated that the abnormal and questionable glands occur exclusively in subjects older than 12 years of age, and more commonly and earlier in females than in males. It is unlikely that these statistics can be explained by the presence of incidental microadenomas. Pituitary adenomas are generally considered rare in children and adolescents, especially when there is no clinical evidence of pituitary gland dysfunction [8–12]. The incidence of abnormal cases in group 1 (30%) exceeds the reported frequency of incidental microadenomas or any other sizable pathology of the pituitary gland [5, 7, 9]. Clinical and laboratory follow-up of two of the abnormal and three of the questionable cases in group 1 revealed no evidence of pituitary dysfunction.

It is also implausible that fundamental errors in the standards of normality employed for CT evaluation of the pituitary gland could explain these findings, since the same criteria were used for both group 1 and group 2. However, several authors have challenged certain criteria proposed by Syvertsen et al. [4]. Taylor [1] stated that convexity of the superior gland margin can be a normal variant when the width of the gland is small. In our study, narrow glands were encountered more often in cases considered normal than in the abnormal or questionable cases. Muhr et al. [6] reported a 4% incidence of convex superior margins in specimens devoid of any sizable pathology and concluded that this finding can be a normal variant. Gardeur et al. [13] stated that no study to date has clearly established standards of normality for the CT appearance of the

pituitary gland, since autopsy or surgical confirmation would be required to prove that there was no pathology present. While such confirmation would be ideal, it is hardly practical.

The best explanation for our findings may be found in the physiological-endocrinological events associated with puberty. In support of this hypothesis we offer the following: (1) No abnormal glands were found in the group of subjects 8–12 years of age and comprising mainly prepubertal children. The mean gland heights for both genders in this age group do not differ significantly from those found in adults in group 2. (2) In females 13–17 years of age, who would be expected to have entered puberty, there is a twofold increase in mean gland height. Males in this age group demonstrate a smaller increase in mean gland height, perhaps reflecting the later onset of puberty in males [14]. (3) In males 18–21 years of age, a continued increase in mean gland height is noted compared with younger boys, perhaps reflecting the fact that most males have reached puberty by this time. (4) The age-related changes noted in the pituitary glands parallel the change in circulating levels of gonadotropins, which increase sharply at puberty [15] and earlier in females [16]. (5) Physiological enlargement of the pituitary gland (hyperplasia) is reported to occur in pregnancy [7, 13], another developmental period during which increased hormonal production by the pituitary gland is expected. An association has been noted [17–19] between pituitary hyperplasia and certain endocrine-deficient states caused by end-organ failure, such as primary hypothyroidism or hypogonadism, presumably secondary to decreased negative-feedback inhibition on the hypothalamus. (6) Costello [9] found a sharp increase in the incidence of "subclinical adenomas" in the pituitary glands of children beginning at about 12 or 13 years of age, which corresponds to the age at which the large increase in mean gland height in females was noted in our study. Since it may be difficult to distinguish pathologically between adenomas and foci of hyperplasia [12, 20], it seems likely that Costello may have mistaken hyperplasia secondary to puberty for microadenomas in these specimens.

Despite the relatively small sample, highly significant differences in pituitary gland size and configuration between adults and pubescent children were noted in our study. It appears from these findings that the previously described standards of normality for the CT appearance of the pituitary gland [4] are not applicable to adolescents, particularly to adolescent females. A large cross-sectional study of the size, shape, and general appearance of the pituitary gland would be helpful to confirm our findings and to provide gender- and age-related standards of normality for the gland.

REFERENCES

1. Taylor S. High resolution computed tomography of the sella. *Radiol Clin North Am* 1983;20:207–236
2. Cusick JF, Haughton VM, Hagen TC. Radiological assessment of intrasellar prolactin-secreting tumors. *Neurosurgery* 1980;6:376–379
3. Bonafe A, Sobel D, Manelfe C. Relative value of computed tomography and hypocycolidal tomography in the diagnosis of pituitary microadenoma: a radio-surgical correlative study. *Neuroradiology* 1981;22:133–137
4. Syvertsen A, Haughton VM, Williams AL, Cusick JF. The computed tomographic appearance of the normal pituitary gland and pituitary microadenomas. *Radiology* 1979;133:385–391
5. Chambers EF, Turski PA, LaMasters D, Newton TH. Regions of low density in the contrast-enhanced pituitary gland: normal and pathologic processes. *Radiology* 1982;144:109–113
6. Muhr C, Bergstrom K, Grimelius L, Larsson SG. A parallel study of the roentgen anatomy of the sella turcica and the histopathology of the pituitary gland in 205 autopsy specimens. *Neuroradiology* 1981;21:55–65
7. McLachlan MSF, Williams ED, Fortt RW, Doyle FH. Estimation of pituitary gland dimensions from radiographs of the sella turcica. *Br J Radiol* 1968;41:323–330
8. Burrow GN, Wortzman G, Rewcastle NB, Holgate RC, Kovacs K. Microadenomas of the pituitary and abnormal sellar tomograms in an unselected autopsy series. *N Engl J Med* 1981;304:156–158
9. Costello RT. Subclinical adenoma of the pituitary gland. *AM J Pathol* 1936;12:205–215
10. Belloni G, Baciocco A, Borrelli P, Sagui G, DiRocco G, Maira G. The value of CT for the diagnosis of pituitary microadenomas in children. *Neuroradiology* 1978;15:179–181
11. Harwood-Nash DC, Fitz CR. *Neuroradiology in infants and children*. St. Louis: Mosby, 1976
12. Russell DS, Rubinstein LJ. *Pathology of tumors of the nervous system*. Baltimore: Williams & Wilkins, 1977:313
13. Gardeur D, Naidich TP, Metzger J. CT analysis of intrasellar pituitary adenomas with emphasis on patterns of contrast enhancement. *Neuroradiology* 1981;20:241–247
14. Tanner JM. Growth and endocrinology of the adolescent. In: Gardner LI, ed. *Endocrine and genetic disease of childhood and adolescence*. Philadelphia: Saunders, 1975:14–64
15. Fairman C, Winter JSD. Gonadotropins and sex hormone patterns in puberty. In: Grunbach MM, Grave GD, Mayer FE, eds. *The control of the onset of puberty*. New York: Wiley, 1974:32–55
16. Tanner JM. In the discussion of Fairman C, Winter JSD. Gonadotropins and sex hormone patterns in puberty. In: Grunbach MM, Grave GD, Mayer FE, eds. *The control of the onset of puberty*. New York: Wiley, 1974:57
17. Lawrence AM, Wilber JF, Hagen TC. The pituitary and primary hypothyroidism. *Arch Intern Med* 1973;132:327–333
18. Danziger J, Wallace S, Handel S, Samaan NB. The sella turcica in primary end organ failure. *Radiology* 1979;131:111–115
19. Okuno T, Sudo M, Momoi T, et al. Pituitary hyperplasia due to hypothyroidism. *J Comput Assist Tomogr* 1980;4:600–602
20. Collins WF. Adenomas of the pituitary gland—an epidemic? *Surg Clin North Am* 1980;60:1201–1206