



Discover Generics

Cost-Effective CT & MRI Contrast Agents



FRESENIUS
KABI

WATCH VIDEO

AJNR

Occluded but nonthrombosed internal carotid artery: an indication for endarterectomy.

H S Ahn, A E Rosenbaum, G S Allen, T J Preziosi, J S Shillito, R C Heros and R A Baker

AJNR Am J Neuroradiol 1983, 4 (3) 286-288

<http://www.ajnr.org/content/4/3/286>

This information is current as
of June 6, 2025.

Occluded but Nonthrombosed Internal Carotid Artery: An Indication for Endarterectomy

Hyo S. Ahn,¹ Arthur E. Rosenbaum,¹ George S. Allen,² Thomas J. Preziosi,³ John S. Shillito,⁴ Roberto C. Heros,⁵ and Richard A. Baker⁶

The indications for carotid endarterectomy are sometimes imprecise. Total occlusion of the internal carotid artery has often implied irreversibility. Carotid thromboendarterectomy was performed on eight patients who on angiography had a complete occlusion of proximal internal carotid artery but showed antegrade opacification of the infraophthalmic carotid siphon. Direct magnification, delayed radiography, and subtraction were used on all patients. In five of eight patients, normal antegrade cervical internal carotid blood flow was restored. The possible restoration of the occluded internal carotid artery lumen offers a viable alternative to bypass surgery in selected cases.

Since the first operative reconstruction of the completely occluded internal carotid artery, numerous publications have discussed indications, surgical techniques, and results. Disparate conclusions have been reached [1–3], although most reports do not favor surgical intervention. Selected authors [4, 5] have published their observations on occlusions of short duration. In the majority of cases, however, the clinical determination of the onset of complete occlusion remains problematic. Reliable criteria, especially angiographic criteria, have been sought to ascertain the duration of occlusion. Recent advances in cerebral angiography have played a role in providing answers to the clinical questions.

Subjects and Methods

A series of eight patients studied angiographically had totally occluded cervical internal carotid arteries and demonstrable patency of the infraophthalmic portion of the carotid siphon. All were studied with a 5 French Hanafree catheter (Becton-Dickinson, Rutherford, NJ) introduced transfemorally. The injection rate for catheters positioned just below the common carotid bifurcation was 5–6 ml/sec for a total volume of 6–10 ml diatrizoate meglumine 60% (Hypaque) or iohalamate meglumine (Conray). Selective external carotid catheterization was also performed where feasible to reduce the amount of contrast material and motion and to aid visualization of potential small collaterals. Except in the first case studied, direct magnification (approximately $\times 2$) was used for all projections and

was accomplished via Machlett 78E 0.13 mm and Siemens Opti 1250 Stereolix tubes. Higher magnification ($\times 3$) was then used in the lateral projection in over half the cases.

Conventional carotid endarterectomy was the procedure when surgery was performed. The first case (successfully operated by J. S. S.) had backflow of sludged blood. This observation could be used in all subsequent cases to ascertain whether the backflowing blood had reached a normal consistency.

Results

On preoperative angiography, all eight patients had demonstrated opacification of the carotid siphon. Analysis of the sequence of opacification of the segments of the siphon showed that opacification was antegrade into the lowermost part of the siphon and distinctly different from the retrograde flow originating from the ophthalmic artery. In five of the eight patients, normal internal carotid flow was restored at surgery. In these five patients, tapering of the proximal end of the reconstituted internal carotid artery at the siphon and dilation of the collateral (meningeal) branches of the internal maxillary artery were visualized angiographically (figs. 1A and 1B). Three patients with unsuccessful restoration of flow and no internal carotid backflow at surgery showed siphon opacification also, but the reconstituted siphon had a blunted appearance (fig. 1C) or "bullet-tip" shape (convex superior margin) representing the cephalic end of the thrombus (fig. 1D).

Clinical symptoms either ceased or improved in six patients, including the five with reestablished internal carotid flow. In the sixth case, considerable stenosis of the external carotid artery was relieved at endarterectomy, florid collateral circulation through external carotid connections to the ophthalmic artery was observed, and transient ischemic attacks disappeared. Only in one case was there exacerbation of a patient's transient ischemic attacks. In this case, sludged blood returning down the internal carotid artery at the endarterectomy site was thought to have cleared fully. Immediately after surgery, the patient suffered contralateral hemiplegia and lost the ability to converse in English, his second language, although fluency in his native Polish was retained. Angiography documented proximal middle cerebral occlusion and a patent inter-

¹ Russell H. Morgan Department of Radiology and Radiological Science, Division of Neuroradiology, Johns Hopkins Medical Institutions, 600 N. Wolfe St., Baltimore, MD 21205. Address reprint requests to H. S. Ahn.

² Department of Neurological Surgery, Johns Hopkins Medical Institutions, Baltimore, MD 21205.

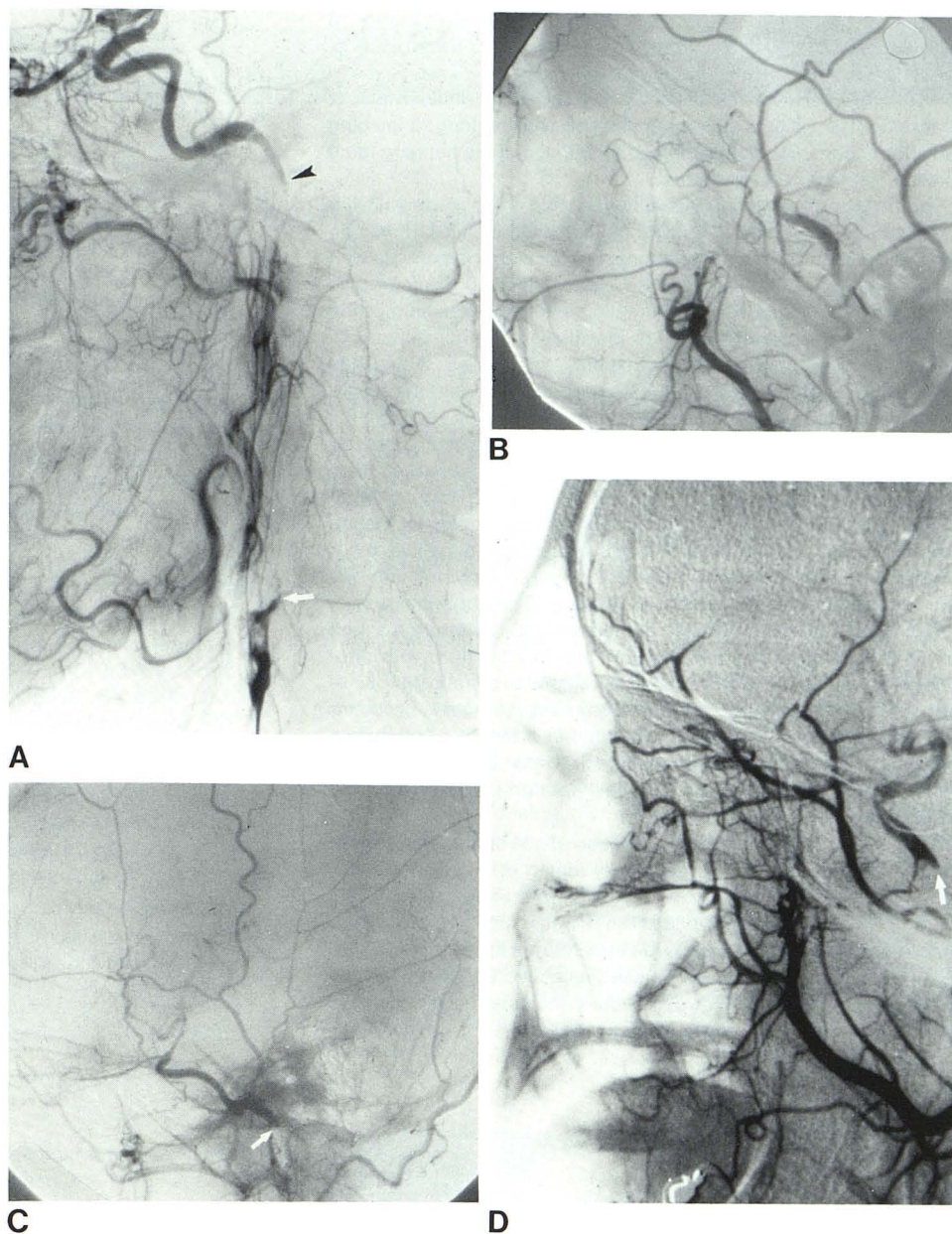
³ Department of Neurology, Johns Hopkins Medical Institutions, Baltimore, MD 21205.

⁴ Department of Neurological Surgery, Brigham & Women's Hospital, Harvard Medical School, Boston, MA 02115.

⁵ Department of Neurological Surgery, Massachusetts General Hospital, Harvard Medical School, Boston, MA 02114.

⁶ Department of Radiology, Division of Neuroradiology, Lahey Clinic, Boston, MA 02215.

Fig. 1.—Preoperative angiograms, lateral view, show carotid patency distal to cervical occlusion. **A**, Selective carotid angiogram, late arterial phase. Apparent complete occlusion of internal carotid artery (*arrow*). Long segment of opacified siphon has tapered proximal end (*arrowhead*). Successful endarterectomy. **B**, Common carotid angiogram. Reconstituted siphon with tapered proximal end is clearly visualized with direct magnification. Inferior cavernous collaterals are opacified before retrograde filling of ophthalmic artery. Successful endarterectomy. **C**, Common carotid angiogram. Distal internal carotid artery opacified via ophthalmic and meningeal collaterals. Proximal end of reconstituted siphon has blunt shape (*arrow*). Unsuccessful surgery. **D**, Common carotid angiogram. Proximal end of reconstituted siphon has "bullet-tip" shape (*arrow*) representing cephalic end of thrombus. Unsuccessful endarterectomy.



nal carotid artery of normal caliber. Within a few days all neurologic symptoms had resolved, and internal carotid angiography 3 weeks later showed restoration of a normal middle cerebral artery.

Discussion

Carotid thromboendarterectomy is the surgical procedure of choice for eliminating the source of thromboembolic strokes from the partly occluded cervical internal carotid artery. Reestablishment of normal internal carotid flow is usually successful in cases of partial occlusion. However, there is controversy about the indications and operative results of endarterectomy in cases of total occlusion of the internal carotid artery [1, 2, 5, 6]. Although most reports do not favor surgical intervention in cases of total occlusion, reports of successful restoration of blood flow continue to appear

[1, 3, 6–9]. Javid [1], on the basis of experience with seven patients, advised against surgical treatment of total occlusions unless surgery was possible shortly after thrombosis occurred. Garamella et al. [4] and Thompson et al. [6] reported 44.4% and 39% success, respectively. Most recently, Hugenholtz and Elgie [5] reported 53% success in 35 patients.

Recent reports agree that the most important factor for operative success is early surgical intervention after onset of occlusion. On reports from one and two decades ago, most angiographies were nonselective and direct magnification was not possible. Moreover, subtraction was not routinely used. As Gabrielsen et al. [9] pointed out, some cases reported earlier as total occlusion may actually have been pseudocclusions (slow antegrade internal carotid artery flow through a highly stenotic lesion). Routine angiographic techniques may not be sufficient to identify complete internal carotid occlusion. High-volume injection [10], hanging head position [11],

and delayed filming [12] have been used for better visualization of the occluded internal carotid artery and retrograde opacification of the distal internal carotid artery. However, when distal common carotid angiography or selective external carotid angiography is performed using direct high magnification with prolonged imaging and subtraction, high-volume injection and use of the hanging head position may not be necessary.

The onset of occlusion is usually assumed to coincide with the development of sudden neurologic deficits. Nonetheless, it may be especially difficult to pinpoint the onset of occlusion in patients with minor neurological deficit. In such cases, detailed angiographic analysis plays a major role in predicting whether reopening of the occluded internal carotid artery is feasible or whether superficial temporal/middle cerebral artery bypass is indicated. Antegrade opacification of the inferior siphon as reported here and the length of the reconstituted distal internal carotid artery as reported by Hugenholtz and Elgie [5] have served as valuable indicators for predicting successful restoration of internal carotid artery flow. Moreover, the shape of the proximal end of the reconstituted internal carotid artery (which requires detailed imaging for visualization) appears to correlate well with surgical results. All five of our cases in which the proximal ends were tapered (figs. 1A and 1B) had successful internal carotid restoration. This tapering is presumed to be due to slow flow in the internal carotid artery through the small collateral channels and perhaps to admixture with unopacified blood. Why there is a delay in complete thrombosis/occlusion of the internal carotid artery in some cases remains problematic. Nonvisualized direct flow and input via collaterals appears to effect this. Thompson et al. [6] hypothesized that the vasa vasorum of the internal carotid artery may allow enough blood to flow into the distal segment to keep it patent.

In this era of bypass surgery, the option of possible reconstitution of the occluded internal carotid artery lumen is sometimes overlooked. Not all patients have a large enough superficial temporal artery to allow successful bypass. The bypass operative procedure is more complex and technically demanding. As intravenous digital angiography gains wider use, detailed selective angiography may be used less frequently. However, where indicated, it can provide valuable information for improved patient care.

REFERENCES

1. Javid H. Surgical management of cerebral vascular insufficiency. *Arch Surg* 1960;80:833-889
2. Young JR, Hymphries AW, deWolfe VG, Beven EG, LeFevre FA. Extracranial cerebrovascular disease treated surgically: study of 100 patients. *Arch Surg* 1964;89:848-855
3. Thompson JE, Talkington CM. Carotid endarterectomy. *Ann Surg* 1976;184:1-15
4. Garamella JJ, Lynch MF, Jensen NK, Sterns LP, Schmidt WR. Endarterectomy and thrombectomy for the totally occluded extracranial internal carotid artery. *Ann Surg* 1966;164:325-333
5. Hugenholtz H, Elgie RG. Carotid thrombo-endarterectomy: a reappraisal criteria for patient selection. *J Neurosurg* 1980;53:776-783
6. Thompson JE, Austin DJ, Patman RD. Endarterectomy of the totally occluded carotid artery for stroke. *Arch Surg* 1967;95:791-801
7. Kish GF, Adkins PC, Slovins AJ. The totally occluded internal carotid artery: indications for surgery. *Am J Surg* 1977;134:288-292
8. Kusunoki T, Rowed DW, Tator CH, Loughheed WM. Thrombo-endarterectomy for total occlusion of the internal carotid artery: a reappraisal of risks, success rate and potential benefits. *Stroke* 1978;9:34-38
9. Gabrielsen TO, Seeger JF, Knake JE, Burke DP, Stilwill EW. The nearly occluded internal carotid artery: a diagnostic trap. *Radiology* 1981;138:611-618
10. Countee RW, ViJayanathan T. Reconstitution of "totally" occluded internal carotid arteries: angiographic and technical considerations. *J Neurosurg* 1979;50:747-757
11. Koch RL, Bieber WP, Hill MC. The hanging head position for detection of site of internal carotid artery occlusion. *AJR* 1967;101:111-115
12. Murphey F, Shillito J. Avoidance of false angiographic localization of the site of internal carotid occlusion. *J Neurosurg* 1959;16:24-31