



Discover Generics

Cost-Effective CT & MRI Contrast Agents



FRESENIUS
KABI

WATCH VIDEO

AJNR

Carotid blood flow response to Conray-60: diagnostic implications.

A B Dublin, J P McGahan, B M Lantz and D H Turkel

AJNR Am J Neuroradiol 1983, 4 (3) 274-276

<http://www.ajnr.org/content/4/3/274>

This information is current as
of June 24, 2025.

Carotid Blood Flow Response to Conray-60: Diagnostic Implications

Arthur B. Dublin,¹ John P. McGahan, Bo M. T. Lantz, and David H. Turkel

The vasoactive effect of the angiographic contrast medium Conray-60 (iothalamate meglumine 60%) on carotid blood flow was studied by the video dilution technique in 26 subjects during routine neuroangiography. After a test series of 1 ml injections of contrast material into the carotid arteries at designated time intervals, an increase in carotid blood flow was found in normal controls at 30 sec, while a significant decrease in flow was observed in patients with atheromatous disease and avascular intracranial masses ($p < 0.01$). Test responses in patients with intracranial aneurysm, neoplasm, and granulomatous vasculitis are also reported. The differential effect of contrast material on the cerebral circulation correlates well with several pathologic states of the central nervous system and may be used as a simple test to diagnose and evaluate a variety of vascular disorders.

The video dilution technique has made it possible to determine regional blood flow in different vascular beds during routine angiography [1-4]. Recent reports have assessed carotid blood flow in normal human subjects and in patients with a variety of cerebrovascular diseases [5-8]. The video dilution technique has been thoroughly tested in hydrodynamic flow models and validated in animal models. The mean differences between electromagnetic flow readings and videodensitometric values has been reported as less than 2% with a correlation coefficient of 0.96 [3].

It has long been recognized that angiographic contrast material is a potent vasodilator in several vascular beds such as the extremity circulation and the splanchnic circulation [9, 10]. By recording the flow changes measured at specific time intervals after a series of small test injections of contrast medium, it is possible to determine deviations from the normal vascular response, characteristic for various abnormalities. The normal hyperemic response in the extremity circulation is severely decreased in arterial obstructive disease, and the level of flow response is correlated with the severity of the disease [10, 11]. The normal response to contrast material in the renal circulation is a decrease in flow. In patients with hypertension and unilateral renovascular disease, there is an increase in blood flow to the unprotected healthy kidney [4]. In such cases, a series of small amounts of contrast material injected intraarterially has proven to be of great clinical value. This is a report of our first clinical experiences in measuring the cerebral response to angiographic contrast material, using a technique previously applied to other vascular regions [1, 3, 7].

Subjects and Methods

Carotid blood flow response to the angiographic contrast medium Conray-60 (Mallinckrodt, St. Louis) was studied in 26 subjects (19 males and 7 females, aged 13-80 years; mean age, 52 years) during routine neuroangiography. With a catheter placed in the common or internal carotid arteries, contrast material was injected serially in 1 ml amounts at 0, 30, 60, and 90 sec. The dilution of the contrast material was recorded during fluoroscopy over the carotid arteries on a video cassette recorder (Sony Umatic) and processed according to the video dilution technique with a solid-state and fully digitized densitometer (Angiotec Corp., Berkeley) connected to a minicomputer (Apple II). The blood flow at 30, 60, and 90 sec, respectively, was then compared with the flow at time 0 and expressed as percentage of the baseline flow (= 100%).

Results

Seven subjects were considered normal by computed tomographic, angiographic, and clinical criteria at the time of the study. At 30 sec after a 1 ml injection of Conray-60, an increase in carotid blood flow was observed in these patients (mean, 113.5%; SD \pm 15.5%). In contrast, a decrease in carotid flow at 30 sec was observed in a group of nine patients with ulcerative and stenotic atheromatous disease (mean, 78.8%; SD \pm 12.7%) (fig. 1). There was a statistically significant difference between the two groups ($p < 0.01$). All test series in the atheromatous group were performed in the common carotid artery. In the normal group, three test series were performed in the internal carotid (mean flow at 30 sec, 126%; SD \pm 12.9%) and the other four series were performed in the common carotid (mean, 104%; SD \pm 10.3%). There was a significant difference between the two subgroups of normal controls tested in the internal and the common carotid arteries, respectively, and also between the latter group and the atheromatous patients, both tested in the common carotid artery ($p < 0.01$). Flow response at 30 sec in patients with a variety of central nervous system disorders is illustrated in figure 2. In three patients with intracranial avascular masses, a significant decrease in flow at 30 sec (mean, 85%; SD \pm 11%) was observed as compared with normal controls. The hemispheric difference in flow response after bilateral internal carotid test series in a patient with a left avascular mass is illustrated in figure 3. There was no significant difference in flow response at 30 sec between the group of three patients with aneurysms and the normal group.

¹All authors: Department of Radiology, Division of Diagnostic Radiology, University of California Davis Medical Center, 4301 X St., Sacramento, CA 95817. Address reprint requests to A. B. Dublin.

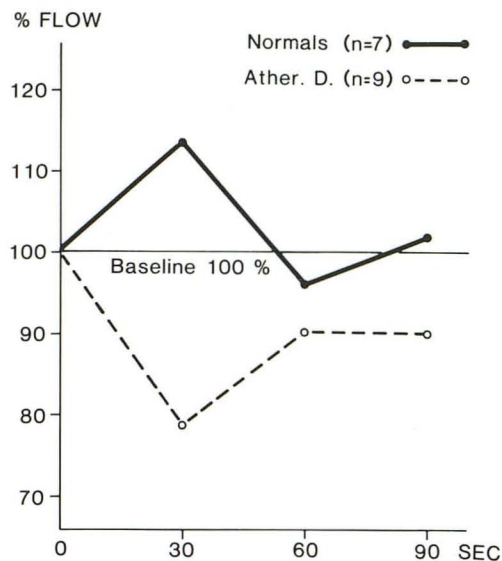


Fig. 1.—Carotid blood flow response to series of 1 ml injections of Conray-60 at 0, 30, 60, and 90 sec in seven normal controls and nine patients with atheromatous disease.

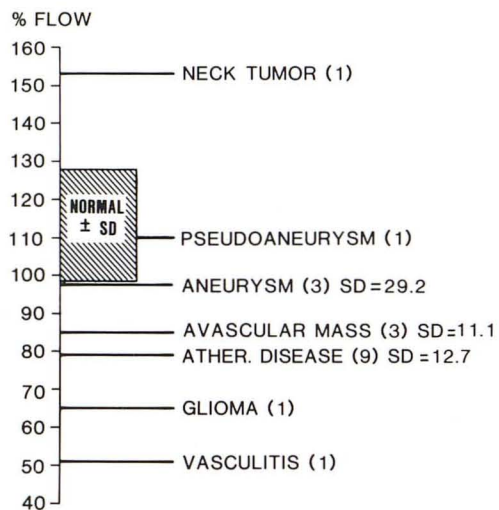


Fig. 2.—Carotid blood flow response 30 sec postinjection of 1 ml Conray-60 in a variety of confirmed central nervous system disorders compared with normal controls. Number of cases in parentheses. Mean value indicated for disorders represented by more than one case (SD = standard deviation).

Discussion

A variety of noninvasive or relatively noninvasive tests for the measurement of carotid blood flow have been described [12–15]. However, the video dilution technique is the only reliable and accurate method of measuring relative carotid blood flow in the clinical setting [5–8]. This technique has been described in detail and extensively reviewed [1, 5–8]. We used the video dilution technique to evaluate the vasoactive effect of Conray-60 on carotid blood flow in normal controls and patients with a variety of vascular disorders.

In normal controls the carotid blood flow showed an increase to 113.5% at 30 sec with a return to baseline levels by 60 sec after a 1 ml injection of Conray-60 (fig. 1). This was similar to the response

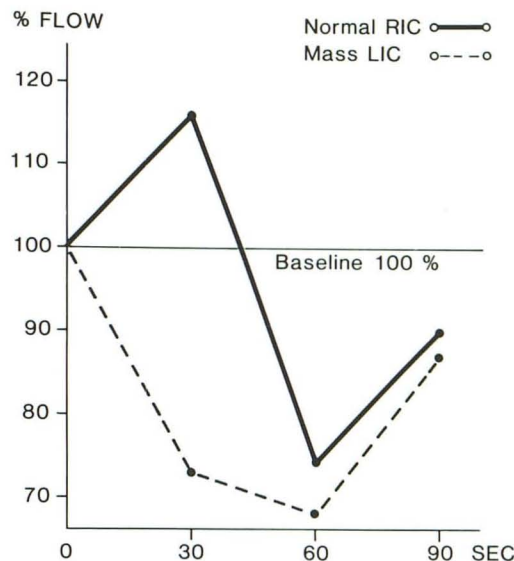


Fig. 3.—Bilateral carotid blood flow response to series of 1 ml injections of Conray-60 in 23-year-old woman with left arachnoidal cyst and hypoplasia of opercular branches of left internal carotid. Normal response at 30 sec noted in right hemisphere (RIC = right internal carotid; LIC = left internal carotid).

that Ulano et al. [16] found in the canine model, that is, 123% of baseline at 20 sec postinjection. However, the simple vasodilator effect observed with Conray-60 was not found with other contrast agents studied by the same researchers. Agents such as Hypaque (diatrizoate meglumine 60%; Winthrop) and Urokon (Mallinckrodt) were injected into the common carotid artery in the dog and produced an initial decrease in cerebral blood flow after 2–3 sec [16]. This effect lasted for about 30 sec and was followed by a return to baseline levels and an increase in cerebral flow lasting 30–60 sec. The researchers believed the initial decrease in flow was secondary to systemic bradycardia and hypotension; they attributed the subsequent elevation in flow to a vasodilatation response of the cerebral vasculature to the contrast material [16].

The effect of Conray-60 in our normal control group was significantly different from the effect observed in our series of patients with angiographically demonstrable atherosclerotic vascular disease (fig. 1). In the latter group, a mean decrease in common carotid blood flow was observed at 30 sec. This decrease in blood flow appeared to be more pronounced in older patients and correlated with the degree of severity of stenotic disease.

A significant decrease in carotid blood flow was also noted in patients with intracranial avascular masses as compared with normal controls (figs. 2 and 3). The reason for this is unclear. Kawase et al. [17] studied a group of stroke patients and concluded that a defect in the blood-brain barrier occurs in these cases. However, extravasation of contrast material through the blood-brain barrier on infarction may not occur acutely. Kawase postulates a delayed effect attributable to a decrease in vessel luminal diameter secondary to the mechanical effect of brain edema on cerebral vascular cell volume [17]. It may be that a similar mechanical constriction occurs in intracranial avascular masses, accentuated by the confines of the cranial vault. A decrease in cerebral vascular volume would reverse the normal brain vasodilator response to contrast media, resulting in a decrease in cerebral blood flow at 30 sec after injection of Conray-60, as observed in our small group of patients with avascular masses.

Our small series of patients with aneurysmal rupture and moderate angiographic arterial spasm showed little difference from

normal controls in carotid blood flow response at 30 sec after injection (fig. 2). This preliminary finding suggests the presence of some vasodilatation reserve in the cerebral vasculature, even in the face of moderate vascular spasm. It is possible that video dilution tests of this type may be useful in determining which patients with vascular spasm are appropriate candidates for surgical exploration and aneurysmal clipping.

The other four patients in the study group represented one case of granulomatous vasculitis; a vascular neck tumor; a traumatic pseudoaneurysm of the common carotid; and an angiographically diagnosed vascular cerebral glioblastoma. In the case of the vascular neck tumor, a marked increase in carotid blood flow was observed at 30 sec after injection of Conray-60. In contrast, the case of vascular glioblastoma showed a decrease in flow at 30 sec with a response similar to that seen with avascular masses. This suggests that the predominant factor in determining the flow response to Conray-60 is the mass effect of the tumor rather than its vascular appearance on computed tomography or angiography.

In summary, the vasoactive effect of Conray-60 as measured by the video dilution technique resulted in a definite increase in carotid blood flow in the normal population at 30 sec postinjection, but a significant decrease at this time interval in patients with atheromatous disease and intracranial avascular masses. The vasoactive effect of Conray-60 differed in a variety of central nervous system disorders and may have diagnostic and/or therapeutic implications for atheromatous disease, intracranial pressure and mass effect, arterial spasm, and tumor vascularity.

REFERENCES

1. Lantz BMT. Relative flow measured by roentgen videodensitometry in hydrodynamic model. *Acta Radiol [Diagn]* (Stockh) **1975**;16:503-519
2. Lantz BMT, Link DP, Foerster JM, Holcroft JW. Angiographic determination of splanchnic blood flow. *Acta Radiol [Diagn]* (Stockh) **1980**;21:3-10
3. Lantz BMT, Foerster JM, Link DP, Holcroft JW. Determination of relative blood flow in single arteries: new video dilution technique. *AJR* **1980**;134:1161-1168
4. Link DP, Stanton CJ, Lantz BMT. Renal flow response to contrast medium measured by video dilution technique. *Acta Radiol [Diagn]* (Stockh) **1981**;22:641-644
5. Lantz BMT, Foerster JM, Link DP, Holcroft JW. Angiographic determination of cerebral blood flow. *Acta Radiol [Diagn]* (Stockh) **1980**;21:147-153
6. Lantz BMT, Dublin AB, McGahan JP, Link DP. Assessment of cerebral blood flow in man by video dilution technique: a preliminary report. *Invest Radiol* **1981**;16:181-187
7. Lantz BMT, Dublin AB, McGahan JP, Link DP. Carotid blood flow in man determined by video dilution technique. I. Theory, procedure, and normal values. *AJNR* **1981**;2:511-516
8. Lantz BMT, Dublin AB, McGahan JP, Link DP. Carotid blood flow in man determined by video dilution technique. II. Vascular abnormalities. *AJNR* **1982**;3:295-303
9. Dedichen H, Myhre HO. Reactive hyperemia of the human lower limb. *Acta Chir Scand* **1975**;141:517-521
10. Link DP, Foerster JM, Lantz BMT, Holcroft JW. Assessment of peripheral blood flow in man by video dilution technique. A preliminary report. *Invest Radiol* **1981**;16:298-304
11. Link DP, Lantz BMT. Vasodilator response in the lower extremity induced by contrast medium. I. Canine model. *Acta Radiol [Diagn]* (Stockh) **1982**;23:81-86
12. Rutishauser W. Application of roentgen densitometry to blood flow measurement in models, animals and in intact conscious man. In: Heintzen PH, ed. *Roentgen-, cine- and videodensitometry*. Stuttgart: Thieme, **1971**:108-118
13. Rosen L, Silverman NR. Videodensitometric measurements of blood flow using cross-correlation techniques. *Radiology* **1973**;109:305-310
14. Hilal SK. Cerebral hemodynamics assessed by angiography. In: Newton TH, Potts DS, eds. *Radiology of the skull and brain*. St. Louis: Mosby, **1974**:1049-1085
15. Roberts VC, Saing AJ. Ultrasonic Doppler velocity. In: Rolfe P, ed. *Noninvasive physiological measurements*. London: Academic Press, **1979**:153-174
16. Ulano HB, Ascanio G, Rice V, O'Hern R, Houmas E, Oppenheimer MJ. Effects of angiographic contrast media and hypertensive saline solutions on cerebral venous outflow in autoregulating brains. *Invest Radiol* **1970**;5:518-533
17. Kawase T, Mizukami M, Araki G. Mechanisms of contrast enhancement in cerebral infarction: computerized tomography, regional cerebral blood flow, fluorescein angiography, and pathological study. In: Carney AL, Anderson EM, eds. *Advances in neurology. Diagnosis and treatment of brain ischemia*. New York: Raven, **1981**:149-158