



## Discover Generics

Cost-Effective CT & MRI Contrast Agents



WATCH VIDEO

# AJNR

### **Benign suprasellar cysts: the CT approach.**

E A Armstrong, D C Harwood-Nash, H Hoffman, C R Fitz, S Chuang and H Pettersson

*AJNR Am J Neuroradiol* 1983, 4 (2) 163-166  
<http://www.ajnr.org/content/4/2/163>

This information is current as  
of June 22, 2025.

# Benign Suprasellar Cysts: The CT Approach

Edward A. Armstrong<sup>1, 2</sup>  
 Derek C. F. Harwood-Nash<sup>1</sup>  
 Harold Hoffman<sup>3</sup>  
 Charles R. Fitz<sup>1</sup>  
 Sylvester Chuang<sup>1</sup>  
 Holger Pettersson<sup>1</sup>

Preoperative diagnosis of intracranial cysts has been simplified and made more rapid and accurate with computed tomography (CT). By means of conventional CT and CT metrizamide ventriculography, the position and communication of intracranial cysts with the ventricular system and subarachnoid space or cisterns can be demonstrated. Suprasellar arachnoid cysts can produce significant neurologic and endocrinologic abnormalities due to their position. They are a surgically curable cause of hydrocephalus. Preoperative differentiation from aqueduct stenosis or other causes of a large third ventricle is important. The usefulness of coronal CT and CT metrizamide ventriculography in the investigation of these lesions is illustrated in six patients.

Subarachnoid cysts account for about 1% of all intracranial space-occupying lesions, and in order of decreasing frequency these cysts are situated in the middle fossa, parietal convexity, posterior fossa, collicular region, and suprasellar regions [1-12]. Suprasellar cysts represent a small but surgically significant proportion of intracranial space-occupying lesions. Most suprasellar cysts are of subarachnoid origin, but a small number of cysts arising from the ependyma or choroid plexus within the third ventricle have also been reported [1-11].

The clinical signs and symptoms of suprasellar cysts can be classified: hydrocephalus, visual impairment, and endocrine dysfunction. Hydrocephalus is the most common presentation in infancy. These patients are noted to have a rapidly increasing head circumference, delayed development, and visual inattentiveness. Visual impairment as a result of pressure by the space-occupying lesion on the optic chiasm or optic tract, associated with varying degrees of optic atrophy and visual fields defects are more common in early childhood. In older children and in adults, endocrine dysfunction [10] may occur with or without concomitant hydrocephalus or visual impairment due to involvement of the hypothalamic-hypophyseal axis. Other neurologic symptoms [1-13] include ataxia, head bobbing [4, 14], intension tremor, choreoathetosis, ptosis, and Parinaud syndrome.

In only eight previously reported suprasellar arachnoid cysts [1, 5-8, 12, 13] was CT performed prior to surgery. We report another six patients with suprasellar arachnoid cysts who had CT preoperatively. A CT diagnostic protocol is suggested.

## Materials and Methods

Six patients, four boys and two girls with cystic, cerebrospinal fluid (CSF) density lesions in the suprasellar area, were evaluated between 1976 and 1980 at the Hospital for Sick Children. All six patients had surgically and pathologically proven suprasellar arachnoid cysts. The patients were 7 months to 9¼ years old (mean age, 3½ years). All had increased head circumference on initial clinical evaluation. Three patients, all 3 years or younger, had ataxia, and three patients, all older than 3 years, had evidence of visual impairment.

Received June 23, 1981; accepted September 24, 1982.

<sup>1</sup> Department of Radiology, Division of Special Procedures and Neuroradiology, Hospital for Sick Children, 555 University Ave., Toronto, Ontario M5G 1X8, Canada. Address reprint requests to D. C. F. Harwood-Nash.

<sup>2</sup> Present address: Department of Radiology, Children's Medical Center, Dallas, TX 75235.

<sup>3</sup> Department of Neurosurgery, Hospital for Sick Children, Toronto, Ontario M5G 1X8, Canada.

**AJNR 4:163-166, March/April 1983**  
 0195-6108/83/0402-0163 \$00.00  
 © American Roentgen Ray Society



None of our patients had evidence of endocrine dysfunction.

All six patients had a skull series and an axial CT scan as their initial neuroradiologic investigation. CT scans were obtained on either the EMI Mark I, Ohio Nuclear Delta-50, or General Electric 8800 CT-T scanners. Four of the six had additional coronal CT and three had metrizamide ventriculography by direct insertion of the contrast material through a ventriculoperitoneal shunt. Two of these three had CT after metrizamide insertion (CT metrizamide ventriculogram) to further evaluate the suprasellar cysts. In one patient initial CT before the availability of metrizamide showed a suprasellar low density, while air cisternography showed air entering the cyst (fig. 1B).

Axial CT demonstrated the suprasellar arachnoid cysts as large, round to oval, midline CSF density structures in the region of the third ventricle and extending inferiorly into the suprasellar region (fig. 2). This characteristic appearance was described previously by Murali and Epstein [8], and a similar appearance is seen in aqueduct stenosis but the third ventricle is usually not as large. Furthermore in aqueduct stenosis posterior tapering of the third ventricle is apparent on higher cuts. It has been reported [8] that the suprasellar cyst characteristically has rounding of both the anterior and posterior aspects (fig. 2A, 3A, and 4B) with compression and flattening of the upper brainstem and colliculi (fig. 3A). In some instances, however (fig. 4A), there is tapering of the posterior aspect of the cyst similar to the tapering of the third ventricle in aqueduct stenosis, suggesting that the CT appearance of the cysts cannot be differentiated from the enlarged third ventricle of aqueduct stenosis.

Four of the six patients had a direct coronal CT. The coronal view

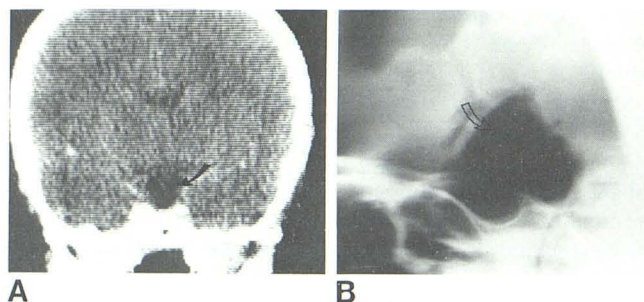


Fig. 1.—A, Coronal CT on second-generation scanner shows separation of cyst (arrow) from region of foramen of Monro. Because distinction between normal cistern and cyst could not be determined, ventriculography was performed. B, Air cisternogram demonstrates cyst filled with air (arrow).

(fig. 1A) showed the separation of the cyst from the foramen of Monro and lateral ventricles in one patient. However, in the other three patients who had coronal CT the cyst was very large, extended upward, and produced obstruction of the foramen of Monro so that the CT appearance was indistinguishable from an aqueduct stenosis. The third ventricle was displaced so far superiorly that the cyst was not discernible as a separate structure from it (figs. 3B and 4B).

In the three patients with ventriculoperitoneal shunts placed for treatment of their associated hydrocephalus, a small amount of metrizamide (2–4 mm of 180–210 mg I/ml) was placed in the lateral ventricles through the shunt. Conventional radiographs (fig. 3C) were obtained in all, and in two patients axial CT scans were obtained also. Metrizamide ventriculography showed that the attenuation of the cyst remained unchanged, thus establishing that there was no communication between the ventricular system and the cyst (fig. 4C). Due to the difficulty in positioning during general anesthesia, coronal views of the metrizamide ventriculogram were not feasible. However, this method may have been able to separate clearly the third ventricle from the cyst.

## Discussion

In the past, the suprasellar arachnoid cyst was defined by invasive procedures such as angiography, pneumoenceph-

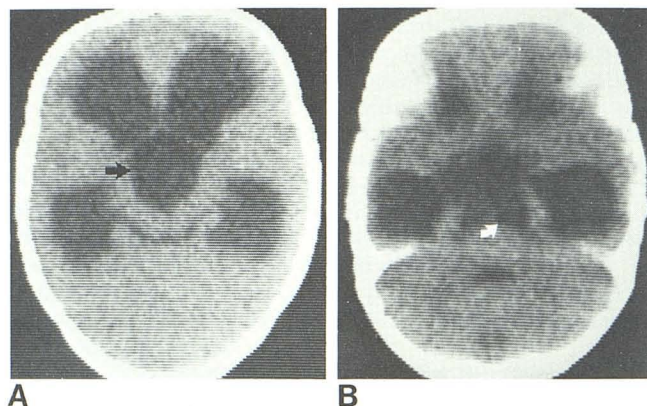


Fig. 2.—Cyst (arrows) producing hydrocephalus and extending down into suprasellar cistern. Rounding of posterior wall of third ventricle and flattening of anterior aspect of colliculi.

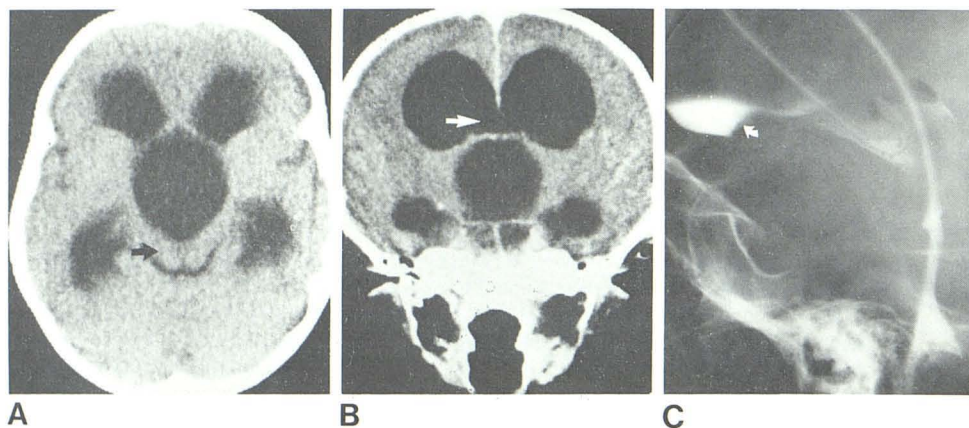
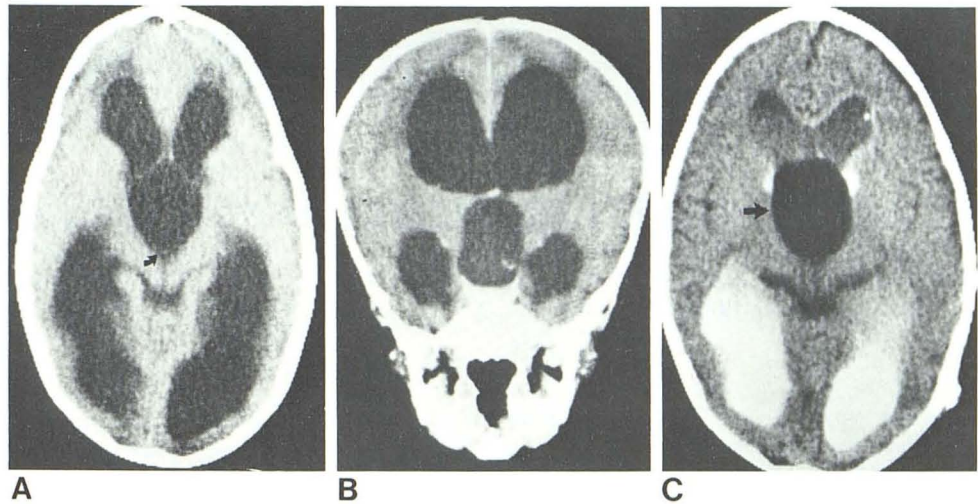


Fig. 3.—A, Axial CT scan shows hydrocephalus, rounding of posterior aspect of cyst, and flattening of colliculi (arrow). B, Coronal scan with large cyst displacing foramen of Monro upward (arrow) producing obstructive hydrocephalus. Third ventricle was not discernible. C, Metrizamide ventriculogram shows round mass effect (arrow) on floor of posterior third ventricle. Metrizamide did not enter cyst.



Fig. 4.—Axial (A) and coronal (B) CT scans. Third ventricle was not seen separate from cyst. Tapering of posterior aspect of cyst (arrow) is indistinguishable from that seen with enlargement of third ventricle secondary to aqueduct stenosis. C, CT metrizamide ventriculogram shows metrizamide in lateral ventricles but not in cyst (arrow). Cyst still measures normal CSF density compared with increased attenuation in ventricles.



alography, and ventricular needle air ventriculography. CT and metrizamide ventriculography have offered a simpler, less invasive, two step approach to preoperative diagnosis.

The CT scan demonstrates the cystic nature of the lesion. Usually the attenuation coefficient of the contents of the cyst are near that of CSF. The rounded shape of the posterior aspect of the cyst reported previously is not a helpful differentiating point between the suprasellar cyst and the enlarged third ventricle. The use of coronal positioning or coronal reconstruction may make it possible to separate the suprasellar cyst from the third ventricle. However, when the suprasellar cyst is large and displacing the third ventricle upward, neither axial nor coronal CT may be able to distinguish between cyst and enlarged third ventricle. Flattening of the upper anterior brainstem or colliculi by the suprasellar cyst may prove to be a helpful differentiating feature.

The introduction of metrizamide either directly into a ventriculoperitoneal shunt or through a needle placed in the lateral ventricles followed by a CT scan may become necessary to distinguish between the suprasellar cyst and the enlarged third ventricle. When there is hydrocephalus secondary to a suprasellar cyst, if the foramen of Monro is obstructed metrizamide remains in the lateral ventricles. This can be defined by CT. With aqueduct stenosis or obstruction, the contrast agent diffuses throughout the lateral ventricular system into a dilated third ventricle and proximal aqueduct.

The CT differential diagnosis of the suprasellar arachnoid cyst includes: the enlarged third ventricle secondary to aqueduct stenosis or communicating hydrocephalus, intraventricular cyst, craniopharyngiomas, suprasellar epidermoids, and nonenhancing glial tumors. Craniopharyngioma can usually be easily differentiated by calcification in the tumor or the capsule of the cyst and also by the higher CT attenuation of these tumors. Suprasellar epidermoids are uncommon in children and the metrizamide cisternography in several of our examples of this tumor have shown a characteristic pattern of the irregularity of the tumor wall being outlined by metrizamide within the interstices of the

tumor. Low-density, non-enhancing gliomas usually have an attenuation value much higher than CSF and the cyst glioma may have an enhancing rim that helps in differentiating it from the suprasellar arachnoid cyst. An intraventricular cyst may be indistinguishable from a suprasellar arachnoid cyst.

Therefore, we suggest the following CT protocol in the evaluation of the suprasellar arachnoid cyst. When the initial CT scan of a patient with hydrocephalus suggests a suprasellar arachnoid cyst, an attempt must initially be made to differentiate this from an enlarged third ventricle. The rounded appearance of the posterior aspect of the cyst may not be apparent on higher cuts and the posterior aspect of the cyst can be indistinguishable from the normal tapering of the posterior aspect of the third ventricle. In such a situation coronal CT or coronal reconstruction should be next attempted to separate the cyst from the third ventricle. Differentiation at this time still may not be possible. It is under these circumstances that CT metrizamide ventriculography plays a key role in the neuroradiologic workup. After a ventriculoperitoneal shunt is placed to alleviate the hydrocephalus or after a diagnostic ventricular puncture, a small amount (2–4 mm) of isotonic metrizamide placed in the lateral ventricles followed immediately by CT can assist in differentiating between a suprasellar arachnoid cyst and an enlarged third ventricle secondary to aqueduct stenosis or communicating hydrocephalus.

#### REFERENCES

1. Anderson FM, Segall HD, Paton WL. Use of computerized tomography scanning in supratentorial arachnoid cysts—a report on 20 children and 4 adults. *J Neurosurg* 1979;50:323–338
2. Choux M, Rabaud C, Pinsard N, Hassoun J, Gambarelli D. Intracranial supratentorial cysts in children excluding tumour and parasitic cysts. *Childs Brain* 1978;4:15–32
3. Contreras C, Coptly M, Langelier R, Gagne F. Traumatic suprasellar arachnoid cyst. *Surg Neurol* 1977;8:196–198
4. Jensen H, Pendl G, Goerke F. Head-bobbing in a patient with a cyst of the third ventricle. *Childs Brain* 1978;4:235–241

5. Kasdon DL, Douglas EA, Brougham MF. Suprasellar arachnoid cyst diagnosed pre-operatively by computerized tomographic scanning. *Surg Neurol* **1977**;7:299-303
6. Lee BCP. Intracranial cysts. *Radiology* **1979**;130:667-674
7. Leo JS, Pinto RS, Hulvat GF, Epstein F, Kricheff II. Computed tomography of arachnoid cysts. *Radiology* **1979**;130:675-680
8. Murali R, Epstein F. Diagnosis and treatment of suprasellar arachnoid cyst—report of 3 cases. *J Neurosurg* **1979**;50:515-518
9. Palma L. Supratentorial neuroepithelial cyst—report of 2 cases. *J Neurosurg* **1975**;42:353-357
10. Sansregret A, Ledoux R, Duplantis F, et al. Suprasellar arachnoid cysts—radioclinical features. *AJR* **1969**;105:291-297
11. Seagall HD, Hassan G, Ling SM, Carton C. Suprasellar cysts associated with isosexual precocious puberty. *Radiology* **1974**;111:607-616
12. Wirt TC, Hester RW. Suprasellar arachnoid cysts. *Surg Neurol* **1978**;9:322
13. Handa J, Nakano Y, Heiha A. CT Cisternography with intracranial arachnoid cysts. *Surg Neurol* **1977**;8:451-454
14. Benton JW, Nellhaus G, Huttenlocher PR, Ojeman RG, Dodge PR. The bobble-head doll syndrome. *Neurology (NY)* **1966**;16:725-729