



Discover Generics

Cost-Effective CT & MRI Contrast Agents



FRESENIUS
KABI

WATCH VIDEO

AJNR

Functional anatomy of the facial vasculature in pathologic conditions and its therapeutic application.

A Berenstein, P Lasjaunias and I I Kricheff

AJNR Am J Neuroradiol 1983, 4 (2) 149-153

<http://www.ajnr.org/content/4/2/149>

This information is current as
of June 23, 2025.

Functional Anatomy of the Facial Vasculature in Pathologic Conditions and its Therapeutic Application

Alex Berenstein¹
 Pierre Lasjaunias^{1,2}
 Irvin I. Kricheff¹

The authors describe the functional anatomy of the facial vascular system, using the anastomoses between the facial, maxillary, transverse facial, lingual, and ophthalmic systems to selectively identify the blood flow to a specific territory for embolization and posttreatment evaluation of hemangiomas. In three patients the specific vascular patterns are described and the usefulness of understanding the regional functional anatomy is illustrated for successful embolotherapy of these malformations.

The normal anatomy of the facial artery, its variations, and its anastomoses have been reported [1]. The facial artery gives rise to arterial branches, which are the nourishing vessels to a specific territory, such as the upper lip (i.e., the superior labial artery). The number and size of the various nourishing arteries are anatomic elements of local territories. Genetic and developmental factors initially determine the anatomy and hemodynamic balance, as vascular regressions and recruitments progress differently in each individual, and on each side of the face in the same individual. Subsequently, the "normal" pattern for an individual may become modified by stenotic lesions, hypervascular conditions, surgical ligations, or embolizations. These factors affect the anatomic arrangements and the hemodynamics of territorial blood supply.

Understanding local vascular anatomy, anastomoses, and hemodynamics [1] is critically important for the understanding of pathologic conditions and for planning their treatment by either intravascular or surgical techniques. The anatomic and hemodynamic balance that the facial artery has with the ipsilateral internal maxillary, transverse facial, ophthalmic, and lingual arteries through anastomotic channels is termed the functional anatomy of the facial artery. Where one of these arteries is hypoplastic or occluded, the others will be proportionally larger and supply a larger territory; however, points of collateral anastomoses remain constant [1]. The contralateral circulation normally does not contribute significantly to the functional anatomy, but may do so when the ipsilateral supply is deficient.

We describe the use of functional anatomy, which takes into consideration arterial size, volume, direction of blood flow, and anastomosis in the evaluation and treatment of pathologic conditions. Modifications in traditional arterial patterns produced by high-flow lesions, surgical ligation, or incomplete embolization may then be anticipated and utilized.

A given arterial territory will recruit one or several possible collateral pathways to sustain perfusion despite proximal obstruction whatever the cause. During selective angiography, the lack of opacification of a specific nourishing artery should direct the investigation to the other potential feeding collaterals, rather than the mistaken assumption of total arterial occlusion.

Received December 8, 1981; accepted after revision September 30, 1982.

Presented at the annual meeting of the American Society of Neuroradiology, Los Angeles, March 1980.

¹Department of Radiology, Bellevue Hospitals, and New York University Medical Center, 550 First Ave., New York, NY 10016. Address reprint requests to A. Berenstein.

²Present address: Service de Radiologie, Hôpital du Kremlin Bicêtre, Paris, France.

AJNR 4:149-153, March/April 1983
 0195-6108/83/0402-0149 \$00.00
 © American Roentgen Ray Society

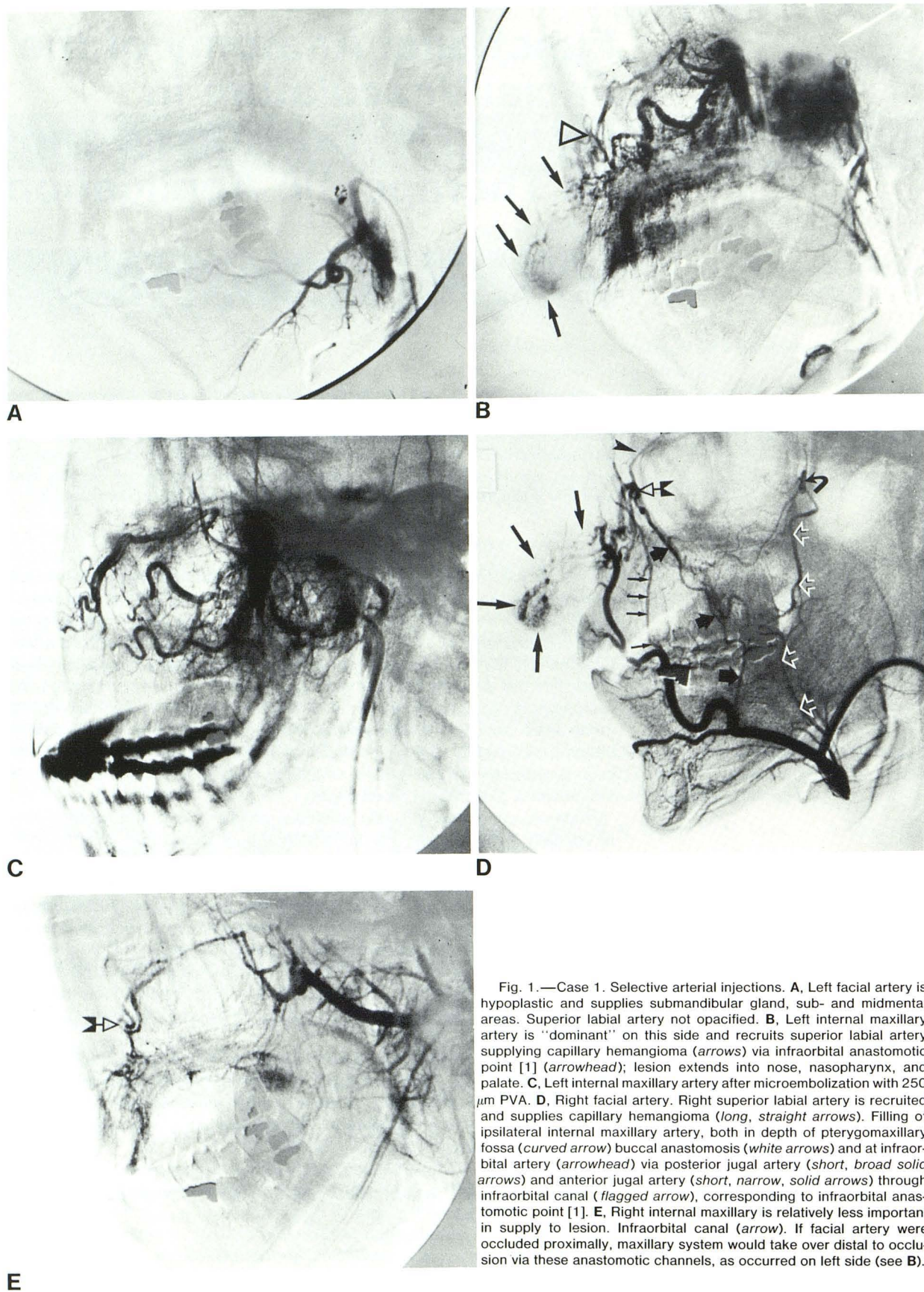


Fig. 1.—Case 1. Selective arterial injections. **A**, Left facial artery is hypoplastic and supplies submandibular gland, sub- and midmental areas. Superior labial artery not opacified. **B**, Left internal maxillary artery is "dominant" on this side and recruits superior labial artery supplying capillary hemangioma (arrows) via infraorbital anastomotic point [1] (arrowhead); lesion extends into nose, nasopharynx, and palate. **C**, Left internal maxillary artery after microembolization with 250 μ m PVA. **D**, Right facial artery. Right superior labial artery is recruited and supplies capillary hemangioma (long, straight arrows). Filling of ipsilateral internal maxillary artery, both in depth of pterygomaxillary fossa (curved arrow) buccal anastomosis (white arrows) and at infraorbital artery (arrowhead) via posterior jugal artery (short, broad solid arrows) and anterior jugal artery (short, narrow, solid arrows) through infraorbital canal (flagged arrow), corresponding to infraorbital anastomotic point [1]. **E**, Right internal maxillary is relatively less important in supply to lesion. Infraorbital canal (arrow). If facial artery were occluded proximally, maxillary system would take over distal to occlusion via these anastomotic channels, as occurred on left side (see **B**).

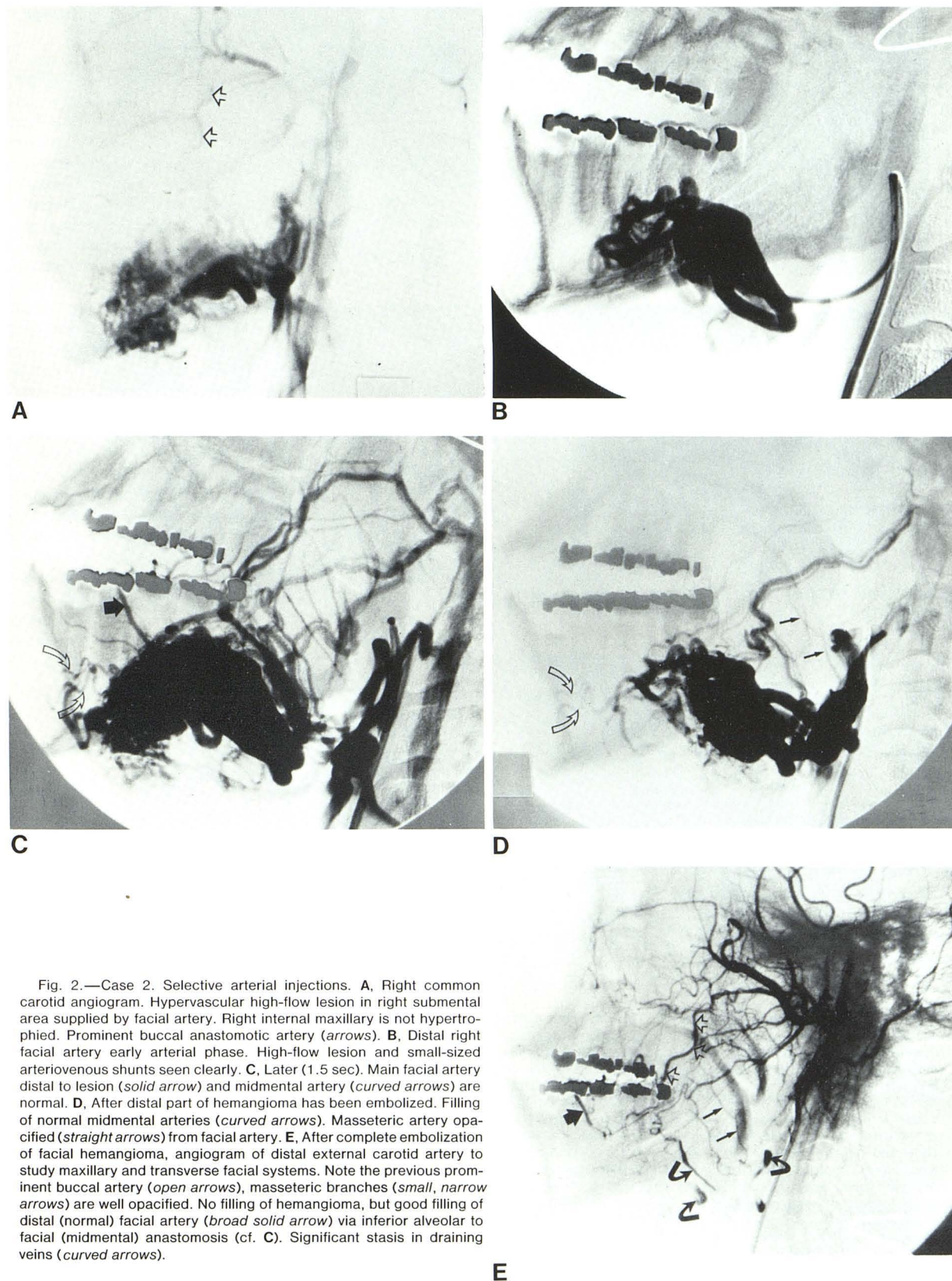


Fig. 2.—Case 2. Selective arterial injections. **A**, Right common carotid angiogram. Hypervascular high-flow lesion in right submental area supplied by facial artery. Right internal maxillary is not hypertrophied. Prominent buccal anastomotic artery (arrows). **B**, Distal right facial artery early arterial phase. High-flow lesion and small-sized arteriovenous shunts seen clearly. **C**, Later (1.5 sec). Main facial artery distal to lesion (solid arrow) and midmental artery (curved arrows) are normal. **D**, After distal part of hemangioma has been embolized. Filling of normal midmental arteries (curved arrows). Masseteric artery opacified (straight arrows) from facial artery. **E**, After complete embolization of facial hemangioma, angiogram of distal external carotid artery to study maxillary and transverse facial systems. Note the previous prominent buccal artery (open arrows), masseteric branches (small, narrow arrows) are well opacified. No filling of hemangioma, but good filling of distal (normal) facial artery (broad solid arrow) via inferior alveolar to facial (midmental) anastomosis (cf. C). Significant stasis in draining veins (curved arrows).

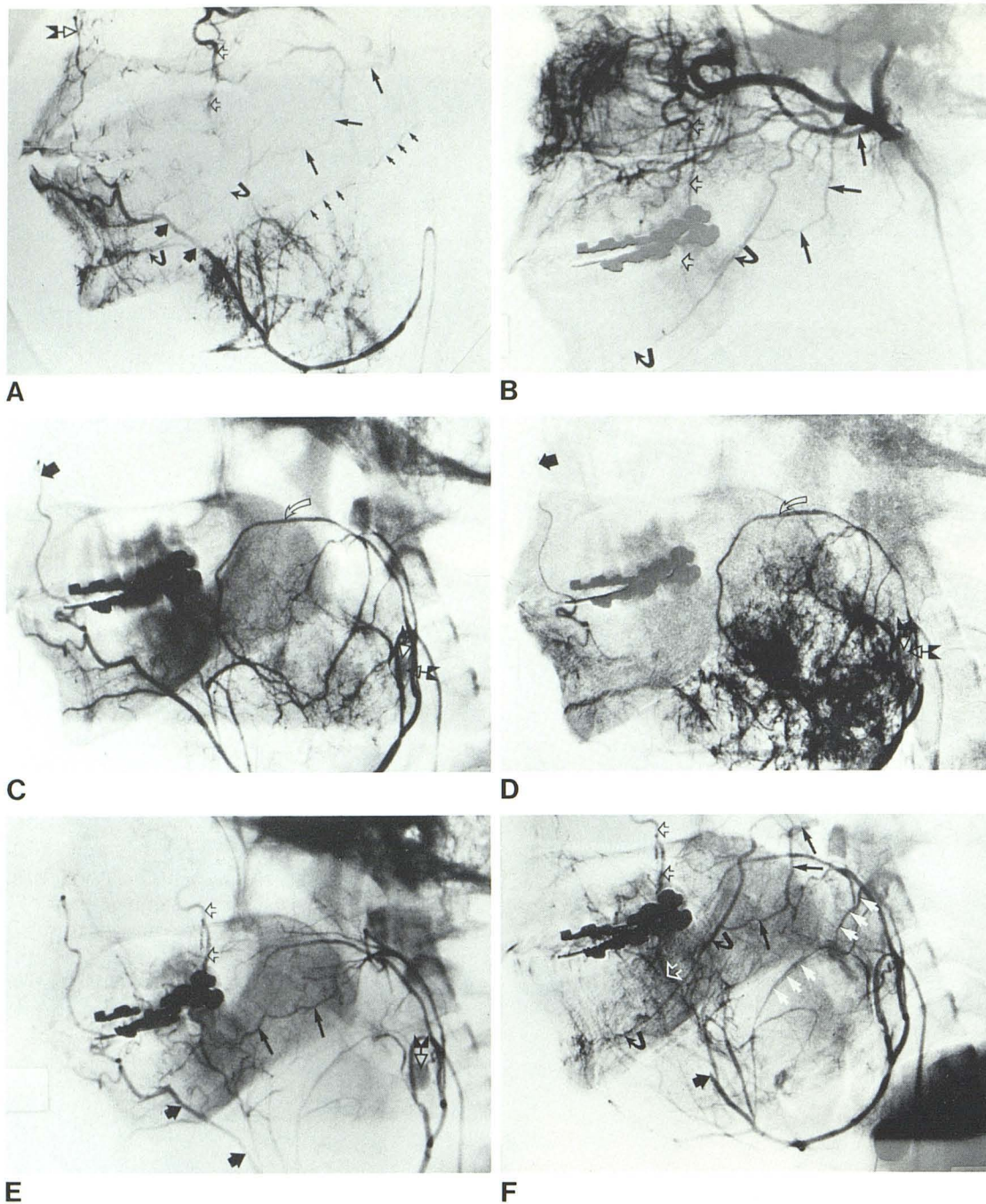


Fig. 3.—Case 3. Selective arterial injections. **A**, Right facial artery of normal caliber, but displaced downward. Tumor vessel supplies small-channel, slow-flow hemangioma. Filling of transverse facial system (*long, straight arrows*) and inferior alveolar artery (*curved arrows*), anastomosing facial system to proximal internal maxillary system. Buccal anastomosis (*open arrows*) fills internal maxillary artery at pterygomaxillary fossa. Distal facial artery (*broad arrows*) fills infraorbital canal (*flagged arrow*) at infraorbital anastomotic point. Anastomosis between inferior masseteric and superior masseteric arteries (*small, narrow arrows*) **B**, Distal external carotid injection to study transverse facial arterial system (*straight, solid arrows*) and internal maxillary to facial collaterals. No direct supply to hemangioma. Inferior alveolar artery (*curved arrows*) and buccal anastomosis (*open arrows*) **C**, Right facial artery using double-lumen balloon catheter in proximal facial trunk. Temporary facial artery occlusion produces reversal in flow from transverse facial and internal maxillary toward lesion using same collateral circulation as in **A**. Inflated balloon at proximal facial origin is partly subtracted (*flagged arrows*). Balloon is proximal to origin of ascending palatine artery (*curved arrow*). Filling of lesion and only partial filling of normal facial artery (*broad arrow*) (cf. **A**). **D**, 4 sec later. Further filling of hemangioma and emptying of ascending palatine artery (*curved arrow*) toward lesion without additional filling of normal vessels or opacification of collaterals. Balloon (*flagged arrows*); facial artery (*broad arrow*). **E**, Right facial artery after embolization of tumor vessels with 40–60 μ m particles of Gelfoam. Balloon (*flagged arrow*) still inflated. With same pressure of injection flow is toward transverse facial and maxillary systems via collateral circulation. Tumor bed is occluded and normal territories are preserved. Transverse facial (*long arrows*), buccal anastomosis (*open arrows*) and distal facial artery (*broad arrows*) **F**, Right facial artery after 250–590 μ m particles were used to occlude feeding vessels more proximally to maximize effects of more distal occlusion. Balloon has been deflated. Flow in collateral circulation is toward transverse facial and internal maxillary systems. Good opacification of collateral circulations without opacification of hemangioma. Larger particle was used to protect normal distal facial artery (*short black arrow*), transverse facial (*long black arrows*), inferior alveolar (*curved arrows*), buccal anastomosis (*open arrows*), and inferior to superior masseteric anastomosis (*white arrows*).

Representative Case Reports

Case 1

An 18-year-old woman with a congenital reddish discolorization of the upper lip was referred because of daily nasal bleeds. Physical examination revealed hemangioma of the upper lip extending to both nostrils, left more than right, and to the hard palate.

The functional anatomy of interest in this patient concerns the upper lip, the nasal cavity, nasopharynx, and palate. The upper lip is usually supplied by the facial trunk, but in this case (fig. 1A) the left facial trunk is hypoplastic and supplies only the submandibular gland, submental and midmental territories. However, the left internal maxillary artery (fig. 1B), not the facial, is the dominant arterial trunk on this side, and supplies the superior labial artery, which in turn fills the hemangioma via the infraorbital anastomotic point [1]. The deep extension of this lesion into the nose, nasopharynx, and palate is also demonstrated by the maxillary injection. The left internal maxillary artery is the only left-sided arterial route to reach the lesion if microembolization [2] is contemplated (figs. 1B and 1C).

On the right side, a right facial artery injection (fig. 1D) opacifies the right superior labial artery and also fills the hemangioma. The buccal artery and posterior and anterior jugal anastomotic channels are demonstrated. The right internal maxillary artery (fig. 1E) is of relatively lesser importance but does fill the hemangioma via the infraorbital anastomotic point [1].

Such asymmetry of blood supply in the facial territory is not uncommon and reflects local hemodynamic adaptations. On the right side, if the facial artery were to be ligated or proximally embolized, the right maxillary artery would then supply the upper lip in a similar manner to that on the left side using the infraorbital anastomotic point [1].

Case 2

A high-flow hemangioma supplied by the right facial artery is shown in figure 2. The maxillary artery is not hypertrophied except for prominence of the buccal artery. While a common carotid injection (fig. 2A) demonstrates the lesion, it is inadequate to evaluate the anatomic and hemodynamic characteristics. Selective distal right facial angiography (figs. 2B and 2C) demonstrates that, although the facial artery is hypertrophied and supplies the high-flow hemangioma, the arteriovenous shunts consist of a number of small vessels. This information is important in selecting for treatment small particles that will penetrate deeply into the lesion and stop at these small vessels. The main trunk of the facial artery distal to the lesion is normal, as is the midmental artery (fig. 2C).

The lesion was embolized with polyvinyl alcohol (PVA) particles 250–590 μm in diameter, and results evaluated by injection of the normal midmental artery (fig. 2D). Subsequently the main facial trunk was completely occluded in its proximal part with larger particles to prevent neovascularization [2]. A distal external carotid injection after complete occlusion of the facial artery (fig. 2E) opacifies the transverse facial and maxillary arteries. The masseteric and buccal anastomoses are filled up to their site of connection with the main facial trunk, which itself does not fill. The normal facial trunk distal to the lesion is opacified via collateral supply from the inferior alveolar anastomosis. The alteration in hemodynamics demonstrated by these posttherapeutic angiograms documents complete obliteration of the lesion. Had this not been accomplished, a part of the lesion would have filled via the transverse facial and/or maxillary arteries, which could have been used to occlude the remaining lesion. In this case, the angiographic findings corresponded with an immediate and complete clinical disappearance of the hemangioma.

Case 3

A small vessel, hypervascular, slow-flow hemangioma supplied by a normal-sized main facial trunk and masseteric branches is shown in figure 3. The pressure of the injection results in antegrade anastomotic opacification of the transverse facial and maxillary systems, without filling of the main external carotid trunk. A distal external carotid injection also fills these vessels but does not opacify the hemangioma (fig. 3B). Temporary balloon occlusion of the main facial artery results in a reversal of flow from the transverse facial and maxillary systems toward the facial territory (figs. 3C and 3D). This modification of hemodynamics permits selective embolization of the hemangioma via gentle facial artery injection while a reverse flow prevents undesired occlusion of the transverse facial and maxillary systems, which would have occurred in the presence of the unmodified flow patterns (fig. 3A). Using these modified hemodynamics, the hemangioma was obliterated with the 40–60 μm Gelfoam particles followed by 250–590 μm particles of PVA (figs. 3E and 3F). High-pressure injection of contrast material fills the transverse facial and maxillary systems in an antegrade manner similar to that seen in figure 3A and demonstrates obliteration of the hemangioma and sparing of the normal territory. In this instance, knowledge of vascular anatomy and hemodynamics allowed selective control of blood flow by balloon catheter for embolizing a lesion, while sparing normal tissue.

Discussion

The precise anatomy of the arteries of the face, their collaterals, points of anastomoses, and the influence these patterns have on the regional hemodynamics is what we have termed functional anatomy. An in-depth knowledge of these factors permits the angiographer to logically plan, evaluate, and embolize complex facial vascular alteration abnormalities, even where circulatory dynamics have been modified by prior intervention. The use of functional anatomic principles permits the interventional radiologist to select the best vessels to reach an abnormal territory; to isolate a lesion from the general circulation for treatment, without fear of producing unwanted occlusion of a vessel supplying normal territories; and to modify patterns of blood flow to suit the needs of the procedure. Functional anatomy, that is, the appreciation and alteration of vascular variations [3] and hemodynamics for transarterial therapy, is a concept applicable to the whole body. Our experience with facial vasculature malformations illustrates its utility.

ACKNOWLEDGMENTS

We thank Jill Tepper for manuscript preparation, Douglas Graeb and Robert Rauktis for medical assistance, and Angel Arce for technical assistance.

REFERENCES

1. Lasjaunias P, Berenstein A, Doyon D. Normal functional anatomy of the facial artery. *Radiology* 1979;133:631–638
2. Berenstein A, Kricheff II. Microembolization techniques of vascular occlusion. Radiologic, pathologic, and clinical correlations. *AJNR* 1981;2:261–267
3. Lasjaunias P. *Craniofacial and upper cervical arteries. Functional, clinical, and angiographic aspects*. Baltimore: Williams & Wilkins, 1981