



Discover Generics

Cost-Effective CT & MRI Contrast Agents

 FRESENIUS
KABI

[WATCH VIDEO](#)

AJNR

Discrepancies between operative and myelographic findings.

J T Wilmink

AJNR Am J Neuroradiol 1983, 4 (1) 92-94

<http://www.ajnr.org/content/4/1/92.citation>

This information is current as
of June 24, 2025.

Discrepancies between Operative and Myelographic Findings

I read with appreciation the paper on bulging lumbar disk by Kieffer et al. [1]. An evaluation such as the authors have performed of the reliability of a number of myelographic signs besides root sheath cutoff is a valuable contribution. Scallionlike widening of the nerve root immediately proximal to the site of compression (Ecoif-fier's "signe du tromblon") is shown to be a most useful indicator of disk prolapse, although this sign is sometimes lacking in L4-L5 lesions (authors' table 1). I believe this is because the S1 root sheath usually emerges from the dural sac well above the level of the L5-S1 disk. An L5-S1 prolapse will therefore compress a nerve root tethered in place by the surrounding root sheath (authors' figs. 5 and 7). The root sheath L5 emerges at, or sometimes even slightly caudal to, the level of the L4-L5 disk, so that in the case of an L4-L5 prolapse the compressed segment of the L5 root is still relatively mobile within the dural sac, and may be displaced or obscured. The authors' figure 4 illustrates this, and also demonstrates another sign that we sometimes find useful in this type of situation, namely, increased distance between the border of the dural sac and the L5 pedicle.

The criterion of an angular deformity of the dural sac will probably present a number of classification difficulties (angular or nonangular deformity?) in borderline cases, as can be seen when the authors' figs. 3 and 6 are compared. A more useful criterion is the extension of dural sac deformity above or below the disk space also mentioned. This finding can however only be reliable if care is taken to angle the x-ray tube craniocaudally so that the central ray is parallel to the disk space of interest. Comparison of Figure 1A with 1E illustrates the effect of parallax on the apparent location of a dural sac deformity relative to the disk space.

Although correlation between myelographic and operative findings are on the whole excellent, there are, as always, discrepancies. The authors' figure 3 is an example. A bulging disk is diagnosed, and this diagnosis is confirmed at operation. Yet it is difficult to relate the operative finding of a mobile root sheath and no impingement by the disk with the myelographic picture of an indentation (at least as angular as in fig. 6, in which a disk prolapse is demonstrated) of the dural sac at L4-L5, cutoff of the left L5 root sheath, and medial displacement of the intrathecal portion of the S1 root. I find it difficult to attribute all these findings to lateral crowding of intrathecal nerve roots as the authors suggest.

An explanation for the discrepancy between myelographic and operative findings may lie in the fact that lumbar myelography is usually performed prone with moderate to marked extension of the lumbar spine, while for laminectomy the patient is usually placed in a position of maximal lumbar flexion. The influence of lumbar

flexion-extension movements upon the myelogram are shown in figures 1A-1D, 1F, and 1G, all of the same patient. Bilateral L5 root sheath cutoff, distal widening of L5 roots, and dural sac deformities are seen at the L4-L5 level in extension, while in flexion the myelographic abnormalities are much less marked; the dural sac deformities have disappeared although bilateral L5 root swelling still prevents contrast filling of the root sheaths. In other cases with less marked root swelling we have seen myelographic abnormalities in extension virtually disappear in flexion.

In effect, figures 1A, 1C, and 1F represent the situation in a routine (prone) myelogram, while figures 1B, 1D, and 1G depict the situation as the surgeon sees it at operation in the same patient. As the lateral films (figs. 1F and 1G) show, there is an anterior dural indentation at L4-L5 with a double contour in extension. In flexion the dural indentation and double contour disappear.

Changes are also seen at the dorsal and dorsolateral dural surfaces, which are displaced anteriorly in extension (see also oblique views). The picture in lumbar extension is similar to the authors' figure 11, illustrating a case of spinal stenosis. In our case, however, compression by ligamentous structures (bulging annulus fibrosus and flaval ligaments) appears to play the major role and bony stenosis seems minimal in view of the picture in flexion and the CT image (fig. 1H).

We have carried out a study of flexion-extension effects upon the dural sac in the lateral myelogram [2] and now routinely include sitting lateral flexion-extension studies in every myelographic examination, with oblique flexion-extension views if indicated. Dorsolateral encroachment by flaval ligaments in extension is not an uncommon finding, especially in patients with root involvement at the L4-L5 level, and is not necessarily related to bony spinal stenosis. In some cases it may be difficult to ascertain whether nerve root compression is due to disk bulging or protrusion, to impingement by flaval ligaments, or to a combination of the two. Careful study of the anterior, posterior, and posterolateral dural margins in the various projections in flexion and extension will usually clarify the relationships and allow reliable prediction of the findings to be expected at operation.

The problem of differentiation between disk bulging and herniation is not new, and it has been stated [3] that there is a gradual transition between the two states. Kieffer et al. do not make it clear whether their criteria for disk herniation include the operative finding of a ruptured annulus fibrosus or are based solely on root compression by a portion of the adjacent disk. If the latter is the case, then the difference between bulging and herniated disk could well equate to the difference between lumbar flexion and lumbar extension.

J. T. Wilmink

University Hospital of Groningen
Groningen, The Netherlands

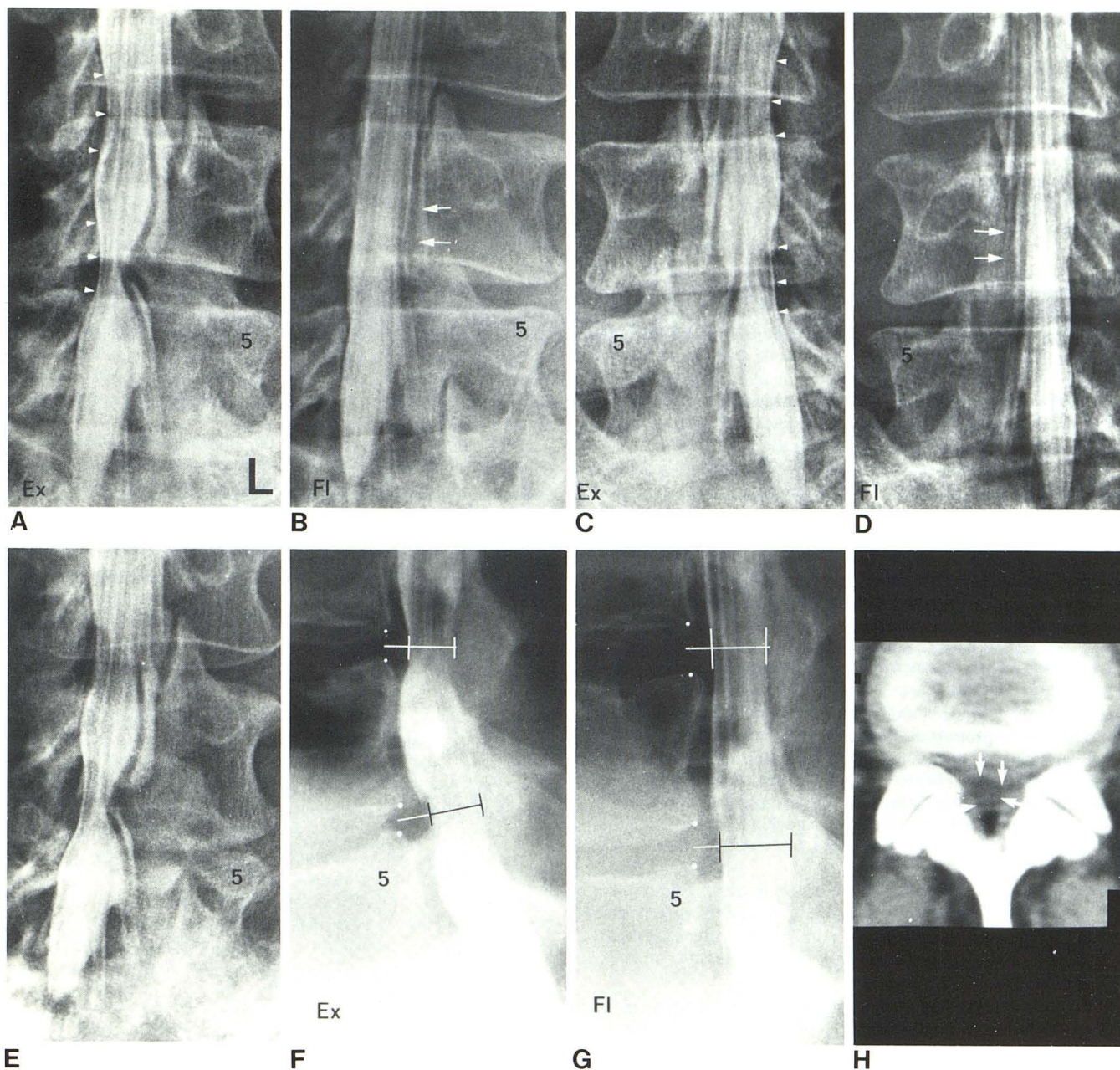


Fig. 1.—Left posterior oblique views of dural end sac in lumbar extension (A) and flexion (B). Similar right posterior oblique views (C and D). Central ray projected parallel to L4–L5 disk space by craniocaudal angulation of tube. Bilateral L5 root sheath cutoff and distal root widening in extension, with dural sac deformities at L4–L5 level. Dorsolateral impressions (arrowheads) on dural sac caused by bulging of flaval ligaments in extension. In flexion, dorsolateral and ventrolateral dural impressions disappear, although there is still nonfilling of both L5 root sheaths, probably due to root swelling

(arrows). E, Left posterior oblique view similar to A, but without craniocaudal angulation. Apparent displacement of dural sac deformity above L4–L5 interspace. Lateral views in extension (F) and flexion (G) show disk bulging and dorsal impression in extension at L3–L4 and L4–L5 interspaces. H, CT section through lower part of L4–L5 disk. Normal bony spinal dimensions. Dural sac is compressed (arrows) anteriorly by asymmetrically bulging disk, and dorsoilaterally by flaval ligaments. Scanogram localization view (not shown) indicated that CT was performed in lumbar extension.

REFERENCES

1. Kieffer SA, Sherry RG, Wellenstein DE, King RB. Bulging lumbar intervertebral disk: myelographic differentiation from herniated disk with nerve root compression. *AJNR* 1982;3:51–58, *AJR* 1982;138:709–716
2. Penning L, Wilmsink JT. Biomechanics of lumbosacral dural sac. *Spine* 1981;6:398–408

3. Pilling JR. Water soluble radiculography in the erect posture. *Clin Radiol* 1979;30:665–670

Reply

We appreciate Dr. Wilmsink's interesting comments and hypotheses and offer the following responses.

His opinion that the S1 nerve root is "tethered in place" by its root sheath is not to our knowledge substantiated by any published anatomic or kinetic studies. It is true that the L5 root usually enters its root sheath at about the level of the L4-L5 disk space, and one could at least as well hypothesize that the L5 root would more likely be "tethered" at the origin of its root sheath, which is anchored to the dural sac. Indeed, many L4-L5 disk herniations impinge on the L5 root at just that location, in the angle between the root sheath and the sac, displacing the root posteriorly and laterally while indenting the sac posteriorly and medially.

Our experience indicates that it is both possible and important to distinguish between the angular sac deformity associated with herniated disk (corresponding in outline to the sides of a tent or a blacksmith's anvil) and the smoothly rounded virtually semicircular margin of the sac deformity in bulging disk (our fig. 3). However, on occasion, and particularly at the L5-S1 level, there is no evident sac deformity associated with a disk herniation (our fig. 6); in such circumstances, one must rely on the demonstration of distal widening of the affected nerve root for the diagnosis, as was the case in figure 6 and in two other patients in our series.

The rounded indentation of the lateral margin of the sac in bulging disk is clearly documented by CT myelography in one of our cases (fig. 2D) as being due to lateral crowding of the nerve roots. Shapiro [1] also discusses this mechanism in his classic textbook on myelography.

The case illustrated by Dr. Wilmsink appears to us to be an example of bulging disk in a patient with mild but definite bony stenosis and thickening of the ligamenta flava. While the external impingement upon the sac is less impressive on the myelographic views obtained in lumbar flexion, these views are by no means normal.

Lumbar disk operations are usually performed with the low back flexed. Posterior protrusion of either a bulging or a herniated disk may indeed be accentuated by lumbar extension and diminished by lumbar flexion. The annulus of a normal disk may also protrude posteriorly in extension, a finding that is probably of no clinical

significance. It is certainly possible that the focal protrusion of a disk herniation might be absent at the time of surgery with the low back flexed. In such circumstances, many surgeons reduce the degree of flexion to more closely simulate the anatomic relationships present at myelography or in the erect position.

In our paper, we clearly indicate that our definition of lumbar disk herniation was based on the surgical verification of nerve root compression by a localized protrusion of disk material. In some instances, the operation demonstrated a "free fragment" of disk material separated from the rest of the disk, while in other cases the focal herniation appeared to be in continuity with the rest of the disk.

We agree that there likely exists a spectrum of degenerative changes in the lumbar intervertebral disks with focal herniation and nerve root compression at the far end of that spectrum. When the annulus is found to be flat at the time of surgery in a patient whose myelogram demonstrated the findings of a bulging disk, the apparent discrepancy may in fact reflect the changes in contour of the annulus between flexion and extension.

Using the criteria we listed in our paper for the myelographic diagnosis of herniated disk, it is gratifying to find a 97% radiologic (extension) to surgical (flexion) concurrence. These criteria alone raise the probability of surgical corroboration of the myelographic findings to a substantial level, despite other factors that preclude 100% concurrence.

Stephen A. Kieffer
Richard G. Sherry
David E. Wellenstein
Robert B. King
*State University of New York
Upstate Medical Center
Syracuse, NY 13210*

REFERENCE

1. Shapiro R. *Myelography*, 3d ed. Chicago, Year Book, 1975:378-385